

TABLE OF CONTENTS*

	<u>Page</u>
INTRODUCTION.....	2
DISCLOSURES	3
FETZER CENTER FLOOR PLANS	4
SCHEDULE.....	5
KEYNOTE SPEAKER.....	6
ORAL PRESENTATIONS	7
POSTER PRESENTATIONS.....	64
ACKNOWLEDGEMENTS	127
INDEX OF AUTHORS FOR ORAL PRESENTATIONS	128

*The complete program including abstracts is available on the Western Michigan University School of Medicine website www.med.wmich.edu.

CME CREDIT:

The evaluation of this activity will be done electronically through the WMED CME website: <http://med.wmich.edu/education/continuing-medical-education>

Click on 'Evaluation Forms' from the left menu. The CME Activity Code is 22196.

After completion of the form, print or save a copy for your files.

INTRODUCTION

RESEARCH, EDUCATION AND SCHOLARSHIP

On this 31st anniversary of Research Day, our institutions commemorate their vision of maintaining the highest quality of research and academics. Under the leadership and sponsorship of Western Michigan University School of Medicine (WMed), we all gather today to evaluate, and take pride in, the extraordinary work being presented by faculty, residents, and students.

The commitment and participation of WMed faculty and the Kalamazoo scientific community continue to provide strong support. This year we had an overall submission of 118 abstracts of which 111 were accepted for inclusion in today's program. We appreciate the dedication and hard work of our academic participants.

Each research project has been carefully reviewed by a group of seven judges who selected the best abstracts for award consideration. Several awards will be given to the best research studies to celebrate the excellence of research, education, and scholarship you will witness at this meeting.

On behalf of WMed, Western Michigan University, and Kalamazoo College, the Kalamazoo Community Medical and Health Sciences Research Committee welcome you. We hope you enjoy this rewarding day.

Luis H. Toledo, MD, PhD
Chair, 2013 Kalamazoo Community Medical and Health Sciences Research Day

Members of the 31st Annual Kalamazoo Community Medical and Health Sciences Research Day Committee:

Leandra Burke
Abby Childs
Laura Eller
Yvonne Ford, PhD (WMU)
Sue Jeska
Wendy Kershner, RN, MSN (WMU)
Diane Kiino, PhD (Kalamazoo College)
Connie Peruchietti (Fetzer Center, WMU)
Elizabeth Phillips
Vinay Reddy, MD

Richard Roach, MD
Sandra Sheppard, RN, MS
Lyndsee Smith (Fetzer Center, WMU)
David Spillers
Ruqiya Tareen, MD
David Todd
Luis Toledo, MD (Chair)
Peter Ziemkowski, MD

DISCLOSURES

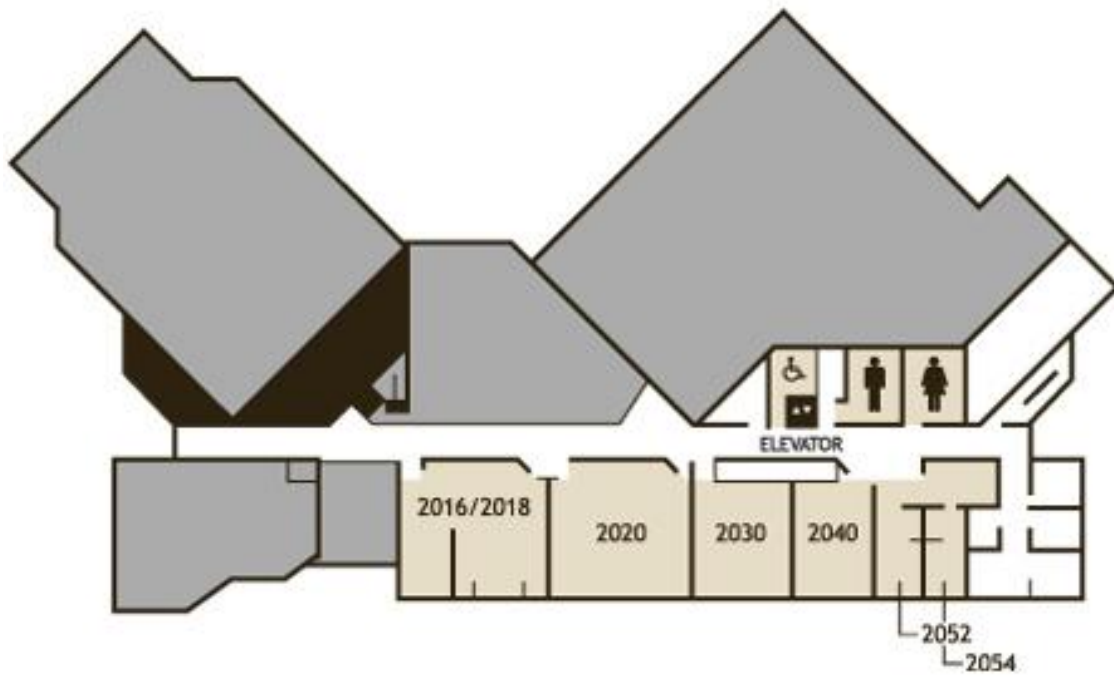
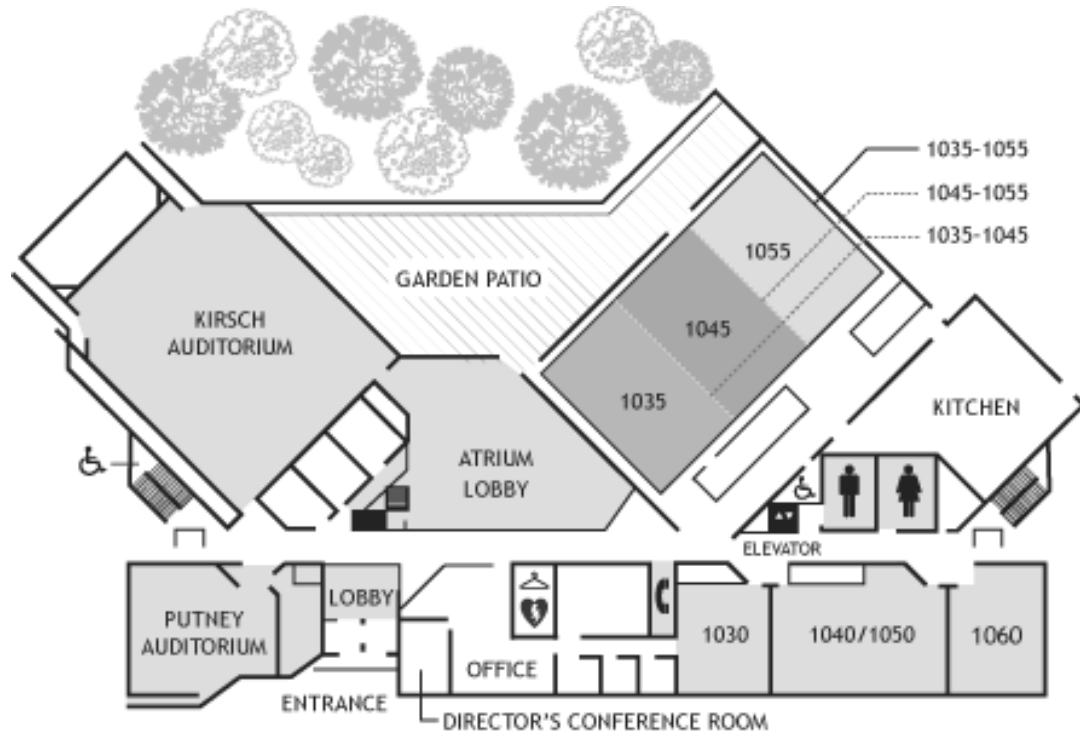
The following oral presenters and group members have no relevant financial relationships to disclose:

Sourabh Aggarwal
Kerri Becktell
Paul Blostein
Megan Brown
Alexander Connaughton
Scott Cressman
Elizabeth Doherty
Christine Dugan
David Dunstone
Laura Furge
Jafar Haghshenas
James Jastifer
Chris Karampahtsis
Andrea Landon
Christina Lang
Michael Liepman
Devin Malik
Brandon Moore
Blake Movitz
Sundeep Singh Randhawa
Vani Sabesan
Usman Saeed
Subhankar Samal
Noah Smith
Robert Strung
Luis Toledo
Anda Tuncay
Richa Varshney
Shrey Velani
David Waterson
Elbert Williams III
Lorenzo Zaffiri

The following oral presenters and group members have financial relationships to disclose:

Catherine Kothari - Evaluation consultant for Healthy Babies-Healthy Start
Leslie Stork – WMU Lee Honors Thesis Research
Daniel Tensmeyer – Synthes
Terri Zachos – North American Veterinary Conference Speakers’ Bureau, consultant for:
Michigan Avenue Animal Hospital, South Main Street Animal Hospital, City College of New York-
Memorial Sloan-Kettering Cancer Center Partnership, AO Foundation Research Review Commission.
Ruth Zielinski – Lee Honors College grant

Fetzer Center Floor Plans



SCHEDULE

8:00 - 8:30 am	Registration Refreshments available in Rooms 1035/1045/1055	
8:30 - 10:05 am	Oral Sessions Session 1A Session 1B Session 1C Session 1D	Putney Lecture Hall Rooms 1040/1050 Rooms 2016/2018 Room 2020
10:05 – 11:00 am	Break Poster Presentations Vendor Exhibits	Rooms 1035/1045/1055
11:00 - 11:55 am	Oral Sessions Session 2A Session 2B Session 2C Session 2D	Putney Lecture Hall Rooms 1040/1050 Rooms 2016/2018 Room 2020
12:00 - 1:15 pm	Lunch / Keynote Speaker <u>2013 Dr. Robert P. Carter Research Lecture</u> The Affordable Care Act: What's Next for Research, Quality, and Training? <i>Marcia Brand, PhD</i> <i>Deputy Administrator,</i> <i>Health Resources & Services Administration</i> <i>U.S. Department of Health and Human Services</i>	Kirsch Auditorium
1:20 - 2:55 pm	Oral Presentations Session 3A Session 3B Session 3C Session 3D	Putney Lecture Hall Room 1040/1050 Room 2016/2018 Room 2020
3:00 - 3:30 pm	Presentation of Awards Hal B. Jenson, MD, MBA <i>Founding Dean</i> <i>Western Michigan University School of Medicine</i>	Kirsch Auditorium

KEYNOTE SPEAKER**The Dr. Robert P. Carter
Research Lecture**

This is the fifth year of this annual lecture supported by the Board of Western Michigan University School of Medicine to celebrate the Research Day activities and recognize Dr. Carter's commitment and support of research at our institution.

“The Affordable Care Act: What's Next for Research, Quality, and Training?”

Marcia Brand, PhD

Deputy Administrator,
Health Resources and Services
Administration

U.S. Department of Health and
Human Services



Marcia Brand, PhD, was named Deputy Administrator of the Health Resources and Services Administration (HRSA) in March, 2009. HRSA is an agency of the U.S. Department of Health and Human Services.

HRSA works to fill in the health care gaps for people who live outside the economic and medical mainstream. The agency uses its \$7 billion annual budget (FY 2009) to expand access to quality health care in partnership with health care providers and health professions training programs.

From 2007-2009, Brand was associate administrator of HRSA's Bureau of Health Professions (BHPr), where she provided national leadership in the development, distribution and retention of a diverse, culturally competent health workforce that provides high-quality care.

From 2001-2007, Brand was director and associate administrator of HRSA's Office of Rural Health Policy. In that position she was responsible for health policy, research and grant activities that promote better health care services in rural America.

Prior to joining ORHP, Brand led efforts to plan and implement the State Planning Grant Program, which helped states explore options in providing health care coverage for uninsured residents. She also coordinated HRSA's efforts to implement the Children's Health Insurance Program (CHIP) and worked on the Secretary's Initiative on Children's Health and the President's Interagency Task Force on Children's Health Insurance Outreach, which aimed to increase enrollment in CHIP and Medicaid.

As senior advisor to the deputy assistant secretary for health in 1997, Brand worked on the Secretary's Initiative on the Future of Academic Health Centers. She served as deputy director of BHPr's Office of Research and Planning for two years prior to that appointment.

Brand earned a doctoral degree in higher education from the University of Pennsylvania, and master and bachelor of science degrees in dental hygiene from Old Dominion University in Virginia.

ORAL PRESENTATIONS**SESSION 1 A - Orthopaedic Surgery****Putney Lecture Hall****Moderator: Dale Rowe, MD – Orthopaedic Surgery**

- 8:30 – 8:45 **Mechanical Stress at the End of Locked and Nonlocked Plating in osteoporotic bone.** Bipin Patel, Peter A. Gustafson, James R. Jastifer, Jason W. Roberts
- 8:50 – 9:05 **Mathematical Model for Preoperative Planning of Ludloff Metatarsal Osteotomies for the Correction of Hallux Valgus.** James R. Jastifer, Vinay Sharma, Adam Hammouda, Peter A. Gustafson
- 9:10 – 9:25 **Economic and Social Impact of Upper Extremity Fragility Fractures in Elderly Patients.** Nathan C. Kolderman, Jovauna M. Currey, Juan N. Rango, Sergey B. Gukasov, Abby Childs, Vani J. Sabesan
- 9:30 – 9:45 **Strength of Locking and Non-locking Plate Constructs Subjected to Oblique Loads in Synthetic Osteoporotic Cancellous Bone with a Cortical Shell.** Daniel F. Tensmeyer, James R. Jastifer, Peter A. Gustafson, Joseph L. Chess, Bipin Patel

SESSION 1 B - Pediatrics**Room 1040/1050****Moderator: Martin Draznin, MD – Pediatrics**

- 8:30 – 8:45 **Perspectives of Patients and Families on Communication with Physicians in the WMUSOM Cystic Fibrosis Center.** Richa Varshney, Douglas Homnick
- 8:50 – 9:05 **Unintentional Injury Education in Pediatrics.** Kerri Beckett, Colette Gushurst
- 9:10 – 9:25 **Blastoschizomyces Capitatus as a Rare Cause of Invasive Fungal Infection in a 20 month-old Girl with ALL.** Christina G.R. Lang, Elizabeth R. Doherty, Katharina Elliott, Thomas Flynn
- 9:30 – 9:45 **Acquired Hemophagocytic Lymphohistiocytosis (HLH) as a Complication of Pediatric Lupus in a 6 yo Boy.** Christina G.R. Lang, Katharina E. Elliott, Mary Moore
- 9:50 – 10:05 **Hypereosinophilic Syndrome Mimicking as Acute Coronary Syndrome in a 17 y/o Patient: A Case Report.** Subhankar Samal, Mary D. Moore

SESSION 1 C - Sports Medicine / Nursing / Maternal Health / Medical Humanities / Other Room 2016/2018**Moderator: Robert Baker, MD – Sports Medicine / Family Medicine**

- 8:30 – 8:45 **Uncommon Knee Injury and its Relationship to Growth Plate Closure.** David C. Waterson, Robert J. Baker
- 8:50 – 9:05 **Prevalence of Pregnancy Folkloric Beliefs Among Nurse-Midwifery Client Populations.** Iris Campbell, Ruth Zielinski, Mary Ann Stark, Mary Lagerwey
- 9:10 – 9:25 **Improving Maternal and Infant Health Through Centering Pregnancy: Results of a Two Year Retrospective Chart Review Using a Matched Comparison Design.** L. Stork, R. Zielinski, M. Deibel C. Kothari
- 9:30 – 9:45 **Hippocrates of Cos. A Historical Example to Future Generations of Physicians.** Luis H. Toledo-Pereyra, James Jastifer
- 9:50 – 10:05 **Old drug, New Problem. A Case of LINES: Levamisole -Induced Necrotic Skin Syndrome.** Devin Malik, Lorenzo Zaffiri, Rasha Abdulmassih, Susan Bannon.

SESSION 1 D - Emergency Medicine / Orthopedic Surgery / Other**Room 2020****Moderator: David Overton, MD – Emergency Medicine**

- 8:30 – 8:45 **The Impact of Helmet Use on Pre-Hospital Neurologic Outcomes in Injured Motorcyclists in Michigan.** Blake Movitz, Caleb Ortega, John Lund, Michelle Lash, Kevin Putman, William Fales
- 8:50 – 9:05 **Fibromuscular Dysplasia Presenting as Bilateral Vertebral and Carotid Artery Dissections with Unilateral Horner's Syndrome in the Postpartum Period.** Noah R. Smith, David V. Smullen, Philip A. Pazderka
- 9:10 – 9:25 **High, but Varied, Utilization from Emergency Department to Hospitalization for Both Victims and Perpetrators of Partner Violence.** Catherine L. Kothari, Rashmi Kothari, Thomas Rohs, Scott Davidson, Carrie Klein, Amy Koestner, Mican DeBoer, Rita Cox, Kim Kutzko
- 9:30 – 9:45 **Behavior of Bone Marrow Derived Mesenchymal Stem Cells in Commercially Available Bone Graft and Scaffolding Products.** Katelynn E. Shaw, Debbie Reynolds, Terri A. Zachos
- 9:50 – 10:05 **Multiligamentous Knee Injuries in the Middle Aged and Elderly Patients.** Paul J. Danielsky, Vani J. Sabesan, Vinay Sharma

SESSION 2 A - General Surgery / Trauma**Putney Lecture Hall****Moderator: Earl Norman, MD – General Surgery**

- 11:00 – 11:15 **Large Bowel Obstruction Secondary to Morgagni Hernia in a Morbidly Obese Adult.** Blake R. Movitz, Saad A. Shebrain, Leandra H. Burke
- 11:20 – 11:35 **Cecal Ganglioneuroma: A Rare Entity Presents as a Therapeutic Dilemma.** Christine M. Dugan, John D. Lund, Lisa A. Miller
- 11:40 – 11:55 **What Do Patients Really Do? Compliance With Discharge Activity Instructions Following Nonoperative Blunt Abdominal Trauma.** Paul Blostein, Scott Davidson, Sheldon Maltz, Jon Walsh, Sheri VandenBerg

SESSION 2 B - General Surgery / Trauma / Cardiac Surgery**Room 1040/1050****Moderator: Saad Shebrain, MD – General Surgery**

- 11:00 – 11:15 **Laparoscopic Adrenalectomy for Giant Adrenal Cyst.** Alexander J. Connaughton, Leandra H. Burke, Saad A. Shebrain
- 11:20 – 11:35 **Caught in Transit. A Rare Case of Definitive Paradoxical Embolism Following Traumatic Injury.** Lorenzo Zaffiri, Elizabeth Steensma, Mark Remmler, Paul A. Blostein, Scott B. Davidson, James Kraatz, Sheldon B. Maltz, Jon C. Walsh
- 11:40 – 11:55 **Manual Thrombectomy in Coronary Artery Bypass Grafting.** Elbert E. Williams, Leandra H. Burke, Jerry W. Pratt

SESSION 2 C - Psychiatry / General Surgery**Room 2016/2018****Moderator: David Dunstone - Psychiatry**

- 11:00 – 11:15 **Post Traumatic Stress Disorder Lost in Transition: A Case Report.** Chris A. Karampahtsis, Robert D. Strung, David C. Dunstone
- 11:20 – 11:35 **The Interrelationship of Partner Violence and Poverty with Postpartum Depression.** Catherine L. Kothari, Michael R. Liepman, Ruqiya S. Tareen, Luz C. Sweezy, Phyllis Florian, Remitha M. Charoth, Suzanne Haas, Joseph W. McKean, Angela Moe, Amy Curtis
- 11:40 – 11:55 **Giant Parastomal Hernia with Massive Bowel Ischemia.** Jafar Haghshenas, Leandra H. Burke, Saad A. Shebrain

SESSION 2 D - Psychiatry**Room 2020****Moderator: Robert Strung, MD – Psychiatry**

- 11:00 – 11:15 **The Sound of Music: Effects on Posttraumatic Stress Disorder.** Sundeep S. Randhawa, Michael R. Liepman, David C. Dunstone, Peter L. Longstreet
- 11:20 – 11:35 **Medical Hypnosis Used to Evaluate and Treat Pain & PTSD Revealed Pre-Term Psychic Trauma.** Michael R. Liepman
- 11:40 – 11:55 **Uncommon Side Effects To Medications In A Patient With Catatonia.** Brandon G. Moore, Mark Kanzawa

SESSION 3 A - Internal Medicine**Putney Lecture Hall****Moderator: Richard Roach – Internal Medicine**

- 1:20 – 1:35 **D.A.M it! A Case of Duodenal Arteriovenous Malformation Causing a Massive GI Bleed.**
Sangeeth R. Dubbireddi, Sourabh Agarwal, Mark Schauer
- 1:40 – 1:55 **Assessing the Compliance of Tattoo Establishments with State Regulations in the Kalamazoo and Surrounding Communities.** Scott J. Cressman, David A. Homa, Anny Ching, Richard R. Roach
- 2:00 – 2:15 **Not Just Another Car Accident: An Uncommon and Refractory Case Presentation of TTP.**
Andrea M. Landon, Shannon L. Stevenson
- 2:20 – 2:35 **May-Thurner syndrome as a Cause of Pulmonary Embolism.** Sourabh Aggarwal, Ravikanth Papani, Sangeeth Dubbireddi, Sarat Vaddineni
- 2:40 – 2:55 **Antineutrophil Cytoplasm Antibody (ANCA) - Negative Granulomatosis with Polyangiitis.**
Christine M. Dugan, Shannon McCormack, Lorenzo Zaffiri, Sourabh Aggarwal, Susan Bannon, Brian Hays

SESSION 3 B - Internal Medicine / Orthopaedic Surgery**Room 1040/1050****Moderator: Thomas Flynn, MD – Internal Medicine / Infectious Disease**

- 1:20 – 1:35 **Sweet Syndrome Associated with a Bitter Hematological Condition.** Arani D. Nanavati, Shrey V. Velani, Ross E. Driscoll
- 1:40 – 1:55 **Linear IgA Bullous Dermatitis Resulting from Vancomycin Therapy!** Shrey V. Velani, Arani D. Nanavati, Melissa Boulden, Pimpawan Boapimp
- 2:00 – 2:15 **Steroid Mist Nourishing an Invasive Mold: A Case Report of Invasive Pulmonary Aspergillosis as a Consequence of High Dose Inhaled Steroid.** Sangeeth R. Dubbireddi, Amy H. Attaway, Thomas E. Flynn
- 2:20 – 2:35 **Secondary Parathyromatosis in a Patient with Normal Kidney Function: Review of Diagnostic Modalities and Approaches to Management.** Anda B. Tuncay Scorza, Andreea G. Moore, Marisa Terry, Lee A. Bricker
- 2:40 – 2:55 **Optimal Augmented Glenoid Implant Size for Moderate to Severe Glenohumeral Osteoarthritis.** Vani Sabesan, Mark Callanan, Vinay Sharma

SESSION 3 C - Internal Medicine**Room 2016/2018****Moderator: Thomas Melgar, MD – Internal Medicine / Pediatrics**

- 1:20 – 1:35 **Bilateral Myelomatous Pleural Effusion: A Case Presentation and Literature Review.** Megan Brown, Usman Saeed
- 1:40 – 1:55 **Dental Visit Exposes Metastatic Renal Cancer: A Case Report of Metastatic Renal Cancer Masquerading as a Tumor Thrombus in the Jugular Veins.** Sangeeth R. Dubbireddi, Rasha Abdulmassih, Sreenivasa Chandana
- 2:00 – 2:15 **Alternative Medicine: Know What Your Patients are Taking!** Sakshi Vaishnav, Sourabh Aggarwal, Valerie Duhn, Ross Driscoll
- 2:20 – 2:35 **Massive Pneumo-Mediastinum Secondary to Pneumocystis Jiroveci Pneumonia in a Non-HIV Patient.** Shrey V. Velani, Imad Bagh, Arani Nanavati, Brian Hays
- 2:40 – 2:55 **Cardioprotective Effect of Xanthine Oxidase Inhibitors in Coronary Artery Disease and Heart Failure** Ryan W. Bradstreet, Megan C. Brown, Erik M. Bobeda, Luis H. Toledo-Pereyra

SESSION 3 D - Family Medicine / Research / Pharmacology / Other**Room 2020****Moderator: Jane Hanneken, MD – Family Medicine**

- 1:20 – 1:35 **Hereditary Stomatocytosis: A Rare Blood Disorder in a Father and his Son.** Shazia Malik, David Homa, Robert Baker
- 1:40 – 1:55 **Racial Disparity in Birth Outcomes: Diversity between Local Communities.** Catherine L. Kothari, Luz C. Sweezy, James Wiley, Amy Curtis
- 2:00 – 2:15 **JAK/STAT Molecular Pathway in Liver Ischemia and Reperfusion.** Andrea Landon, Luis H. Toledo-Pereyra
- 2:20 – 2:35 **Metoclopramide is Metabolized Primarily by Human CYP 2D6 and is a Reversible Inhibitor of CYP2D6.** Mara Livezey, Erran Briggs, Amanda Bolles, Leslie Nagy, and Laura Lowe Furge
- 2:40 – 2:55 **Gender and Choice of Medical Specialty in Medical Students.** Samantha Shaw, Terri A. Zachos, Shiwei Zhou, Sandra V. Sheppard, Luis H. Toledo-Pereyra, Clare Luz, Elizabeth A. Burns

MEDICAL HYPNOSIS USED TO EVALUATE AND TREAT PAIN & PTSD REVEALED PRE-TERM PSYCHIC TRAUMA

Michael R. Liepman

Western Michigan University School of Medicine, Department of Psychiatry, Kalamazoo, MI

INTRODUCTION: Medical hypnosis being used to evaluate pain and PTSD revealed pre-term psychic trauma underlying the PTSD.

CASE REPORT: A 32-year old Caucasian male Vietnam combat veteran presented with post-traumatic stress disorder (PTSD), chronic lumbar back pain, and addiction to opioid agonist pain medications, heroin and cannabis. Past history was positive for mild developmental cognitive disability, but was negative for history of childhood trauma. He sustained injury to his back during an enemy ambush during which he was thrown by an explosion, landing on his back, onto a tank turret. Medical evaluations at presentation revealed no radiological evidence of current or prior fractures, vertebral displacement, or disc narrowing. Straight leg-raising exam was negative, with no tenderness, neurological disruption, guarding, or decreased range of motion. He experienced flashbacks, startle responses, nightmares and psychic numbing; he used heroin and marijuana to avoid feeling. Hypnotic age regression (traveling backwards in memory during trance) allowed him to re-experience the onset of his back pain in order to obtain more detailed history of its onset. Once he reached the injury incident, he provided a running narrative starting just before the ambush, describing the unexpected incoming firing and explosions, and his fate as he flew through the air and landed on the turret; his description was expressed with strong emotion in the form of a controlled flashback that lasted about 5-7 minutes. He observed a layer of dirt and debris covering him as he lay on the turret; initially he was convinced that he had died until he noticed the back pain which convinced him that he was still alive. This association continued until the present. A post-hypnotic suggestion was given that he could pinch himself if he ever wondered whether he was still alive, making it no longer necessary to suffer from the back pain. Upon emerging from trance, he remarked that his back pain was gone, and it did not return subsequently. Before bringing him out of trance, on request to go back further in time to see if there were any other scary events in his life, he revealed another incident in a similar flashback with running narrative. He described being in a dark, warm, safe place until suddenly there was an abrupt jerking movement, followed by screaming, then sirens and people yelling. He reported feeling quite scared, even though the warmth and darkness continued. He was not able to explain what this memory was about. Later, during an interview with his mother, she reported her son having had no known childhood traumatic experiences, but she revealed an auto accident during her eighth month of pregnancy with this patient. She was rushed to the hospital by ambulance and kept for observation. They released her, and a month later she delivered him at term. She wondered if the accident was responsible for him being cognitively impaired, as none of her other children were. She denied ever telling her son about that incident and doubted that he ever could have learned about it from any other source.

DISCUSSION: Medical hypnosis may be used to assist in the management of pain. In cases where pain is caused by diagnosed medical conditions, hypnosis may facilitate decreasing attention to the pain, diminishing suffering, or reducing the intensity of the pain. In cases where the origin of the pain is psychosomatic, the pain may be eliminated entirely. Post-traumatic Stress Disorder following adult traumatic incidents usually occurs in persons who sustained prior childhood trauma. This case highlights the occurrence of a pre-term traumatic experience setting the stage for later PTSD. Hypnotic age regression provides a means to access repressed memories that might otherwise be inaccessible to the patient and therapist. Maternal adrenalin and cortisol release would have crossed the placenta and affected the fetus causing him to become frightened and to recall the event.

CONCLUSION: Unconscious memories may include recall of pre-term experiences that might otherwise be inaccessible to the patient and therapist. These memories may have a lasting detrimental effect on the person. Medical hypnosis may assist in unraveling the mystery and treating the symptoms.

ACQUIRED HEMOPHAGOCYtic LYMPHOHISTIOCYTOSIS (HLH) AS A COMPLICATION OF PEDIATRIC LUPUS IN A 6 YO BOY

Christina G.R. Lang, Katharina E. Elliott, Mary Moore
Western Michigan University School of Medicine, Kalamazoo, MI

INTRODUCTION: Hemophagocytic lymphohistiocytosis (HLH) is an incompletely understood condition resulting in uncontrolled and ineffective immune activation. HLH is classified as genetic HLH (primary) or acquired (secondary) and presents with a fulminant picture of non-remitting high fever, pancytopenia, hepatosplenomegaly, lymphadenopathy, liver dysfunction, coagulopathy, and neurological symptoms. Acquired causes of HLH include infection associated hemophagocytic syndrome (IAHS), macrophage activating syndrome(MAS), and malignancy-associated HLH.

CASE REPORT: BS, a 6 yo Caucasian male at the time of presentation, was admitted to a pediatric hematology service with a 3 week history of fever of unknown origin, fatigue and joint pain. His past medical history was significant for ITP at age 3 that was treated with IVIG x 2 resulting in complete resolution. Prior to admission, BS had developed a 'lacy' appearing facial rash approximately 1 month prior. He had been evaluated by his primary pediatrician and diagnosed with Erythema infectiosum. The rash subsequently resolved without medical intervention and he remained afebrile for approximately 5 days. One week later, the fever (105.8 Fahrenheit) and rash recurred. The rash had become more extensive, involving his trunk, arms, and legs and was described as pruritic and the patient was referred to outpatient hematology. Outpatient evaluation was significant for positive CMV IgM and past EBV infection and an outpatient bone marrow was scheduled to rule out malignancy; however the patient was hospitalized prior to this for clinical deterioration. Physical, laboratory and interim historical findings included diffuse lymphadenopathy, photophobia, general fatigue, anorexia and migratory joint pain preventing ambulation. Fever spikes were described as multiple and daily. CBC on admission demonstrated lymphocytopenia and pancytopenia without evidence of blasts. Urinalysis demonstrated evidence of nephritis and nephrotic range proteinuria. A bone marrow biopsy was performed and ruled out malignancy. A battery of laboratory studies were performed (chart to be included). The patient met diagnostic criteria for HLH. The diagnosis and HLH-2004 protocol were reviewed with the family and chemotherapy initiated. At initiation of therapy the patient could be succinctly described as a 6 yo male with prolonged fever, generalized lymphadenopathy, arthralgias, oral ulceration, patchy airspace disease, hypoalbuminemia, hypergammaglobulinemia, hypocomplementemia, low grade DIC, confirmed bilateral retinitis and nephritis consistent with HLH. The underlying autoimmune dysfunction was thought to be secondary to XLP 2 as X-linked lymphoproliferative (XLP 1) and autoimmune lymphoproliferative syndrome(ALPS) were subsequently ruled out. The patient initially responded very well to therapy but had refractory illness approximately 3 months after initiation of therapy, including profound worsening proteinuria with steroid cessation. BS was sent to a larger center for nephrology consult and renal biopsy. The renal biopsy was diagnostic for focal lupus nephritis (class 3) and the patient was started on mycophenolate.

DISCUSSION: HLH and SLE are both challenging diagnosis in the pediatric population and can have significant morbidity and mortality. Ultimately, our patient had “reactive” HLH secondary to underlying SLE, an extremely rare diagnosis in pre-school aged caucasian males.

CONCLUSION: Systemic lupus erythematosus (SLE), an autoimmune disease characterized by multiple-organ involvement, female dominance, and rapid progression affects patients from infancy to old age. The reported yearly incidence of SLE in children ranges between 0.36 and 0.9 per 100,000, compared to 3.0 per 100,000 in adults [Zhu, 2013]. The incidence of SLE in a Caucasian male under age 10 is extremely rare, with one study documenting lupus nephritis in Caucasian boys with an estimated prevalence of 0.20% and an annual incidence of 0.03%. SLE has often been referred to as the “great mimicker” as it shares many characteristics with other autoimmune processes as is evident in this case. SLE in the pediatric population is a challenging diagnosis. In the pediatric population presenting symptoms include fever, skin involvement, arthritis, and seizures with hematologic involvement presenting most commonly (zhu et al 2013); making hematologic disorders as the presenting etiology difficult to distinguish.

WHAT DO PATIENTS REALLY DO? COMPLIANCE WITH DISCHARGE ACTIVITY INSTRUCTIONS FOLLOWING NONOPERATIVE BLUNT ABDOMINAL TRAUMA

Paul Blostein, Scott Davidson, Sheldon Maltz, Jon Walsh, Sheri Vandenberg
Bronson Methodist Hospital, Trauma Burn and Surgical Critical Care Program, Kalamazoo, MI

INTRODUCTION: Management of solid visceral injuries from blunt abdominal trauma has evolved over the last two decades. The majority of blunt injuries of the liver, spleen, and kidney are now successfully managed non-operatively. Activity restrictions during the period of organ healing after hospital discharge are not standardized. The extent of activity reduction, length of reduced activity, and parameters determining when normal activities may be resumed are variably prescribed by surgeons. However, it is not known whether patients comply with the activity restrictions they are given at discharge. We followed patients with blunt injuries of the liver, spleen, and/or kidney for two months after discharge to determine their actual levels of activity and compliance with restrictions.

MATERIAL & METHODS: All patients age six and over who were admitted to our Level I trauma center after sustaining a blunt injury of the liver, spleen, and/or kidney that did not require surgical intervention were eligible for study inclusion if accessible by telephone after discharge, English speaking, and able to understand written activity restrictions. After informed consent/assent, study subjects (and their parents) were given written activity restrictions on the day of discharge. Questions were answered, and a best telephone number and time were established for contact at one, two, four, and eight weeks after discharge. Restrictions were adjusted at outpatient follow-up physician visits as appropriate, and new written activity restrictions issued. Using a standardized format, the trauma research nurse conducted a telephone interview with each subject (or the parent of a minor subject), at one, two, four, and eight weeks post-discharge. The interview consisted of open ended questions in relation to each restriction, e.g., “How much weight are you lifting? Have you returned to work? Are you driving?” and were identical at each interview. The subject was also queried about difficulty or pain with each activity, and each response was recorded without comment or judgment. All responses were confidential and noted only in the database. Trauma surgeons were blinded to the results. If subjects were not contacted by telephone on the scheduled day of their interview, they were asked to comment on their activity level for that specific day when reached. Subjects unable to be contacted on three attempts on different days were considered lost to follow up.

RESULTS: Fifty subjects participated in the study; 36 males (72%), aged 27.6 ± 18.0 , 7-78 years (mean \pm SD, range). Length of stay (LOS) was 3.5 ± 2.3 , 1-13 days, and injury severity score 16.1 ± 10.4 , 4-57. Eight patients sustained a liver laceration, 38 had splenic laceration, and 15 had renal laceration or contusion. Six patients sustained both splenic and renal injury while 3 patients had concurrent renal and liver injuries. Twenty nine (58%) of the subjects had another concomitant injury. 52% of injuries were motor vehicle related, 24% sports related, 14% from falls and the remaining 10% from other causes. Fifty six percent of patients completed all four follow-up interviews; 26% completed three; 4% completed two; 14% of patients completed one interview. Two patients withdrew from the study when insurance dictated that medical follow-up be closer to home. One additional patient was dropped on the 12th post-injury day when he required an emergent splenectomy. 161 phone interviews were conducted with 49 patients. Activity violations were not statistically significant between each interval. There were 26 violations of any type at one, 25 at two, 30 at four, and 19 at eight weeks respectively. Neither gender, age, or LOS was predictive of overall activity violations. Female patients were more likely to climb stairs, participate in noncontact sports, and drive despite restrictions. Male patients were more likely to violate sexual activity restrictions (OR 0.675, 95% CI 0.069-6.648).

CONCLUSION: The majority of patients actually follow trauma surgeons' advice regarding activity restrictions after liver, spleen, and/or kidney injuries. Some activity violations are gender biased and instructions could be emphasized accordingly. There were no apparent sequelae directly related to activity violations, but whether this means restrictions can be liberalized or shortened requires further study.

MECHANICAL STRESS AT THE END OF LOCKED AND NONLOCKED PLATING IN OSTEOPOROTIC BONE

Bipin Patel, Peter A. Gustafson, James R. Jastifer, Jason W. Roberts
Western Michigan University School of Medicine, Kalamazoo, MI

INTRODUCTION: After a fracture, bones are often fixed with plate and screw constructs. Periprosthetic fracture at the end of the construct is a well-recognized complication and is thought to be related to the contact behavior between the bone ends, the plate, and the screws. Locking screw constructs have been shown to have a greater periprosthetic fracture risk than conventional constructs.

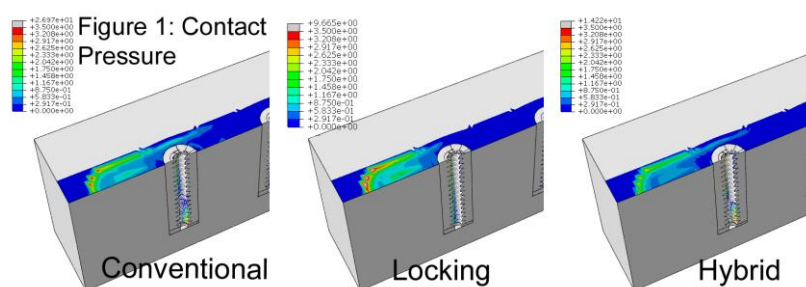
RATIONALE: The purpose of the current study is to establish the biomechanical rationale for the increased risk of periprosthetic fracture associated with locking screw constructs over conventional screw constructs. This is important because the promise of locking plates to increase fixation in osteoporotic bone must be balanced with the potential complication of a periprosthetic fracture. An understanding of the biomechanical rationale for fracture may result in a potential solution to improve fixation in osteoporotic bone while minimizing complications. Our hypothesis was that the application of a conventional screw at the end of a locking screw construct (hybrid plating) leads to a decrease in contact stress at the interface between the plate and the bone.

MATERIAL & METHODS: A finite element study was performed to investigate a conventional screw construct, locking screw construct, and hybrid plating construct under normal, oblique, and shear loads. The models consisted of a bone block and a plate with two screws. A static load of 100N was applied at the plate end. Finite element analyses were performed on the three models using Abaqus 6.11 with the following combinations: (1) two conventional screws (2) two locking screws and (3) one conventional and one locking screw with the conventional screw located at the end of the plate. Each construct was evaluated with cancellous bone densities 0.08 g/cm³ and 0.16g/cm³ to simulate osteoporotic bone. Contact surfaces at the plate-bone interface and screw-bone interface were evaluated.

RESULTS: Locking screw constructs experienced 62% higher plate-bone contact pressure than conventional screw constructs (Figure 1). Substitution of a conventional screw instead of a locking screw at the end of a locked construct reduces the contact pressure by 72%. It was also observed that the greater the bone density, the greater the effect that the construct type has. In other words, there was less of a difference between locking and conventional constructs in low density osteoporotic bone compared to higher density osteoporotic bone. Also, locked plates were found to be more sensitive to bone density than conventional plates. These observations were due to higher contact pressure and contact shear at the screw-bone interface. Finally, compared to conventional screw constructs, the locked screw construct was found to be weaker in pullout loads and stronger in shear loads.

DISCUSSION: These results support the observation from experimental studies that locking plate constructs are susceptible to fracture at the end of the plate. The current study also provides insight on screw-bone contact mechanics with locking and conventional plating demonstrating that the stresses in severely osteoporotic bone are not as dependent on construct type as in higher bone densities.

CONCLUSION: The clinical significance of this study is that it supports the placement of a conventional screw in the last hole of a locking screw construct to help prevent periprosthetic fracture.



MATHEMATICAL MODEL FOR PREOPERATIVE PLANNING OF LUDLOFF METATARSAL OSTEOTOMIES FOR THE CORRECTION OF HALLUX VALGUS

James R. Jastifer, Vinay Sharma, Adam Hammouda, Peter A. Gustafson
Western Michigan University School of Medicine, Kalamazoo, MI

INTRODUCTION: Hallux valgus is a complex pathological condition of the first ray of the foot that sometimes requires corrective surgery. Computer based models and tools are increasingly being utilized in preoperative surgical planning, a critical step for surgeons to optimize postoperative results.

RATIONALE: To our knowledge, no study has investigated the use of a mathematical model as an independent tool for preoperative planning of hallux valgus correction. An extension of our previous work on the qualitative geometric effects of the Ludloff osteotomy, the current study aimed at presenting a novel mathematical model and relevant computationally derived tools for the quantitative geometric effects of hallux valgus correction with a Ludloff osteotomy. Our hypothesis was that an accurate computational model could be developed, inclusive of the most important geometric parameters of hallux valgus and the Ludloff osteotomy, which could assist the surgeon in preoperative planning.

MATERIAL & METHODS: Utilizing a previously developed three-dimensional computational and mathematical model of hallux valgus, a computational tool was created using the software package GNU Octave 3.6.2. This model and subsequent tool utilized three types of input data. First, mean anatomical data obtained from current literature. Second, patient specific data based on preoperative x-rays including the severity of the hallux valgus deformity. Third, surgeon specific data including the osteotomy angle (angle of Ludloff osteotomy relative to the axis of the first metatarsal), the angle of rotation (the amount of rotation required to correct the deformity), and any metatarsal translation that may be desired. This tool was then used to create reference tables for quantitative preoperative planning.

RESULTS: Quantitative geometric effects of an osteotomy can be predicted from patient specific hallux valgus data including the actual (preoperative) and desired (postoperative) 1-2 intermetatarsal, planned osteotomy parameters including the osteotomy angle and angle of rotation, and mean geometric data. For example, if a patient had a severe hallux valgus deformity with a 20 degree 1-2 intermetatarsal angle that the surgeon wished to correct to the angle to 9 degrees with a 60 degree Ludloff osteotomy, a rotation of 19 degrees would be required which would also yield an elevation of the first ray of 2.4 mm and pronation of the first ray of 9 degrees.

DISCUSSION: The current model is the first comprehensive computational model and tool that predicts the quantitative geometric effects of a Ludloff osteotomy for hallux valgus correction. As technology drives innovation, this model and tool can help surgeons plan more accurate surgery by integrating important patient and surgeon related data to predict the geometric outcome of a Ludloff osteotomy.

CONCLUSION: The clinical significance of this study is that we have developed a tool to assist the surgeon in the preoperative planning of hallux valgus correction with a Ludloff osteotomy. This tool uses a computer based approach to quickly analyze all of the important variables and provide the surgeon with the necessary data to plan a successful hallux valgus correction.

CAUGHT IN TRANSIT. A RARE CASE OF DEFINITIVE PARADOXICAL EMBOLISM FOLLOWING TRAUMATIC INJURY.

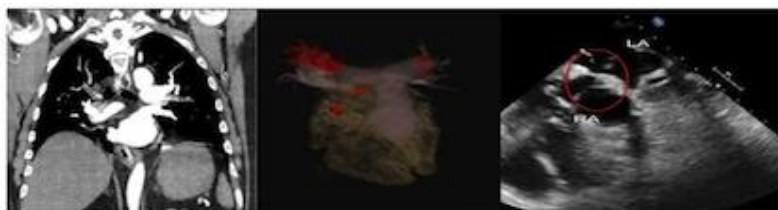
Lorenzo Zaffiri, Elizabeth Steensma, Mark Remmler, Paul A. Blostein, Scott B. Davidson, James Kraatz, Sheldon B. Maltz, Jon C. Walsh
Western Michigan University School of Medicine, Kalamazoo, MI

INTRODUCTION: Paradoxical embolism is a rare and catastrophic clinical phenomenon. Diagnosis is based on the presence of 4 key elements: venous thrombus, communication between right and left heart, thrombus traversing a patent foramen ovale (PFO) and arterial embolism. In most cases, this is a presumptive diagnosis due to lack of simultaneous evidences of all these findings. We describe a rare case of definitive paradoxical embolism following a traumatic injury. Interestingly, we were able to identify all the key elements for a definitive diagnosis through imaging studies.

CASE REPORT: A 54-year-old male was hospitalized following a fall from a ladder. He immediately developed hip pain and inability to bear weight on right side. Past medical history was significant for obstructive sleep apnea, obesity and hypertension. His initial physical examination and laboratory findings were all normal. Pelvic Computed Tomography (CT) scan without contrast demonstrated acute fractures of right acetabulum and proximal femur associated with prominent intramuscular and soft tissue edema. Twelve hours post-admission, the patient was brought to operating room for intramedullary nailing of right femur. He suddenly became hypotensive, hypoxic and tachycardic. CT chest with contrast showed extensive bilateral pulmonary embolism with evidence for right heart strain. Interestingly, heart three-dimensional reconstruction demonstrated a tubular low-density filling defect within the left atrium measuring 8 mm and 3.5 cm long which appeared to represent an extension of a right atrial embolism. Trans-esophageal echocardiography (TEE) confirmed the presence of a thrombus in transit within a PFO. The patient underwent emergent removal of atrial blood clots, foramen ovale closure and pulmonary arteries embolectomy. An inferior vena cava filter was placed and intravenous heparin infusion was started. Subsequent CT abdomen and pelvis demonstrated the presence of arterial emboli to the left kidney and a thrombus in right profunda femoral vein. Hypercoagulability work-up revealed lupus anticoagulant antibodies. Patient remained on mechanical ventilation and vasopressors support for few days and was subsequently discharged from the hospital on day 25.

DISCUSSION: In the general population the prevalence of PFO is up to 26%. However, paradoxical embolism occurs in less than 2% of all arterial embolism cases. More interestingly, only 55% of the cases meet the criteria of definitive paradoxical embolism. In our case, radiological findings identify the presence of all the key elements for a definitive diagnosis. Generally a PFO does not induce symptoms or complications. However, a rapid increase of right side pressures of the heart, as in case of massive PE, could allow the passage of venous embolism into the arterial circulation through a PFO. Our patient was affected by OSA which is considered a tremendous risk factor for the development of PFO and a prothrombotic state induced by the lupus anticoagulant antibodies. The presence of these predisposing factors associated with the development of a DVT following a traumatic injury induced the subsequent progression of serious events including massive PE and paradoxical embolism. Echocardiography is the test of choice to identify the presence of PFO and a right-to-left shunt. Although there is a lack of trials to define the best treatment options, surgical embolectomy with closure of PFO is considered the treatment of choice in severe cases.

CONCLUSION: In conclusion, we describe a rare case of confirmed paradoxical embolism, in which imaging studies allowed the identification of a venous thrombosis, a traversing thrombus and pulmonary and systemic embolism.



UNCOMMON KNEE INJURY AND ITS RELATIONSHIP TO GROWTH PLATE CLOSURE

David C. Waterson, Robert J. Baker
Western Michigan University School of Medicine, Kalamazoo, MI

INTRODUCTION: This case report describes an uncommon knee injury that affects adolescent athletes. The injury is unique because of timing of closure of the distal femoral growth plate.

CASE REPORT: A 17 year-old high school football offensive lineman sustained a right knee injury while blocking down field. Late in the game, he describes a hyperextension injury to the right knee. He was unable to continue playing or even bear weight and noted that the knee swelled immediately. Examination, the following morning revealed a large right knee effusion with slight flexion contracture and minimal active flexion secondary to pain. Valgus stress showed gapping of the medial joint line when testing near zero degrees. Lachman's test was limited due to effusion, guarding, and medial joint line tenderness. Knee X-rays demonstrated an effusion and fracture of the medial femoral condyle. On CT scan a horizontally oriented fracture through the medial aspect of the distal femoral physis extending in a sagittally oriented fashion into both the intracondylar notch and the patellofemoral joint was seen. Complete arthroscopy of the knee showed ligament structures intact. An open reduction internal fixation was performed.

DISCUSSION: Distal femoral growth plate fractures represent a unique presentation of a common injury mechanism. The differential diagnosis would more commonly include ligament sprains. The closure of the distal femoral physis starts centrally, at about age 15 to 16. While the injury mechanism mimics MCL sprain, because of the unique physiology of the closure of the medial femoral physis, fracture should be considered in this age group. Further, this fracture is often characterized by a unique pattern.

CONCLUSION: This case demonstrates the unique presentation of distal femoral growth plate fracture in an adolescent. A high index of suspicion is important as these fractures may be minimally displaced and therefore, difficult to characterize with plain film radiography.

D.A.M IT! A CASE OF DUODENAL ARTERIOVENOUS MALFORMATION CAUSING A MASSIVE GI BLEED

Sangeeth R. Dubbireddi, Sourabh Agarwal, Mark Schauer

Western Michigan University School of Medicine, Internal Medicine, Kalamazoo, Michigan

INTRODUCTION: Arteriovenous malformations (AVM) of the small intestine are abnormally dilated submucosal veins and increasingly recognized as a cause of Gastrointestinal (GI) bleeding. They are classically known to cause slow chronic blood loss and are reliably diagnosed on angiography. Here we describe a rare case of a duodenal AVM that led to a massive GI bleed requiring an exploratory laparotomy for definitive diagnosis and treatment

CASE REPORT: A 74 year old gentleman presented with dizziness and black tarry stools that started 2 days prior. He suffered from Rheumatoid Arthritis requiring monthly Infliximab infusions, intermittent NSAIDs and daily prednisone of 4 mg. He also had Diabetes Mellitus. He was pale, diaphoretic, tachycardic and hypotensive (MAP 60's); hemoglobin was 7.3 gm/dl. Initially, it appeared to be secondary to a bleeding peptic ulcer related to NSAID usage. However, Esophagogastroduodenoscopy revealed an area of persistent bleeding in the distal duodenum; two clips were placed and epinephrine was locally injected but this failed to stop the bleeding. Poor visualization prompted selective visceral angiography which was equivocal. A tagged RBC scan confirmed progressive accumulation and extravasation of radiotracer suggestive of a small bowel hemorrhage. The patient's hemoglobin continued to drop despite transfusions and an exploratory laparotomy was indicated. Duodenotomy revealed a polypoid mass with irregular surface calcifications, oozing blood in the distal duodenum, which was resected. He was transfused a total of 11 units packed RBCs, 4 units of Fresh Frozen Plasma, 1 Cryoprecipitate and 6 packs of platelets during his hospital stay. Surgical pathology specimen confirmed this to be an AVM with submucosal dilation of veins. Hemoglobin at the time of discharge was 8.3 gm/dl and at 3 week follow up his wound was healing well and Hemoglobin was 11.

DISCUSSION: Moore et al categorized AVMs into 3 types. Type 1 is solitary, located in the colon presenting around age 55. Type 2 is large, congenital and in the small bowel. Type 3 is described as punctate angiomas associated hereditary hemorrhagic telangiectasias. Our case has mixed features of Type 1 and 2 by presenting in a 74 year old in the duodenum suggesting a need for reclassifying AVMs. Only 2 cases of Duodenal Arteriovenous Malformation causing massive GI bleed have been reported in the literature exposing the rarity of this clinical entity.

CONCLUSION: While the most common causes of a massive GI bleed are still peptic ulcer disease and esophageal varices, AVMs must also be considered in the differential. Further study is required to better characterize and understand the pathophysiology of intestinal AVMs.

DENTAL VISIT EXPOSES METASTATIC RENAL CANCER: A CASE REPORT OF METASTATIC RENAL CANCER MASQUERADING AS A TUMOR THROMBUS IN THE JUGULAR VEINS

Sangeeth R. Dubbireddi MD, Rasha Abdulmassih MD, Sreenivasa Chandana MD PhD
Western Michigan University School of Medicine, Internal Medicine, Kalamazoo, Michigan

INTRODUCTION: Renal cell carcinoma (RCC) is well-known for its metastatic potential. RCC has been recognized to metastasize to nearly every organ system. Most common metastatic sites are lung, bone, liver, brain and contralateral kidney in descending order and uncommonly the head and neck region. Here, we present a rare case of RCC, caught in its act of hematogenous metastasis to the jugular venous system, presenting as a parotid mass.

CASE REPORT: A 84 year old Caucasian male went to the dentist for a routine visit, where exam revealed fullness of the right parotid region without any symptoms. His past medical history is significant for early stage prostate cancer, diagnosed 3 years ago, stage II RCC diagnosed 13 years ago. Patient underwent prostatectomy for his prostate cancer and left nephrectomy for his RCC. Social and family histories are unremarkable. An otolaryngology referral prompted computerized tomography (CT) of the neck, which revealed asymmetric contrast enhancement of the left carotid artery in the masticator space with filling defects in the left retromandibular and left internal jugular vein. Fine needle aspiration and cytology was positive for renal cell carcinoma with clear cell histology. Further work up including CT of chest, abdomen and pelvis was negative for any other metastases. Only subtotal excision was achieved due to the extensive invasion of the tumor into every tributary draining into the external jugular vein and the parotid gland. Magnetic resonance imaging of brain did not reveal any intra cranial involvement. Patient underwent involved field radiation therapy, followed by targeted therapy with tyrosine kinase inhibitor, Pazopanib. On frequent follow up, he continues to be asymptomatic, tolerating therapy well.

DISCUSSION: Renal cell carcinoma metastasis to the parotid gland after nephrectomy is extremely rare. To the best of our knowledge, about 25 cases of RCC were reported to have metastasis to parotid gland, but never with involvement of jugular venous system. In our case, RCC metastasis to parotid gland with contiguous spread through draining jugular veins is unique. This is akin to spread of primary RCC to inferior vena cava and right atrium through renal veins. Biological behavior of RCC with contiguous venous spread, again suggest its metastatic potential. Molecular pathways involving the vascular endothelial growth Factor (VEGF), molecular target of rapamycin (mTOR) might have a role in this process.

CONCLUSION: Ongoing clinical studies with tyrosine kinase and mTOR inhibitors in adjuvant setting might give us more biological insights.

PERSPECTIVES OF PATIENTS AND FAMILIES ON COMMUNICATION WITH PHYSICIANS IN THE WMUSOM CYSTIC FIBROSIS CENTER

Richa Varshney, Douglas Homnick
Western Michigan University School of Medicine, Kalamazoo, Michigan

BACKGROUND: Cystic fibrosis (CF) is a chronic disease and its management requires constant and cooperative care by the family, patient and the physician. As a result, communication is a key component of CF care. It has been demonstrated that patient centered communication improves diagnostic and therapeutic efficiency, physicians' and patients' satisfaction and treatment outcomes. CF patients and families may have issues surrounding communications with their providers of which providers may be unaware, including those associated with the time constraints and stresses of a busy CF clinic

OBJECTIVE: To investigate the questions and concerns of CF patients/families surrounding communication with physician providers in the WMUSOM CF clinic through a 5-7 minute written survey.

METHOD: An 11 item questionnaire was distributed by the CF clinic staff to participants upon entry into the clinic. A master check list was maintained to ensure no duplication of surveys and that no patients and families were missed. The master list was coded so that the investigators did not know the identity of the respondents. Data collection was done between 9/1/2012 through 01/31/2013 until most patients and families had completed or refused to complete the survey. Results were expressed in percentages of responses to individual questions based on the denominator of responses.

RESULT: The survey was completed by 32 out of 37(86%) CF patients and /families. Forty percent were males and 60% females up to 21 years of age. Forty-seven percent of patients had been diagnosed with CF for more than five years and perceived their overall health as very good. Out of 32 who completed the survey, 91% stated that they had no difficulty asking the doctor questions. Out of 9% who had difficulty asking question, 67% stated that they forgot questions to be asked before the clinic visit and 33% felt uncomfortable in expressing concerns in face- to- face interview with physician. Fifty percent of patients had no difficulty contacting the clinical team concerning questions prior to or after their visit. Fifty-three percent thought that the clinical team provided excellent information about CF care at home.

CONCLUSION: This health care communication questionnaire gives information about indicators of quality of care from the patient's and family's perspective. From this intervention tools may be developed to test in subsequent PDSA cycles. Suggested test material may include keeping a diary to prevent forgetting of questions during a busy clinic and the ability to e-mail /text/phone physician providers with care questions. This can be used for quality improvement initiatives.

THE INTERRELATIONSHIP OF PARTNER VIOLENCE & POVERTY WITH POSTPARTUM DEPRESSION

Catherine L. Kothari, Michael R. Liepman, Ruqiya S. Tareen, Luz C. Sweezy, Phyllys Florian, Remitha M. Charoth, Suzanne Haas, Joseph W. McKean, Angela Moe, Amy Curtis
Western Michigan University School of Medicine, Kalamazoo, MI

INTRODUCTION: Millions of women experience partner violence, poverty and depression every year in the United States; each exacting physical, social and mental health burdens that can become lifelong. Evidence documenting the co-occurrence of partner violence and depression, and the co-occurrence of poverty and depression continues to mount, but studies of how the three intersect remain sparse. The perinatal period, pregnancy and postpartum, is particularly vulnerable to the onset and the effects of psychosocial difficulties, and thus offers a critical window within which to examine this interrelationship.

RATIONALE: The current study examines the intersection of poverty, partner violence and depression among a socio-economically diverse sample of postpartum women. Specifically, this study examined poverty and IPV as (1) independent predictors of depression, after controlling for each other, (2) as moderating each other's relationship with depression, and (3) as mediators of each other upon depression.

MATERIAL & METHODS: The study is a secondary analysis of data that was originally collected for a prospective survey of 301 postpartum women, recruited from the two county delivery hospitals, January through May, 2009. Data was collected through phone interviews at two months postpartum, in addition to medical record abstraction. IPV was assessed using three questions for current or past emotional or physical abuse. Insurance status (Medicaid or private insurance) served as a proxy measure for poverty. Depression was measured using the Edinburgh Postnatal Depression Scale (EPDS). The following study covariates were included: Maternal demographics (age, race, marital status), perinatal characteristics (adequacy of care, whether the pregnancy was planned), psycho-social characteristics (substance abuse history, work history, housing problems, and life stressors), and birth outcomes (low birthweight, prematurity). Multivariate analyses were conducted using linear regression, after confirming test assumptions were met. Covariates that were found to be independently associated with EPDS without functioning as a mediator in the relationship between IPV and depression or between poverty and depression were included in the final model. All statistical operations were two-tailed and conducted at the $p < .05$ significance level.

RESULTS: The study sample was similar to the 2009 Kalamazoo County maternal population regarding several demographic and health-related characteristics: Maternal age, race, marital status, paragravida, gravida, prenatal care, prenatal BMI and infant birthweight. However, the study sample was significantly more likely to have private insurance and a High School diploma, and had significantly lower infant prematurity. EPDS scores ranged from zero to twenty-eight, with a mean of 5.1 (standard deviation 4.6), and a median of 4.0. One in five study participants (21.3%, $n = 64$) screened positive for emotional or physical abuse, and one in three participants (32.2%, $n = 97$) met study poverty criteria. Finally, separate from their relationship with depression, IPV and poverty were statistically significantly associated with each other. Thirty-three percent of women living in poverty reported experiencing IPV as opposed to 15.7% among women not living in poverty ($p < .001$). IPV and poverty were each significant predictors of depression in simple regression analyses (unadjusted EDPS rates: 3.2 beta, 2.0-4.5 CI, $p < .001$ for IPV and 1.3 beta, 0.2-2.4 CI, $p = .017$ for poverty). Furthermore, the significance you would expect to see if there were an IPV-poverty interaction, with each of the four groups significantly different from the referent group, is absent. In the adjusted regression model, IPV has a significant relationship with depression when poverty is controlled for, but poverty's relationship with depression disappears when IPV is controlled for. Experiencing IPV is associated with an increase in 3.1 points on the 30-point EPDS scale ($p < .001$), while poverty is associated with an increase of 0.8 EDPS points ($p < .141$).

DISCUSSION: In a socioeconomically diverse sample of perinatal women, study findings demonstrate that IPV had a strong direct relationship with postpartum depression; a relationship that did not change with poverty status. Among the multiple pathways into depression (genetic, hormonal, environmental), this study examined predictors that are thought to lead to depression through their net effect upon environment through increased stress, low social support, and negative cognitions. In contrast, poverty, rather than directly related to depression, is indirectly related to depression through its impact upon IPV.

CONCLUSION: In sum, study findings suggest a ripple effect of IPV; a ripple that includes depression and poverty.

RACIAL DISPARITY IN BIRTH OUTCOMES: DIVERSITY BETWEEN LOCAL COMMUNITIES

Catherine L. Kothari, Luz C. Sweezy, James Wiley, Amy Curtis
Western Michigan University School of Medicine, Kalamazoo, Michigan

INTRODUCTION: Racial disparity in birth outcomes remains a significant issue across the United States; Kalamazoo County, Michigan, the setting for this study, has a history of high black infant mortality rate (18.7 IMR per 1,000 live births among black women, 2006-2010 period) and high racial disparity (black to white IMR disparity ratio of 3.5, 2006-2010 period). Despite evidence regarding the influence of community-level economic and social infrastructure, and the impact of multi-level interventions upon race-related health disparity, programming at the local, state and federal levels rarely takes community differences into account.

RATIONALE: The study goal was to examine the variation across communities within a single county regarding racial disparity in birth-outcomes, and to identify the community-level features associated with the variation.

MATERIAL & METHODS: This was a cross-sectional study linking two secondary datasets from Kalamazoo County, Michigan using geographic information systems (GIS): 1) 2008 birth certificate record data, generated by Michigan State vital records department (N=2,873), and 2) Y2000 census tract data extracted from the Rand Center for Population Health and Health Disparities Core Data Series, housed within the Interuniversity-Consortium-for-Political-and-Social-Research data warehouse (N=60). Within each tract, disparity was measured by subtracting the percent of White mothers with a poor birth outcome (premature or low birthweight infant) from the percent of Black mothers with a poor birth outcome. Outcomes were operationalized with two methods: As interval-level differences, and as a categorical-level variable (White birth outcomes worse, White and Black birth outcomes similar, Black birth outcomes worse, Black birth outcomes much worse). Covariates included demographic, socio-economic, environmental (pollution and street connectivity), maternal and healthcare variables. Also included were two race-related indices, calculated for this study and based upon census data: Racial Dissimilarity Index (a measure of racial residential segregation), and Index of Income Dualism (a measure of the proportionality of a community's income earned by a racial group relative to its population size).² Bivariate analyses were conducted using Spearman's Rho for the non-parametric interval outcome measure and ANOVA for the categorical outcome measure, with Bonferroni correction for multiple comparisons. The moderate sample size of sixty and the large number of covariates precluded multivariate analyses. All statistical operations were two-tailed and conducted at the $p < .05$ significance level.

RESULTS: Census tracts varied widely on this disparity measure, from -28% (Whites worse) to +93% (Blacks much worse), and were categorized as: Whites worse (n=19), Similar (n=11), Blacks worse (n=21), and Blacks much worse (n=5). Four census tracts had no Black births in 2008. There were no significant linear correlations between covariates and the interval-level birth-outcome-disparity-measure. However, several non-linear relationships were revealed through ANOVA analysis with the categorical-level-birth-outcome-disparity measure: The "Whites worse" category had the highest community high-school-graduation rates (30.3% versus 20.3%-26.2%, $p.011$). The single characteristic shared by the "Whites worse" and the "Blacks worse" communities is high prenatal smoking (21.7% and 26.0% respectively compared to the others with 13.3% and 17.5%, $p.026$). The "Similar Whites and Blacks" category was marked by the highest foreign-born population (280 versus 124-170, $p.022$). Interestingly, the two black disparity categories, "Blacks worse" and "Blacks much worse" were at opposite ends of the spectrum on several features: First trimester prenatal care (75.7% and 88.4% respectively versus 78.0% and 77.9%, $p.025$), teen pregnancy (13.2% and 2.9% respectively versus 7.6% and 11.0%, $p.052$), Median value of housing (\$87,884 and \$118,912 respectively versus \$113,268 and 115,610, $p.062$), and Percent of residential housing that was vacant (7.2% and 3.7% respectively compared to 5.3% and 5.6%, $p.093$).

DISCUSSION: Even within a single county, there is wide diversity in racial birth disparities. Communities have distinct socio-economic and maternal features associated with this disparity. In fact, the greatest variation is seen among the range of communities where Black birth outcomes are worse than White birth outcomes. Prenatal smoking as a risk factor cuts across racial lines, and the communities where White and Black women have similar birth outcomes appear to have the greatest cultural diversity, with the highest number of foreign-born women. Mapping at the community level is a critical step in identifying communities at risk and in targeting the medical and public health resources to combat that community's particular risk profile.

CONCLUSION: Racial disparity in birth outcomes varies dramatically by community, and, even among the same racial group, is associated with different characteristics within different communities.

MANUAL THROMBECTOMY IN CORONARY ARTERY BYPASS GRAFTING

Elbert E. Williams, Leandra H. Burke, Jerry W. Pratt

Western Michigan University School of Medicine, Department of Surgery, Kalamazoo, MI

INTRODUCTION: Stent thrombosis after Percutaneous Coronary Intervention (PCI) is a serious potential complication of stenting. The rate of acute in-stent restenosis is lower with drug-eluting stents compared with bare metal stents (OR 0.29; 95% CI 0.22-0.40 at 6 months). One indication for emergent Coronary Artery Bypass Grafting (CABG) is recurrent acute restenosis during PCI; with extensive dissection and perforation/tamponade being two other major indications.

CASE REPORT: A 45-year-old active duty male with a history of smoking and hyperlipidemia presented with severe chest pain secondary to physical training exercises. An EKG revealed an inferior wall ST-segment elevation myocardial infarction (STEMI). Urgent coronary catheterization was performed and was remarkable for 100% occlusion in the proximal right coronary artery (RCA). An uneventful placement of a stent in the proximal RCA restored TIMI III flow. Despite treatment with aspirin, Plavix, and Integrilin for 18 hours, the patient experienced a second episode of chest pain and was taken back to the catheterization lab the following morning where significant restenosis of the RCA was seen 10 mm distal to the previously placed stent. Multiple stents were placed percutaneously, proximally and distally to the original stent. Two days later, the patient experienced another episode of chest pain accompanied by distended neck veins, hypotension, and elevated cardiac enzymes. In the catheterization lab, his RCA was again found to be occluded. This attempt at percutaneous intervention was unsuccessful and he was referred for emergent surgical revascularization of the RCA. Upon opening the chest, a distended and hypokinetic right ventricle and atrium were immediately visualized. The RCA thrombus extended to the right posterior descending artery. An ateriectomy permitted a 2 French Fogarty embolectomy catheter with a 0.2 cc balloon to be inserted into the RCA. A 5cm thrombus was extracted proximally to the stents. The catheter was advanced further and down the right posterior descending artery and large amounts of thrombus burden were removed after two passes, re-establishing flow. The RCA was irrigated and flushed with heparinized saline. Distal anastomoses to the RCA and obtuse marginal artery were established using a saphenous vein graft.

DISCUSSION: Manual thrombectomy is not currently indicated in coronary artery bypass grafting procedures. However, this technique is used in PCI, albeit with some controversy. It was found that adjunct thrombectomy during PCI improves myocardial perfusion as evidenced by a higher rate of complete ST segment elevation resolution (57.4% versus 37.3%), and reduced microvascular obstruction manifested as scar inhomogeneity as seen on MRI with late gadolinium enhancement. However, there was no difference in overall infarct size or one-year freedom from major adverse cardiac events. In this particular patient, thrombectomy significantly and definitively improved perfusion to the repeatedly occluded vessel allowing for a successful CABG procedure.

CONCLUSION: Manual thrombectomy during CABG is unreported in the literature. This technique is employed in PCI and the efficacy of this practice is being evaluated. With the increasing use of hybrid revascularization procedures employing both CABG and PCI, the use of manual thrombectomy during CABG warrants further evaluation.

UNINTENTIONAL INJURY EDUCATION IN PEDIATRICS

Kerri Beckett, Colette Gushurst, MD
Western Michigan University School of Medicine, Kalamazoo, MI

INTRODUCTION: The Center for Disease Control estimates that 12,175 children from the ages of 0-19 die from unintentional injuries (UI) each year. There is a high rate of non-fatal injuries in this population with an estimated 9.2 million children visiting the emergency room for treatment after unintentional injuries yearly. One main job of a pediatrician is to address the risk of these injuries and prevention methods with parents during well child visits.

RATIONALE: The aim of this study was to investigate how parents feel about the education they are receiving at their child's well visit appointment. Parental recall about what important issues were covered or overlooked in the visits and parental preferences were solicited on how they might prefer this education to be changed and improved.

MATERIAL & METHODS: A parent survey was created to address multiple issues surrounding the topic of unintentional injury education during well child exam visits. There were four age-specific versions of the survey created. After gaining approval from the WMed Privacy Board, the surveys were offered to parents by the receptionist immediately following their well child visits at the WMed Pediatrics Clinic. Participation was voluntary. The surveys were collected and analyzed by the researchers.

RESULTS: A total of 71 parent surveys were collected during a period of two months. Two questions addressed parent's knowledge of unintentional injury risk. Overall, 56% of parents underestimated the rate of unintentional injuries that occur in the pediatric population. Also, 43% of parents felt that their children were at a lower risk of experiencing an injury of this nature than the general pediatric population. In regards to unintentional injury education, 52% of the parents participating in the study reported that this type of education occurred during the well child visit. All of these parents also felt that an adequate amount of time was spent on this education. Overall, 30% of parents indicated they would be interested in further information regarding unintentional injury prevention. There were multiple options for further education, parents indicated that electronic resources (47%) and informational handouts (62%) would be their preferred choices.

DISCUSSION: This study highlights many important aspects of unintentional injury prevention. It demonstrates that many parents are unaware of the risk of unintentional injuries that their children face, often described as optimism bias. When unintentional injuries are addressed at clinic visits, parents report satisfaction that they are being adequately discussed. However, 48% of parents reported that this education did not take place at all. Particular areas that were not discussed during visits according to the surveys include firearms, poison, and choking.

CONCLUSION: These results demonstrate the additional opportunities for improved counseling on these important aspects of anticipatory guidance in the WMed Pediatrics Clinic. The results also provide an opportunity to take parent's suggestions into account when working toward making these improvements.

BILATERAL MYELOMATOUS PLEURAL EFFUSION: A CASE PRESENTATION AND LITERATURE REVIEW

Megan Brown, Usman Saeed
Western Michigan University School of Medicine, Kalamazoo, MI

INTRODUCTION: Multiple myeloma (MM) is a malignant transformation and proliferation of plasma cells which typically infiltrates the bone marrow. Common complications are anemia, hypercalcemia, lytic bone lesions, renal failure, pain and compromised immunity. Extramedullary manifestations are less common and malignant pleural effusion is very rare. We present a case malignant myeloma complicated by malignant pleural effusion in a 81 year old woman.

CASE REPORT: Patient initially presented with mild anemia. Hb was 8.9 with MCV of 110.7 and normal serum ferritin and B12 levels. On further workup an abnormal protein band was found measuring 3.0 on immunofixation and positive for IgA kappa. Bone marrow biopsy confirmed the diagnosis of IgA Kappa Multiple Myeloma. She was started on melphalan and prednisone which was initially tolerated well but the treatment had to be held after one course due to drop in blood counts. She was switched to bortezomib and dexamethasone and received four cycles with improvement in her symptoms and blood counts. The patient subsequently developed dyspnea which progressively worsened the point that she presented to emergency room. The workup at that time revealed large left and moderate right sided pleural effusion. She was admitted by the hospitalist service and left thoracentesis was performed by IR and 550cc of fluid was removed. Cytologic analysis of the pleural fluid revealed numerous atypical plasmacytoid cells with multinucleated forms, nucleoli, cytoplasmic vacuoles and mitotic figures, consistent with multiple myeloma. CT scan revealed extensive pleural nodularity consistent with extra osseous metastatic involvement. The patient was also seen by her oncologist and a plan was made to start her on carfilzomib once she is stable. Her condition unfortunately deteriorated and palliative care was consulted. The patient passed away after one week of hospitalization.

DISCUSSION: In about 6% of patients with MM, pleural effusions develop. In this relatively small subset of patients with pleural effusions, less than one percent are malignant pleural effusion (MPE)[1]. Current literature reveals that less than 100 cases of MPE have been reported worldwide. Within these case reports, MPE is consistently a poor prognostic indicator, with mean survival less than four months[2-4]. The presence of MPE can manifest as the presenting sign of MM or later in the disease course. MPE has been reported in ages ranging from 22-83, equally distributed between males and females, and in IgA, IgG, IgD and light chain subtypes[3-6]. Case reports have demonstrated that despite aggressive treatment with system chemotherapy, radiation, autologous stem cell transplantation or direct chemotherapy injection in the pleural cavity, these effusions often recur within months and ultimately lead to the patient's death [3]. One case report showed resolution of MPE and MM with Bortezomib, a proteasome inhibitor known for its remarkable efficacy in extramedullary MM, indicating a possible therapeutic option for patients with MPE. Although the pathogenesis is unknown, it is theorized that MPE may be a direct extension of thoracic myelomatous involvement; a review of 57 cases demonstrated that half of the patients with MPE had concomitant thoracic skeletal, lung parenchyma or chest wall plasmacytomas, which would provide a source for MPE [3]. Similarly, our patient had a pulmonary nodule, likely metastatic disease.

CONCLUSION: Although rare, more cases of MPE are being described in the literature, with evidence indicating its poor prognosis and lack of efficacious treatment. Due to the severity of MPE, we recommend that patients with pleural effusion be evaluated with protein electrophoresis, flow cytometry, cytologic examination of pleural fluid or pleural biopsy to identify MPE and begin treatment promptly [8-9].

THE IMPACT OF HELMET USE ON PRE-HOSPITAL NEUROLOGIC OUTCOMES IN INJURED MOTORCYCLISTS IN MICHIGAN

Blake Movitz, Caleb Ortega, John Lund, Michelle Lash, Kevin Putman, William Fales,
Michigan State University College of Human Medicine, Western Michigan University School of Medicine
Michigan State University College of Human Medicine, Kalamazoo, Michigan

OBJECTIVE: To demonstrate the utility of statewide emergency medical services information system (EMSIS) database to analyze the incidence of pre-hospital neurologic outcome associated with motorcycle helmet use.

RATIONALE: Despite compelling evidence advocating its health and cost benefits, in April 2012, Michigan repealed its universal motorcycle helmet use law. While EMSIS is a promising means to obtain timely public health information, it has not yet been effectively used for this purpose.

METHODS: This retrospective study is part of an ongoing, state IRB approved research project. Records were compared from April through September of 2011 and 2012. A statewide EMSIS database was used to identify potential subjects injured in motorcycle crashes by filtering on a pre-defined cause of injury field, "motorcycle crash." Data were exported from EMSIS into a separate database, where selected records were manually reviewed to confirm they satisfied inclusion criteria. Records selected for manual review included those indicating safety equipment not likely to be associated with a motorcycle (e.g., safety belts) or when helmet use was unknown. Inclusion criteria were defined as motorcycle crash as a mechanism of injury, knowledge of helmet use, and evidence of pre-hospital neurologic status. Cases were excluded when the subject was riding in a vehicle other than a motorcycle, when the motorcycle crash did not occur on a public street, or when helmet use or neurologic status could not be determined. Data were further analyzed to determine patient demographics, suspected use of alcohol or drugs, and Glasgow Coma Score (GCS). Further subanalysis was performed for cases in which the GCS was less than 15 to exclude subjects with no or trivial head trauma. The pre-hospital neurologic outcome was derived and characterized as good (GCS >12 or "alert/oriented"), intermediate (GCS of 9 to 12), or poor (GCS <9 or "unresponsive" or "responsive only to pain"). Standard statistical analysis was then performed using the T-test and chi-square test.

RESULTS: During the study period, there were 1.3 million records entered into the EMSIS database. A total of 1,331 records were initially identified as motorcycle crashes. Of these, 755 (56.7%) were manually reviewed, resulting in 513 (38.5%) cases being excluded and 818 (61.5%) cases meeting final inclusion criteria. Non-helmeted motorcycle cases accounted for 9 of 398 (2.3%) and 107 of 420 (25.5%) cases in 2011 and 2012, respectively ($p < 0.0001$). There was no difference in age, gender, or race based on helmet use. The mean GCS in 2012 was worse than in 2011 among both helmeted and non-helmeted groups combined (13.7 ± 2.5 vs. 14.2 ± 2.5 , $p = 0.0432$). After excluding those with a GCS of 15, the difference in mean GCS between 2012 and 2011 was even more notable (8.1 ± 5.0 vs 10.9 ± 4.3 , $p = .0013$). In 2012, 9.5% of combined helmeted and non-helmeted subjects had a poor prehospital neurologic outcome compared to 6.4% in 2011 (NS). In comparing helmeted to non-helmeted subjects in both years, suspected use of alcohol or drugs was more than 3 times higher among non-helmeted subjects (39.7% vs 11.1%, $p < 0.0001$). The mean GCS was worse in non-helmeted subjects (12.4 ± 4.7) compared to helmeted (14.3 ± 2.5 , $p < 0.0001$). After excluding those with a GCS of 15, the mean GCS was notably worse in non-helmeted subjects compared to helmeted (7.6 ± 5.2 vs 10.2 ± 4.6 , $p < 0.0059$). Regarding pre-hospital neurologic outcome, 20.7% of non-helmeted subjects had poor neurological outcome, compared to only 5.8% of helmeted ($p < 0.0001$).

CONCLUSION: The Michigan EMSIS was used to effectively analyze the incidence of pre-hospital neurologic outcomes associated with motorcycle helmet use. Pre-hospital neurologic outcomes were significantly worse among non-helmeted motorcycle riders compared to those wearing helmets. Non-helmeted subjects were more likely to be associated with suspected alcohol or drug use. This study further supports the protective benefits of helmet use and provides justification for efforts to reinstate a universal helmet law in Michigan. Our use of statewide EMSIS data further demonstrates the potential utility of this novel information system to support public health policy decision-making, injury prevention and control efforts.

ECONOMIC AND SOCIAL IMPACT OF UPPER EXTREMITY FRAGILITY FRACTURES IN ELDERLY PATIENTS

Nathan C. Kolderman, Jovauna M. Currey, Juan N. Rango, Sergey B. Gukasov, Abby Childs, Vani J. Sabesan
Dept of Orthopaedic Surgery Western Michigan University School of Medicine and Michigan State University
College of Human Medicine,, Kalamazoo, MI

INTRODUCTION: Proximal humerus fractures (PHF) and distal radius fractures (DRF) are common osteoporotic fractures that are a significant cause of morbidity and mortality in the elderly and are expected to exponentially increase in frequency over the next 50 years. Like fractures of the femoral neck they have become a public health concern. The economic impact of fragility fractures is enormous costing the health care system over 19 billion dollars annually. There is extensive literature focused on the effect of increasing age and overall cost of hip fractures including costs of medical and custodial care, functional limitations, reduced quality of life, loss of independence, and inability to work. However literature focused on functional and economic impact of upper extremity fractures is limited.

RATIONALE: Our study focuses on the effect of increased age as it relates to the economic and patient specific impact of upper extremity fragility fractures.

MATERIAL & METHODS: A retrospective chart review was performed on 104 patients ≥50 years old treated at Bronson Hospital from 2004-2012 for a proximal humerus fracture or a distal radius fracture. To better delineate effect of age on for patients with these types of upper extremity fractures, patients were divided into two groups; 51 patients 50-79years old = group 1 and 53 patients ≥80 = group 2. Demographic, admission, inpatient and discharge data was obtained from the electronic medical record and compared between group 1 and group 2. A brief follow up phone survey was performed to verify chart data and provide follow up outcome data.

RESULTS: Thirty one percent of group 1 and 33% group 2 patients had a previous history of fragility fracture. Patients 50-79 years of age underwent surgical treatment for their fracture at a significantly higher (45%) rate than patients ≥80 years of age (21%) (p=0.0082). The average inpatient length of stay was not significantly different between group1 (5.2days) and (4.80days) group 2 (p=0.31). Prior to fracture for group 1 84% lived at home, 7.8% at a skilled nursing facility, and 7.8% had assisted living. Post fracture disposition for group 1, 28% were discharged to SNF, 18% to rehab, 2% to assisted living, 36% to home, and 8% to hospice. Of patients in group 2, 67.9% lived at home, 1.8% with family, 16% at a skilled nursing facility, and 13.2% were at an assisted living facility. For post fracture disposition in group 2 40% were discharged to SNF, 16% to assisted living, 6% to rehab, 34% to home, and 4% to hospice.

DISCUSSION: While hip fractures represent the most dramatic consequence of osteoporosis, fractures of the humerus, forearm and wrist account for one-third of the total incidence of fractures and can be a significant burden to individuals and the community. Our results illustrate the significant burden of upper extremity fractures in terms of loss of independence, inpatient hospitalizations and prolonged nursing home or rehabilitation needs, accounting for considerable health care costs. Reasons are not just related to increasing age or treatment type, more attention needs to focus on goals of costly surgeries and lost opportunities in prevention burdening patients and our healthcare system with recurrent fractures.

CONCLUSION: Our results illustrate the significant burden of upper extremity fractures on elderly patients in terms of loss of independence, prolonged inpatient hospitalizations and rehabilitation needs, accounting for considerable health care costs.

STERIOD MIST NOURISHING AN INVASIVE MOLD: A CASE REPORT OF INVASIVE PULMONARY ASPERGILLOSIS AS A CONSEQUENCE OF HIGH DOSE INHALED STEROID

Sangeeth R. Dubbireddi, MD, Amy H. Attaway, MD, Thomas E. Flynn, MD
Western Michigan University School of Medicine, Internal Medicine, Kalamazoo, Michigan

INTRODUCTION: Invasive aspergillosis (IPA) is commonly seen in immunocompromised neutropenic patients usually presenting innocuously as fever and dyspnea and rapidly progressing to death if not suspected and treated early. Here we present an unusual case of tissue biopsy confirmed invasive pulmonary aspergillosis in a chronic asthmatic on high dose inhaled corticosteroids.

CASE REPORT: The patient is a 44 year old non-smoker female with chronic asthma who presented to the hospital with a fourth episode of fever, increased dyspnea, cough and malaise. Prior three episodes 4 years were marked by similar symptoms, leukocytosis and lung infiltrate. Symptoms and chest x-ray findings resolved on treatment with oral antibiotics (azithromycin, levofloxacin, amoxicillin-clavulunate) all the three times. This admission, her labs were notable for leukocytosis of 13,800 with predominant neutrophils and mild absolute eosinophilia of 0.7, ESR of 40, ANA speckled pattern at 1:320, IgE elevation at 224 (normal <101). Chest x-ray revealed a 3 cm right upper lobe pulmonary cavity suspicious for a neoplasm. Workup including AFB sputum Culture for TB, Urinary Histoplasma Antigen, Blastomycosis Antibody, Fungitel, (generic fungitel=1,3 Beta-D-Glucan) and Galactomannan were negative. CT chest with IV contrast confirmed the 3 cm sized upper lobe cavity and bronchoscopy revealed inflammation of airways with the bronchoalveolar lavage positive for candida on fungal culture. A video assisted thoracoscopy was done and frozen section on the operating table of the biopsy lesion revealed necrotizing granulomatous changes without malignant cells. A complete histopathological report showed dividing hyphae invading into the pulmonary vessels with chronic necrotizing granulomatous changes consistent with invasive aspergillosis. She clinically improved upon treatment with IV Voriconazole.

DISCUSSION: IPA is a clinical entity typically seen in patients with underlying immunocompromise, but is increasingly recognized as a risk factor for patients with chronic lung diseases like COPD. Although there have been at least 5 case reports in the literature of IPA with inhaled steroids in COPD patients, IPA in a chronic asthmatic on inhaled steroids does not appear in the literature search. When untreated, IPA has a greater than 90 percent mortality warranting a high index of suspicion and early initiation of therapy.

CONCLUSION: Our case demonstrates an unusual presentation of invasive aspergillosis and a differential for this must be included on anyone who is on chronic inhaled corticosteroids with worsening symptoms.

METOCLOPRAMIDE IS METABOLIZED PRIMARILY BY HUMAN CYP 2D6 AND IS A REVERSIBLE INHIBITOR OF CYP2D6

Mara Livezey, Erran Briggs, Amanda Bolles, Leslie Nagy, and Laura Lowe Furge
Kalamazoo College - Department of Chemistry, Kalamazoo, MI

SIGNIFICANCE: Metoclopramide is a widely used clinical drug in a variety of medical settings.

OBJECTIVE: To determine which cytochrome P450s are primarily responsible for metabolism of metoclopramide and if any of the cytochrome P450s are inhibited by metoclopramide or its metabolites.

METHODS: LC/ESI-MS was used for identification of metoclopramide metabolites formed by CYPs including 2D6, 2C9, 2C19, 3A4, and 1A2. SMARTCyp and RS Predictor software were used for theoretical predictions of metoclopramide products. AutoDock molecular modeling software was used to visualize potential interactions between metoclopramide and CYP2D6. Enzyme activity assays were used to assess the effect of metoclopramide on bufuralol or dextromethorphan metabolism mediated by CYP2D6.

RESULTS & DISCUSSION: Metoclopramide interacts with CYP2D6 with Type I binding and a K_s value of $9.56 \pm 1.09 \mu\text{M}$. CYP2D6 is the major metabolizer of metoclopramide while other CYPs including 2C9, 2C19, 3A4, and 1A2 also metabolize metoclopramide. The two major products of metabolism are N-deethylated metoclopramide and hydroxylation of the phenyl ring amine-both at sites predicted by SMARTCyp and RS Predictor software. Molecular modeling with CYP2D6 was consistent with formation of both major products. Furthermore, two additional mono-oxygenated products not previously identified were observed. No metabolism at the methoxy group was observed despite computational predictions. Finally, no CYP2D6 inactivation by metoclopramide was observed under conditions of varying concentration or varying time in the presence of NADPH using SupersomesTM or pooled human liver microsomes. However, in Dixon analysis, metoclopramide behaved as a competitive inhibitor with $K_i = 13 \mu\text{M}$.

CONCLUSION: These studies show that while metoclopramide is metabolized largely by CYP2D6, it is not a significant inactivator of CYP2D6.

FUNDING: NIH 1R15-GM086767-01 & -01S1 and NIH 2R15GM086767-02

HIPPOCRATES OF COS. A HISTORICAL EXAMPLE TO FUTURE GENERATIONS OF PHYSICIANS

Luis Toledo-Pererya, James Jastifer

Western Michigan University School of Medicine, Research Department, Orthopaedics Department,
Kalamazoo, MI

INTRODUCTION: In the year of 460 BC the Greek Island of Cos saw the birth of the legendary physician Hippocrates (460 BC-370 BC). Even though this event occurred 2500 years ago, during the Golden Age of Pericles between the Persian and the Peloponnesian Wars, it highlighted the dawning of the greatest medical event ever seen in antiquity; the introduction of rational medicine. This historical study investigates the contribution of Hippocrates, “Father of Medicine,” to the practice of medicine for physicians and medical students of today.

HISTORICAL SOURCES: We utilized early writings of Hippocrates and his disciples from the original Greek that were translated into English by W.H.S. Jones in 1923-1931; these included *The Oath*, *The Canon*, *The Science of Medicine*, *Prognosis*, *Aphorisms*, *The Sacred Disease*, *Dreams*, *The Nature of Men* and *a Regimen for Health* (Loeb Eds., Vols. 1, 2, 4). Another work of Hippocrates called *Fractures*, translated from the Greek into English by E.T. Withington in 1928 (Vol. 3, London), was also used. *The Hippocratic Writings*, edited by G.E.R. Lloyd and translated from the Greek into English by J Chadwick and W.N. Mann (1950, Penguin Classics, London/NY) was reviewed as well. A recent work of J. Jouanna titled *Hippocrates*, translated from the French into English by M.B. DeBovise in 1999 (Johns Hopkins University Press, Baltimore) added a great deal to our work inasmuch as Jouanna quoted extensively from Emile Littré (1839), *Oeuvres Completes D’Hippocrate*, (Chez J.B. Bailliere, publisher).

HISTORICAL FINDINGS: Hippocrates and the members of the School of Cos approached medicine in a very distinct manner unlike anyone else before them. The rational understanding of the biological phenomenon and the explanation of the disease etiology, which had evolved from magico-religious to natural causes, created a new way to characterize medicine, a way which applies equally well to the medicine of today and the future. The Hippocratic physicians considered the four humours (blood, yellow bile, black bile and phlegm) as essential in the explanation of the disease response. Furthermore, prognostication had not been used before in evaluating disease and represented a vital part of the Hippocratic Canon. As far as ethics was concerned, professionalism, compassion and the concept of “I will use my power to help the sick to the best of my ability and judgment; I will abstain from harming or wronging any man by it” (Chadwick and Mann, 1950) was at the center of the Hippocratic moral philosophy. Hippocratic physicians understood the importance of patient-centered medicine had in the care of the sick. Disease by itself did not have the same clinical relevance as the patient response, according to the Hippocratic Corpus. “The cardinal concept in the Corpus was that health was equilibrium and illness an upset, an explanation probably owing much to pre-Socratic attempts” (R Porter, 1997, WW Norton, NY). Treatment was, therefore, conservative and based on diet and exercise if at all possible. Surgery was utilized after trauma, for war wounds, hemorrhoids, fistula in ano, empyema, and wound management (FB Lund, *Ann Surg*, 1935).

CONCLUSION: Faculty, residents, and medical students of our generation have thoroughly practiced Hippocratic medicine, sometimes unintentionally, since the beginning of their educational instruction. Accepting and understanding the clinical evidence, explaining the cause of disease, and maintaining professional ethical behavior in the care of patients has been a long-lasting preoccupation and commitment since the time of Hippocrates.

NOT JUST ANOTHER CAR ACCIDENT: AN UNCOMMON AND REFRACTORY CASE PRESENTATION OF TTP

Andrea M. Landon, Shannon L. Stevenson
Western Michigan University School of Medicine, Kalamazoo, MI

BACKGROUND: Thrombotic Thrombocytopenic Purpura (TTP) is a rare genetic or acquired disease only affecting 4 in 1 million individuals each year (See William's Hematology, Harrison's and EMJ Case Report). Acquired forms often result from cancer, pregnancy, autoimmune disease, medications, illicit substances, and infection. Conversely, genetic TTP results from antibodies against von-Willebrand factor cleaving protease labeled ADAMTS 13 resulting in decreased enzyme activity. Common patients include African Americans at a 9 to 1 ratio and women are 3 times more likely to have the condition with the median age of 40 years at diagnosis. Mortality rates in the untreated are extremely high at 90%. Modern treatment reduces death rates to 10-20% with most disease mortality due to microvascular neurological complications (Medscape, Harrison's). Patients with TTP have varied disease courses from mild anemia and nuisance neurological complaints to recurrent cerebrovascular accidents (CVAs). Disease severity is not directly related to etiology (acquired versus genetic) or degree of ADAMTS 13 activity. Refractory cases occur in 10-30% of overall cases and can include relapsing complications after initial therapy response and those patients without any initial, asymptomatic recovery period. Our patient falls into the latter category.

CASE REPORT: Our patient, CJ, is a 25-year-old African American woman who initially presented with a MVA due to loss of consciousness while driving. Upon thorough evaluation, a diagnosis of CVA secondary to TTP was apparent. Her initial treatment course included 10 days of daily inpatient plasmapheresis. Her platelets recovered from 34,000 to 250,000, but despite this initial treatment response, CJ's tri-weekly outpatient plasmapheresis failed to maintain remission. Her platelets again dropped, this time to 93,000, along with her hemoglobin which fell to 7.9, requiring readmission. During this admission, her daily plasmapheresis produced platelet improvement to 103,000 after only 2 days, and she returned to outpatient tri-weekly plasmapheresis. Once again, her platelet count did not sustain and fell to 60,000 four days after discharge. Now on her third admission, 28 days after the initial CVA, CJ again received daily plasmapheresis with the addition of a single 325 mg (3.2mg/kg) dose of rituximab. Six days into her intensive inpatient care, she experienced a second, rather major, CVA. Upon stabilization in the Neuro ICU the patient was transferred to another tertiary care center for continued workup and exploration of additional treatment options not available at our facility. She continues to follow up with Heme/Onc and Neurology with residual deficits in cognition and motor function.

DISCUSSION: CJ's case exemplifies genetic TTP as her ADAMTS 13 activity measured <5%. Additionally, her other laboratory studies followed typical TTP patterns including high LDH, low haptoglobin, and schistocytes to name a few. What is unique about CJ is her age, initial symptoms, and absolute refractory response to treatment leading to significant neuronal loss. At 25 years she is at the younger end of the age spectrum and to have her initial symptom be an isolated CVA appears rare according to the literature. Case reports commonly cite more obscure neurological complaints, such as wandering numbness and bruising, as initial presentations. She did receive the initial treatment of choice: plasmapheresis. And later, once her status became refractory, the grade 1B recommendation to add rituximab was appropriately utilized. Most TTP patients experience microvasculitis leading to occlusion of small vessels within the brain, hence the obscure neurologic complaints commonly associated with the disease. CJ instead experienced two large vessel infarcts, the first being a large right temporoparietal stroke and the second having a right frontal parietal and posterior cerebellum distribution. Consideration was given to concomitant PFO exacerbating her disease course but was not fully investigated prior to transfer.

CONCLUSION: This case is a unique presentation of TTP considering the age of the patient and the extent and recurrence of CVAs despite proper treatment. Literature reports of rituximab success in refractory cases indicate a median treatment time of 11 days with once weekly dosing to partial restoration of ADAMTS 13 activity and symptom improvement. CJ was due to receive her next dose the day following her second major stroke. Perhaps earlier implementation of rituximab may have spared some neuronal loss and should be considered in future cases not seeming to respond to traditional plasma exchange at the outset.

MAY-THURNER SYNDROME AS A CAUSE OF PULMONARY EMBOLISM

Sourabh Aggarwal, Ravikanth Papani, Sangeeth Dubbireddi, Sarat Vaddineni

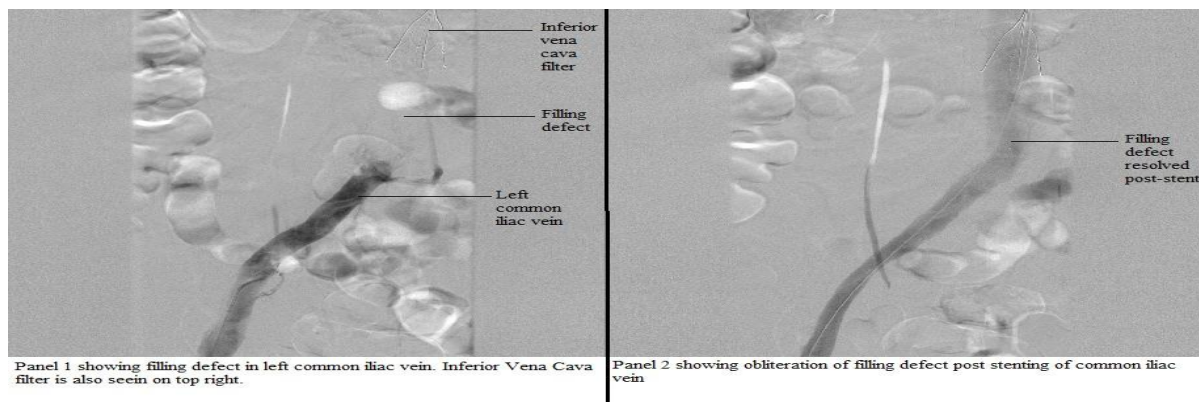
Western Michigan University School of Medicine, Department of Internal Medicine, Kalamazoo, MI

INTRODUCTION: Pulmonary thromboembolism secondary to deep vein thrombosis (DVT) is not very uncommon and can be fatal. However, it is intriguing at times to diagnose the underlying cause of DVT.

CASE REPORT: A 39-year-old female presented with left lower extremity pain with marked swelling and shortness of breath with bilateral chest pain that was worse with a deep inspiration. She denied recent travel or hospitalization. Family and social history were non-contributory. Physical examination was significant for warm, edematous and firm left leg from groin to toe and tenderness in left calf. Complete blood count, metabolic profile, cardiac enzymes (including troponins and CK-MB) and initial EKG was unremarkable. Ultrasonography of lower extremities demonstrated DVT in the left iliac vein (IV), common femoral vein (CFV), femoral vein (FV) and popliteal vein (PV). CT scan of the chest showed multiple bilateral pulmonary emboli. Anticoagulation with heparin was initiated. She was considered for catheter based thrombolysis given the extent of thrombus. Optional IVC filter was placed via right internal jugular vein approach followed by left popliteal vein access with patient in prone position. Thrombolysis of the left PV, CFV, FV and IV was done. A follow up venogram showed resolution of the thrombus in these veins with an unmasked persistent filling defect in common IV as shown in panel 1. Endovascular stent was placed extending from IV to inferior vena cava and post-stent venogram showed resolved filling defects as shown in panel 2. The patient reported resolution of symptoms post-procedure and was started on oral anticoagulation therapy.

DISCUSSION: The persistent filling defect was perceived to be due to intra-luminal webbing consistent with diagnosis of iliac vein compression syndrome (IVCS). May Thurner syndrome, a subtype of IVCS, is classically described as left common IV being compressed by the right common iliac artery increasing the risk of DVT. Pulmonary embolism as presenting complaint of May-Thurner has been rarely reported. The iliac artery by its anatomic orientation entraps the left common IV and by chronic pulsatile force cause extensive intimal hypertrophy of the vein. Histologically, these lesions are composed of elastin and collagen, without inflammatory cellular infiltration.

CONCLUSION: Clinicians should have high index of suspicion for diagnosis of May-Thurner syndrome and venogram and Intra Vascular Ultrasonography aids in the diagnosis of this condition.



LAPAROSCOPIC ADRENALECTOMY FOR GIANT ADRENAL CYST

Alexander J. Connaughton, Leandra H. Burke, and Saad A. Shebrain

Western Michigan University School of Medicine, Department of Surgery, Kalamazoo, MI

INTRODUCTION: There has been much research done on the comparison between laparoscopic versus open adrenalectomy for various adrenal pathologies. Currently, the final decision on what type of procedure to use is determined on a case-by-case basis after informed decision making has taken place with the surgeon and patient's family. However, current literature has shown that when possible, a laparoscopic approach to removing various adrenal pathology, such as a Giant Adrenal Cyst, has many benefits to the patient over an open excision. There are two ways to perform a laparoscopic excision: from a lateral trans-abdominal or posterior retroperitoneal approach.

CASE REPORT: An 18 year-old female presented to our institution with a month history of right upper quadrant and right back pain that became significantly worse two days prior to her presentation. CT of the abdomen revealed a 16.4 x 14.1 x 14.3 cystic lesion with moderately thickened walls in the right upper quadrant likely originating from the adrenal gland. An MRI also showed a 15.9 x 13.3 x 4.2cm complex cystic lesion. The functional status was ruled out by sending for urinary cortisol in addition to metanephrine and normetanephrine. The risks, benefits and alternatives were discussed in detail with the patient and family in regards to performing a laparoscopic versus open right adrenal cyst excision. In the end a Lateral Trans-abdominal Laparoscopic excision of large right adrenal cyst was performed. The excised cyst turned out to be about 20 x 25 cm in size when opened in the back table of the OR. Pathology revealed a benign Adrenal cyst.

DISCUSSION: The literature has shown that there are many benefits to performing a laparoscopic over open adrenalectomy. A current study analyzing 308 papers on MEDLINE revealed that the former is as safe, efficacious, and less expensive than the latter for excising various adrenal pathologies. The laparoscopic procedure does require a longer operative time than the open technique. In our case, the laparoscopic excision of the giant adrenal cyst was a eight hour procedure. However, the laparoscopic procedure has lower post-operative pain reported by the patient. The patients receiving a laparoscopic excision of an adrenal mass also had a shorter hospital stay of 1.5-4 days versus 5.3-10 days for an open procedure. The two common approaches for a laparoscopic adrenal excision (lateral trans-abdominal versus posterior retroperitoneal) both have been found to be equally efficacious with similar operating times and length of hospital stay for the patients. Laparoscopic adrenalectomies are usually only done on cases where an adrenal pathology such as an adenoma or cyst is less than 6 cm in diameter.

CONCLUSION: When a patient presents with adrenal pathology such as an adenoma or cyst that requires excision, it has been found that it is more cost effective and beneficial to the patient to perform the procedure laparoscopically. However, if the adrenal lesion has a diameter greater than 6 cm or there are other issues pertaining to the patient, it is important to determine which technique to use on a case by case basis. In these cases it is important to discuss the risks, benefits and alternatives with the patient and family of performing one procedure over the other. In our case after discussing with the family it was determined to perform a laparoscopic adrenalectomy even though the adrenal cyst was larger than 6 cm.

JAK/STAT MOLECULAR PATHWAY IN LIVER ISCHEMIA AND REPERFUSION

Andrea Landon, Luis H. Toledo-Pereyra

Western Michigan University School of Medicine, Research Department., Kalamazoo, MI

INTRODUCTION: Ischemia/Reperfusion (I/R) injury is a commonly known cause of liver transplant failure. Much research has been done to determine the best way to minimize I/R. With 600/6000 transplants failing due to I/R, and other patients dealing with the long-term complications, it is imperative that new techniques or pharmacological interventions are researched and put into practice. Currently, ischemic preconditioning is the only one of several methods that has been used on patients to prevent I/R. Cytokine and genetic research show that interventions used on the JAK/STAT (Janus Kinase/Signal Transducer and Activator of Transcription) pathway may decrease I/R. Upon ischemic injury, many chemokines and cytokines are released including IL-6, which stimulates the JAK/STAT pathway through receptors and an enzymatic cascade. STAT3 is a transcription factor predominately activated by JAK that has a profound positive effect on liver proliferation and regeneration, so much that it improves survival in mice, therefore, our interest in this molecular pathway.

RATIONALE: Increased JAK/STAT pathway may prove to be beneficial in animal and human transplants with increased survival rates and decreased morbidity associated with I/R injury.

HYPOTHESIS: Will increased stimulation of the JAK/STAT pathway with pharmacological interventions decrease the failure rate of liver transplant surgery caused by I/R injury?

ANALYSIS OF DATA: A PubMed search of the literature and cross-referencing revealed over 40 articles that show the benefits of increased JAK/STAT (in particular JAK/STAT3) duration of activation and concentration after I/R secondary to liver transplantation. **RESULTS:** We encountered multiple approaches of enhancement of the STAT3 pathway such as: stimulation by increasing an initiating factor IL-6 (Matsumoto et al), inhibition of JAK/STAT pathway regulators (Singh et al), inhibition of late phase reactions by deletion of chemokine receptor CXCR2 (Kuboki et al) and earlier stimulation of STAT3 with mesenchymal stem cell (MSC) transplant (Lam et al). Matsumoto's results confirmed that increased IL-6 in combination with ischemic preconditioning was beneficial showing better survival rates ($p=.0374$) as well as enhanced STAT3 activity. Absence of IL-6 abrogated the protective effects of preconditioning ($p<.05$). Singh created a kinetic model that evaluated the roles of regulatory molecules SOSC3, SHP2 and PP2. Results showed that there was increased nuclear STAT3 concentrations with the inhibition of SOSC3, SHP2 and PP2. Kuboki's results regarding the inhibition of CXCR2 showed histological differences, enhanced hepatocyte proliferation ($p<.05$) and increased activation of STAT3 ($p<.05$). Microscopic responses included less accumulation of neutrophils ($p<.05$) smaller areas of necrosis and almost normal liver architecture 96 hours after reperfusion. Lam demonstrated that transplantation with MSC alleviated acute liver injury and decreased ALT and bilirubin levels at 40 hours post ischemia ($p< 0.03$). MSC transplantation also showed increased STAT3 activity up to 72 hours after injury. Elevation was most prominent with administration of Hyper IL-6. Activation of STAT3 led to significant reversal of fulminate hepatic failure, enhanced survival and stimulation of hepatocyte function.

CONCLUSION: The importance of enhanced activity of JAK/STAT (particularly JAK/STAT3) is evident from many different studies. Increased hepatocyte proliferation and decreased necrosis have many beneficial long term effects including increased survivability. The use of better pharmacological interventions to increase JAK/STAT would improve liver protection of ischemic and transplanted livers.

GIANT PARASTOMAL HERNIA WITH MASSIVE BOWEL ISCHEMIA

Jafar Haghshenas, Leandra H. Burke, Saad A. Shebrain

Western Michigan University School of Medicine, Department of Surgery, Kalamazoo, MI

INTRODUCTION: Parastomal hernia (PSH) is one of the most common complications following stomal construction with an overall incidence between 30% and 50%. Even with such a high incidence the majority of these types of hernias are small and asymptomatic, and best managed conservatively. Obstruction, strangulation, and perforation of a PSH, are rare but serious complications prompting immediate surgical intervention.

CASE REPORT: An 81-year-old male presented in transfer to the ED complaining of nausea, postprandial vomiting and severe abdominal pain for 2 weeks. The patient's past medical history was significant for stage II rectal adenocarcinoma with treatment via abdominal perianal resection and end sigmoid colostomy eleven years prior to presentation. In the past year, the patient was admitted for small bowel obstruction (SBO) and was found to have a small PSH for which he declined surgical intervention. Typical episodes of the current nausea and vomiting consisted of postprandial vomiting followed by severe pain around the colostomy site. At the outlying facility, abdominal X-ray showed air fluid levels with dilatation of the small bowel indicating bowel obstruction. Moreover, the stoma appeared non-viable and presumably ischemic, prompting transfer to our ED. On physical exam the patient's abdomen was distended, tender mainly around the LLQ ostomy site, and dark in color indicating dead tissue. Surrounding erythema extended up to 25cm beyond the borders of the colostomy, was firm to palpation and very tender with no appreciable bowel sounds. The patient was taken to the OR for an exploratory laparotomy where the distal small bowel and distal colon were found to be necrotic and gangrenous. The surrounding skin showed cellulitis where the hernia ball was residing. Repair of the strangulation of the PSH was preformed as well as a small bowel resection and subtotal colectomy/splenic flexure mobilization with development of a new end ileostomy in the RLQ.

DISCUSSION: This case illustrates a rare complication of a PSH. Normally, they are asymptomatic and managed conservatively with minimal associated morbidity. Although uncommon, obstruction, strangulation, and perforation represent serious complications that exist with PSH and are absolute indications for surgical intervention. To the best of our knowledge our patient is one of only a few cases of strangulated parastomal hernia with subsequent bowel ischemia reported in the literature to date.

CONCLUSION: Here we present a case of giant parastomal hernia with subsequent SBO and massive bowel ischemia prompting small bowel resection with subtotal colectomy. Despite improving techniques and technologies, parastomal hernias still remain a common problem with often difficult surgical solutions.

**IMPROVING MATERNAL AND INFANT HEALTH THROUGH CENTERING PREGNANCY:
RESULTS OF A TWO YEAR RETROSPECTIVE CHART REVIEW USING A MATCHED
COMPARISON DESIGN**

L. Stork, R. Zielinski, M. Deibel, C. Kothari
Western Michigan University and Borgess Women's Health, Richland, Michigan

INTRODUCTION: Healthy People 2020 goals include reducing infant mortality and morbidity associated with pregnancy(1). Centering Pregnancy is a model of healthcare delivery that unifies health assessment, education and support into a group setting that has been shown to improve prenatal care compliance, prenatal health knowledge and prematurity (2,3).

RATIONALE: Research Question: Is there a difference in select maternal health indicators and pregnancy outcomes between women participating in Centering Pregnancy (CP) and traditional care (TC)?

MATERIAL & METHODS: An analysis was conducted comparing CP participants with a matched comparison group (TC). Data was collected through retrospective records review. IRB approval was obtained from WMU and Borgess Medical Center prior to data collection. For the period of data collection (January 2010 through April 2012), 173 Centering participants were identified and a comparison group of 170 traditional Certified Nurse Midwifery (CNM) care clients were selected matched on race, age and insurance status. Additional maternal data collected included prior pregnancies, height and pre-pregnancy weight. Prenatal variables included number and timing of prenatal care visits, weight gain, and smoking status. Intrapartum variables included mode of delivery and gestational age. Post partum data was collected regarding attendance at 6 weeks post partum visit and breastfeeding.

RESULTS: There was a significant between groups difference in gestation at first prenatal visit 11.8 weeks for TC vs. 10.3 for CP, $p = .031$. There was not a significant difference in mean number of prenatal visits (14.2 for CP vs. 13.4 for TC, $p = .266$). There was not a significant difference in rates of smoking at pregnancy diagnosis (26% [$n = 45$] of CP vs. 30% [$n = 49$] of TC) however 69% ($n = 31$) of the women in the CP group quit with pregnancy diagnosis vs. 18% ($n = 9$) of the TC group ($p < .000$). Additionally, 50% ($n=7$) of those still smoking quit during CP vs. only 8% ($n = 3$) during TC ($p < .001$). There was no difference in pre-pregnancy weights or weight gain between groups, with only 28% of TC and 25% of CP participants gaining the optimal amount of weight. There was no difference in mean gestational age at delivery (39.3 weeks for CP vs 39.5 weeks for TC) or rates of preterm births (5.8% in CP vs. 5.9% in TC). There were no differences in rates of Cesarean section (17% for CP vs. 14% for TC, $p = .443$). Both groups had high rates of attendance at their 6 week post partum visit (92% for CP vs. 88% for TC, $p = .243$). CP participants were more likely to initiate breastfeeding (79% vs. 60% for TC, $p < .001$) and more likely to still be breastfeeding at the 6 week PP visit (65% vs. 45% for TC, $p < .001$).

DISCUSSION: In this study Centering Pregnancy demonstrated promise in reducing smoking rates during pregnancy and improving breast feeding rates. This study also demonstrates that optimal weight gain guidelines must be addressed with women during pregnancy regardless of type of prenatal care. Findings from this study must be viewed in light of the self selection bias. Despite our attempts to control for variance by utilizing a matched comparison design, women who chose CP initiated prenatal care earlier and also were more likely to quit smoking prior to onset of prenatal care than those who chose TC.

CONCLUSION: In spite of these limitations, these results indicate that Centering Pregnancy may result in improved outcomes, particularly in the important areas of breastfeeding and smoking cessation during pregnancy.

PREVALENCE OF PREGNANCY FOLKLORIC BELIEFS AMONG NURSE-MIDWIFERY CLIENT POPULATIONS.

Iris Campbell, Ruth Zielinski, Mary Ann Stark, Mary Lagerwey
Western Michigan University and Borgess Women's Health, Richland, Michigan

INTRODUCTION: To explore prevalence of pregnancy related folklore beliefs by conducting a survey of Certified Nurse Midwives (CNMs) in the United States. Currently CNMs practice in every state in the US and serve a diverse population of women and their families.

RATIONALE: Research Questions included: What are the folklore beliefs most commonly encountered by nurse-midwives in the United States? Does the prevalence of folklore beliefs differ by geography of practice area? Does the type of folklore beliefs differ by the ethnicity and culture of the nurse-midwifery clientele?

MATERIAL & METHODS: Following Institutional Board and American College of Nurse Midwives (ACNM) approval, a geographically diverse sample of 1,000 active ACNM CNM members was sent an email inviting them to participate. The survey was developed following a review of the literature and included 12 pregnancy beliefs. Responders were asked to rate the frequency with which they heard each (never-1, seldom-2, occasionally-3, frequently-4), and whether that particular belief was more common among a certain ethnic/racial group. Participants were asked to provide years and location of midwifery practice. Space was provided for comments.

RESULTS: Response rate was 20% (n=CNMs) Mean years of midwifery practice was 15.8 and response rates were distributed across the four US regions (22.8% NE, 21.8% MW, 29.7% South and 24.8% West). Prevalence of beliefs did not differ by region. Six beliefs (in italics in Table) were more prevalent on preliminary analysis. Participants reported hearing most pregnancy beliefs from clients of a variety of races/ethnicities.

DISCUSSION: Non-judgmental acceptance of patient and family and the importance of valuing tradition and culture in “modern” healthcare is central to the values of holistic healthcare.

CONCLUSION: These research findings provide insight into common pregnancy beliefs and how providers can educate their clients in regard to these beliefs.

Pregnancy belief	Mean score (SD)
Shape of your face predicts the sex of the baby	1.31(.71)
<i>How you are carrying predicts the sex of the baby</i>	3.18 (.76)
<i>Fetal heart rate predicts the sex of the baby</i>	3.73 (.51)
<i>A full moon will start labor</i>	3.27 (.88)
<i>Eating spicy food will start labor</i>	3.01 (.86)
<i>“Mother had a long/quick labor so I will too”</i>	3.23 (.77)
A girl will steal her mother's beauty	1.29 (.64)
Lose a tooth for every pregnancy/baby	1.73 (.80)
<i>Heart burn = full head of hair</i>	3.56 (.76)
Raising your hands above head will cause the cord to wrap around the baby's neck*	2.69 (1.00)
Don't take a bath/go swimming when pregnant	1.97 (.90)
If a woman sees something she will have an ugly baby*	1.48 (.76)

MASSIVE PNEUMO-MEDIASTINUM SECONDARY TO PNEUMOCYSTIS JIROVECI PNEUMONIA IN A NON-HIV PATIENT

Shrey V. Velani, Imad Bagh, Arani Nanavati, Brian Hays

Western Michigan University School of Medicine, Internal Medicine Department, Kalamazoo, MI

INTRODUCTION: Pneumo-mediastinum is a not uncommon complication of barotrauma due to mechanical ventilation, physical injury due to bronchoscopy as well as biological conditions like dermatomyositis, asthma, COPD. Pneumocystis Jiroveci infection is also a cause, especially in patients with HIV and immune-compromised states. We here, present a case of patient with c-ANCA positive vasculitis, who was on cyclophosphamide for 3 months and was diagnosed with Pneumocystis Pneumonia, eventually developing massive pneumo-mediastinum.

CASE REPORT: Patient is a 78 year old female, with past medical history of c-ANCA vasculitis, vasculitis associated myopathy and asthma, who came to ED because of worsening dyspnea, dry cough, wheezing and increased work of breathing. She was found to have profound hypoxia and SPO₂ of 86%. Pertinent lab values include WBC of 6.4, Hemoglobin of 11.2, lactate 3.0, pro-calcitonin 1.48, ESR 48. Arterial pH was 7.50 with pCO₂ of 34 and pO₂ of 64. BMP, UA, Troponin, pro-BNP were essentially normal. She was transferred to ICU and was intubated and mechanically ventilated for 2 days. She was started on vancomycin, zosyn and levaquin for possible HCAP and high dose steroids. During ICU course, she underwent bronchoscopy and culture of BAL. No organism was found but PCR for Pneumocystis was positive. Cell counts were CD3-60, CD4-37 and CD8-26 (cells/mcl). LDH was elevated at 545. RNP-70, U1-RNP, Ro/SSA, La/SSB antibodies were negative. Blood and Sputum Cultures were negative throughout. Following PCR results, she was started on Bactrim and steroids were continued. Other antibiotics were discontinued. Her breathing gradually got better and she was transferred to floor with normalized arterial blood gases. She was feeling better for 2 days after which she started de-saturating (SPO₂ in 70s) even with minor movements, she was requiring 10-12 L O₂ via nasal cannula to maintain SPO₂>90%. Daily X-Rays were being followed, one of which showed fine line of lucency at right basal lobe suspicious of pneumothorax. CT scan of chest was done which surprisingly showed small right basal pneumothorax and large pneumo-mediastinum. The cause of patient's hypoxia was thus discovered but patient did not want any intervention including chest tubes and she eventually passed away.

DISCUSSION/CONCLUSION: Though, many cases of pneumo-mediastinum secondary to PJP have been reported but mostly all of them have been in HIV positive patients. We wanted to highlight the cytotoxic effects of cyclophosphamide leading to immune-compromised state which made patient susceptible to Pneumocystis infection resulting in pneumo-mediastinum which was the cause of her death. In a way, this would be a unique case involving c-ANCA vasculitis, cyclophosphamide use, Pneumocystis infection and fatal Pneumo-mediastinum.

REFERENCES: World Journal of Gastroenterology April 2009 - Pneumocystis jiroveci pneumonia and pneumomediastinum in an anti-TNF α naive patient with ulcerative colitis Takeshi Saraya, Yasutaka Tanaka, Kosuke Ohkuma, Mitsuru Sada, Naoki Tsujimoto, Hajime Takizawa and Hajime Goto "Massive Tension Pneumomediastinum" Takayuki Takimoto, Satomu Morita, Akio Osa and Kinya Abe "Tension Pneumomediastinum in a Patient with Interstitial Pneumonia" UpToDate: Pneumomediastinum, PJP complications

ANTINEUTROPHIL CYTOPLASM ANTIBODY (ANCA) - NEGATIVE GRANULOMATOSIS WITH POLYANGIITIS

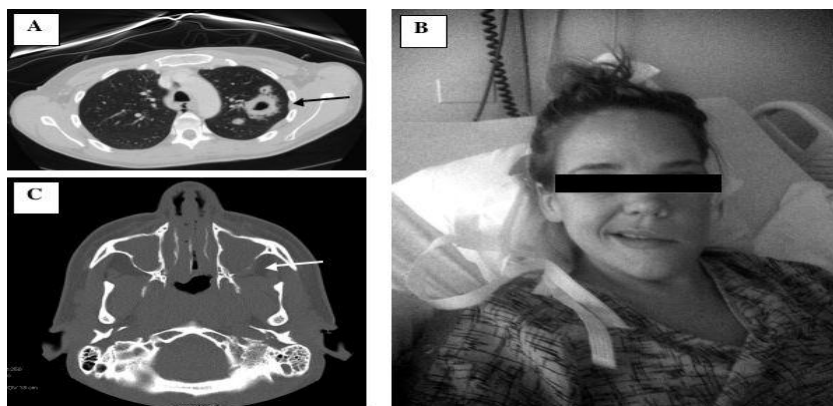
Christine M Dugan, Shannon McCormack, Lorenzo Zaffiri, Sourabh Aggarwal, Susan Bannon, Brian Hays
Western Michigan University School of Medicine, Internal Medicine, Kalamazoo, MI

INTRODUCTION: Granulomatosis with polyangiitis (GPA), formerly known as Wegener's granulomatosis, is a unique clinicopathological disease characterized by necrotizing granuloma formation and vasculitis. It targets the upper and lower respiratory tracts, kidneys, and less commonly the skin, nervous system, and joints. We present a rare case of a woman with acute, limited GPA with negative serology for anti-neutrophil cytoplasm antibodies (ANCA).

CASE REPORT: The patient is a 24yo woman with a 4-month history of sinus congestion presenting with acute worsening otalgia, diminished hearing, cough, and hemoptysis. A saddle nose deformity was appreciated on physical exam, as well as bilateral rhonchorous breath sounds. A thoracic CT (Figure A) revealed a thick-walled cavitary lesion in her left upper lobe and multiple pulmonary nodules. Serology was negative for rheumatoid factor, anti-neutrophil antibody, as well as ANCA. Serum C3 and C4 levels were within normal limits. On the fourth day of admission the patient developed a seventh-nerve palsy (Figure B) and mononeuritis multiplex of the distal right upper extremity. She developed respiratory distress and required the evaluation and treatment of the intensive care unit. A CT of the paranasal sinuses demonstrated bony erosions (Figure C) of the posterior wall of the left maxillary sinus. Sinus biopsy revealed granuloma formation, extensive neutrophil infiltration and vasculitis confirming the diagnosis of GPA. Pulse therapy of high-dose methylprednisolone followed by daily prednisone with weekly Rituxinab was initiated. The patient improved clinically as evidenced by improved hearing and decreased sinus congestion, cough, and work of breathing. At two months, the chest radiograph demonstrates a decrease of disease burden; however, the seventh nerve palsy persists.

DISCUSSION: This case highlights the need for quick and accurate diagnosis in the setting of a rapidly progressive disease with variable clinical manifestations and diagnostic criteria. It also underscores that there is increasing evidence that the widely accepted mechanism of pathogenesis thought to be mediated by ANCA is incomplete. Other mechanisms of pathogenesis should be explored in addition to those mediated by ANCA. This could offer new insights into the progression of disease, as well as provide alternative therapeutic modalities for treatment.

CONCLUSION: 1. ANCA-negative GPA can be a rapidly progressive disease with significant morbidity and mortality. 2. Physicians should use caution when interpreting a negative ANCA serology in the setting of a possible GPA diagnosis. 3. Alternative mechanisms of pathogenesis of GPA need to be explored.



LARGE BOWEL OBSTRUCTION SECONDARY TO MORGAGNI HERNIA IN A MORBIDLY OBESE ADULT

Blake R. Movitz and Saad A. Shebrain

Western Michigan University School of Medicine, Department of Surgery, Kalamazoo, MI

INTRODUCTION: Giovanni Battista Morgagni first reported hernia through the sternocostal triangle of the diaphragm in 1769. Congenital diaphragmatic abnormalities occur in 1/2,000 to 1/4,000 membranes. Morgagni hernias, much less common than the Bochdalek hernia, account for 3 to 4% of all diaphragmatic hernias. Approximately 35% of patients may remain asymptomatic with a Morgagni hernia; however, patients may present with symptoms secondary to intestinal obstruction, strangulation, or respiratory compromise. Most often found in the sac of a Morgagni hernia is the transverse colon, omentum, or liver. In the literature, several case reports suggest that obesity is correlated with Morgagni hernias in adults. Historically, diagnosis was made with the aid of a chest radiograph with or without barium enema. The operative technique has classically been laparotomy or thoracotomy. However, in the last two decades, advanced technology has led to progression in the modality of choice for diagnosis and surgical treatment of Morgagni hernias.

CASE REPORT: We describe a 28 year-old morbidly obese male presenting to our institution with recurrent onsets of acute, sharp, intermittent non-radiating epigastric abdominal pain, nausea, and vomiting with episodes of bloating and constipation, and shortness of breath. Cardiac evaluation was negative for ischemia. Computer Tomography (CT) scan revealed Morgagni hernia with a large portion of transverse colon in the anterior mediastinum. Laparoscopic diaphragmatic hernia repair with a flexible composite mesh was performed. The post-operative course was uncomplicated. Six months since discharge he is without complications.

DISCUSSION: Morgagni hernias are an uncommon diaphragmatic abnormality. Literature suggests a bimodal distribution of symptomatic cases, with peaks in ages under 6 years and above 50 years. Patients of the minor mode typically present with significant respiratory dysfunction and high mortality due to pulmonary hypoplasia. For those represented by the major mode, the diaphragmatic defect is often small and covered by underlying omentum or liver. Such adults may remain asymptomatic until viscera protrude through an enlarged defect. The suggested pathophysiology may elucidate the role of obesity and increased intra-abdominal pressure in precipitating the incidence of symptomatic Morgagni hernia. The risk of bowel strangulation makes early diagnosis and surgical management of Morgagni hernias necessary. In the past, chest radiography with or without barium enema was used in the imaging workup of Morgagni hernias. It was not uncommon for pathology pre-operatively diagnosed as Morgagni hernias to be revealed as a misdiagnosis at the time of surgery, however. Historically, the surgical technique was a transthoracic or transabdominal approach. More recently, a laparoscopic approach to surgically correct the defect has been found to decrease post-operative pain and length of stay. In our case, the use of CT-scan successfully delineated a Morgagni hernia. A laparoscopic diaphragmatic hernia repair with a flexible composite mesh was performed without peri-operative or post-operative complications.

CONCLUSION: This case represents a symptomatic Morgagni hernia in a patient who does not fit the classic epidemiological findings. It highlights the effect of morbid obesity blunting the bimodal distribution historically suggested in the literature. A high index of suspicion for a Morgagni hernia is warranted, as a missed diagnosis can lead to bowel strangulation and respiratory failure, conditions with significant morbidity and mortality. In this regard, patients with unusual demographics present as unique challenges to prompt diagnosis, which may impact surgical approach considerations. The role of CT scan in the diagnosis and laparoscopic surgical intervention proved to be safe and effective. Future research is necessary to enhance the understanding of obesity in the pathophysiology, presentation, workup, and treatment of Morgagni hernias.

CECAL GANGLIONEUROMA: A RARE ENTITY PRESENTS AS A THERAPEUTIC DILEMMA

Christine M. Dugan, John D. Lund, and Lisa A. Miller

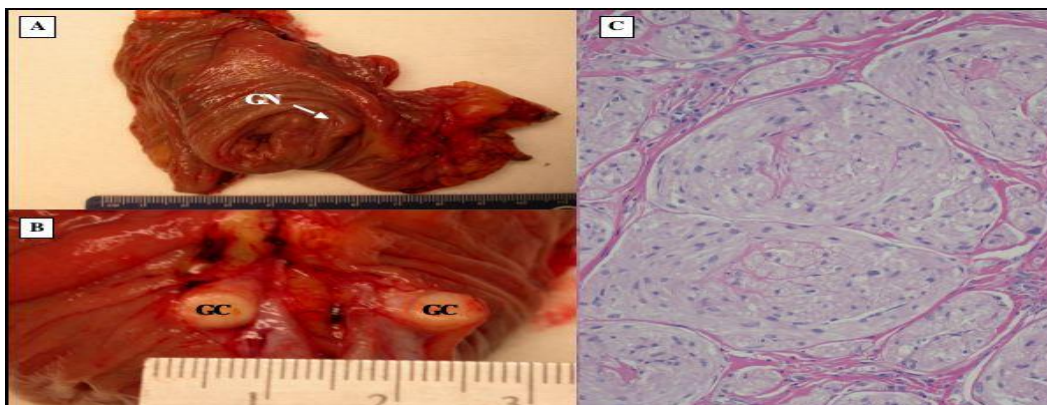
Western Michigan University School of Medicine, Department of Surgery, Kalamazoo, MI

INTRODUCTION: Ganglioneuromas (GNs) are rare tumors of neural crest origin that commonly present in the posterior mediastinum and retroperitoneum. GNs at these locations have been associated with Von Recklinghausen's neurofibromatosis and multiple mucosal neuroma Type 2b syndrome. GNs of the alimentary tract are extremely uncommon. Literature review revealed a single report of a GN of a ileocecal valve; however to our knowledge no other isolated cecal GNs have been reported.

CASE REPORT: Herein, we report the finding of a deeply embedded mass adjacent to the appendiceal orifice identified on a screening colonoscopy in a woman lacking the stigmata of Van Recklinghausen's or multiple mucosal neuroma Type 2b syndromes, such as cafe au lait spots, Lisch nodules, or a marfanoid habitus. The pathology report of the tissue biopsy indicated histological features consistent with a GN. After conferring with the Western Michigan University tumor board, an ileocecectomy was recommended and performed without complication. A solid 1 cm cecal tumor was removed in a ileocecal resection (Figure A) and the bisection of the specimen revealed a homogenous tan tumor (Figure B). Histological analysis demonstrated a well circumscribed spindle cell proliferation arrange in fascicles (Figure C). Immunohistochemistry analysis of the tissue was strongly positive for S100 protein, whereas staining for desmin, CD1-17, DOG1, and smooth muscle actin were negative. These findings are consistent with features of a GN.

DISCUSSION: While most gastrointestinal GNs are well-differentiated, mature lesions with benign behavior characteristics, some have been known to undergo malignant transformation and others have caused gastrointestinal complications, such as obstruction, perforation, and hemoperitoneum. With limited understanding of the malignant potential and morbid complications surrounding these rare and poorly studied lesions, cecal GNs clearly present a therapeutic challenge to physicians.

CONCLUSION: We present the unusual case of a cecal ganglioneuroma in a woman; found incidentally during screening colonoscopy.



CARDIOPROTECTIVE EFFECT OF XANTHINE OXIDASE INHIBITORS IN CORONARY ARTERY DISEASE AND HEART FAILURE

Ryan W Bradstreet, Megan C Brown, Erik M Bobeda, Luis H Toledo-Pereyra
MSU College of Human Medicine and Western Michigan University School of Medicine, Kalamazoo, MI

INTRODUCTION: An elevated serum uric acid level is a known risk factor for cardiovascular disease (Choi, 2007). Xanthine oxidase inhibitors (XOI) are approved for treatment of hyperuricemia; XOI act on xanthine oxidase, an enzyme responsible for uric acid (UA) production, and they effectively decrease UA and reduce oxidative stress in the vasculature (Higgins, 2012). Due to their dual actions, XOI have significant potential to prevent and treat both coronary artery disease (CAD) and heart failure (HF).

RATIONALE: This review evaluates the role of XOI in CAD and HF. We hypothesize that XOI have a cardioprotective effect on patients with, or at risk for, CAD and HF, due to their ability to decrease UA levels and improve endothelial function.

MATERIALS AND METHODS: A comprehensive review of the literature was performed on the effects of XOI on vascular endothelial function and cardiac morbidity and mortality. Ten studies satisfied the inclusion criteria for the review, and consisted of randomized control trials (RCTs), cohort studies, and a meta-analysis from peer reviewed journals printed in English since year 2000. Significant results were determined by p value <0.05. Rajendra (2011), Farquharson (2002), George (2006), and Baldus (2005) evaluated the effects of XOI on endothelial function in patients with underlying cardiac conditions in RCTs with 80, 11, 30, and 18 patients respectively. Higgins (2012) performed a meta-analysis consisting of 40 studies with endpoints measuring endothelial function. Thanassoulis (2010), a cohort with 25,090 patients, Terawaki (2012), a case control study with 178 patients, and Hare (2008), a RCT with 405 patients, evaluated the benefits of XOI on cardiac morbidity and mortality. Noman (2010) measured exercise capacity in a RCT of 65 patients, and Erdogan (2012) measured coronary flow reserve in 39 patients on allopurinol.

RESULTS: Rajendra (2011), Farquharson (2002), and George (2006) found that allopurinol improved endothelium-dependent vasodilation by forearm venous occlusion plethysmography (145% vs 93%, p=0.006), (181% vs 120%, p=0.003), and (240% vs 73%, p<0.001) respectively. Rajendra and Baldus (2005) found that XOI improved vasodilation by flow-mediated dilation (5.4 vs 4.2, p<0.001) and (7.6 vs 5.1, p<0.05) respectively. Rajendra (p<0.001) and Farquharson (p=0.03) also found that allopurinol improved vascular oxidative stress. Higgins (2012) found that with XOI, forearm blood flow increased 68.80% (CI 18.70-118.90%), and that malondialdehyde, a marker of oxidative stress, was reduced by 0.56 nmol/mL (CI 0.26-0.87). Thanassoulis (2010) found that allopurinol was associated with reduced HF readmission or death (P<0.01), as well as all-cause mortality (P<0.01) in patients with gout. Terawaki (2012) and Hare (2008) found that XOI were beneficial for cardiac morbidity in patients with cardiac risk factors (p=0.04) and (p=0.02) respectively. Noman (2010) found that allopurinol improved exercise time (p=0.0003), time to chest pain (p=0.001), and time to ST depression (p=0.0002) in exercise tolerance tests. Lastly, Erdogan (2012) found that allopurinol improved coronary flow reserve (2.20 vs 1.87, p<0.001).

DISCUSSION: Multiple studies have demonstrated the efficacy of XOI in improving endothelial function, cardiovascular morbidity and mortality and functional status in CHF. As hyperuricemia is an important risk factor for cardiovascular disease, these studies support the impact of decreasing UA levels. In addition to decreasing UA levels, XOI improve endothelial function irrespective of the decrease in UA levels (George, 2006). This demonstrates the potential utility of XOI as preventative medications in patients at risk for CAD and CHF regardless of UA levels. These studies have been performed on patients with a history of CAD, CHF and hypertensive nephropathy, demonstrating the effectiveness of XOI on those with underlying CV disease. In the future, a RCT would be beneficial to investigate the effectiveness of prophylactic administration of XOI in preventing CV disease in healthy patients.

CONCLUSION: Allopurinol has demonstrated a cardioprotective effect in both CAD and HF by improving markers of endothelial dysfunction, oxidative stress, morbidity, mortality and exercise tolerance. While current research supports the efficacy of XOI in secondary prevention of cardiovascular morbidity and mortality, the use of XOI in patients with underlying risk factors for CAD should be evaluated to determine the efficacy of this treatment as a primary prevention measure.

POST TRAUMATIC STRESS DISORDER LOST IN TRANSITION: A CASE REPORT

Chris A. Karampahtsis, Robert D. Strung, David C. Dunstone
Western Michigan University School of Medicine, Kalamazoo, MI

INTRODUCTION: The third year of psychiatric residency at Western Michigan University School of Medicine consists of a year-long focused outpatient experience. At the beginning of the academic year, as many as 70 patients are transferred to each of the incoming residents from their predecessors. They must also learn to manage 50 minute sessions, deal with being videotaped, work with rotating supervising faculty, learn to do psychotherapy, and learn a new electronic medical record. Patients may pose obstacles by withholding information, treatment non-adherence, and missed appointments. Residents must quickly and accurately assimilate their patients' diagnoses, psychosocial issues and treatment histories in order to provide safe and effective treatment. How residents do that varies, but common short-cut practices include reviewing the transfer summary, problem lists, most recent progress notes, and perhaps the initial intake evaluation. Residents may or may not ever review the entire record. Given these many challenges, it is understandable that errors in transfer of information are bound to occur and patient care may be adversely affected.

CASE REPORT: DW is a 64 year old, married, Caucasian female who was first seen in our psychiatric clinic in 2006 by a third year resident. The resident's intake note documented that the onset of DW's mental health difficulties followed a traumatic sexual assault at age 24. The resident concurred with her previous community psychiatrist's diagnoses of Bipolar Disorder and Post Traumatic Stress Disorder (PTSD) and continued her on mood stabilizers and temazepam 30 mg for sleep. On the second visit, the patient was switched from temazepam to trazodone. On the third visit the diagnosis of PTSD was dropped with no explanation. Over her six year history in our clinic, five residents participated in her care. The third resident started the patient back on temazepam 60 mg HS when the patient explained that she had done better on temazepam, had a high tolerance for it, and previously required 60 mg. The diagnosis of PTSD did not appear again in any note by the second, third and fourth residents. The issue of her sexual assault was only briefly mentioned by the second resident on two occasions, but not addressed. The fifth resident encountered a very challenging patient who seemed focused only on acquiring more medications. She requested early refills of temazepam on three occasions and became angry when asked about it. Her husband even called to demand the early refills and suggested the dose be increased beyond 60 mg because it wasn't working. With supervisory support, the resident pressed ahead, over loud protests, with a dosage reduction to approved levels. Back on 30 mg, the patient reported nightmares of her sexual assault and then opened up to spend most of one session recounting her trauma in great detail.

DISCUSSION: Although this patient received appropriate treatment for her Bipolar Disorder, her PTSD was not addressed for six years. She was also treated for two years with inappropriately high doses of temazepam, which lead to a benzodiazepine addiction and also likely suppressed her PTSD symptoms. A number of system factors likely contributed: 1) A resident inappropriately dropped the PTSD diagnosis from her problem list. 2) Subsequent residents missed opportunities to pick up the diagnosis from the intake note and from the discharge summary of a psychiatric hospitalization, 3) We changed to a new electronic medical record system which archived some of the notes, including this patient's intake evaluation. 4) The patient was strongly defended against talking about her very painful sexual assault, such that she did not volunteer the issue. 5) Rotating clinic supervisors failed to identify the dropped diagnosis and for a time, the excessive benzodiazepine doses.

CONCLUSION: This case illustrates a challenge that many resident clinics likely face, across all specialties; a challenge for residents, faculty and clinic administration. It is a cautionary tale, and suggests several systems approaches, such as requiring all new doctors to review the initial intake evaluation, a thorough record review for particularly difficult patients, more attention to transitions of care, and quality of care audits tailored to discover "dropped" essential information.

HEREDITARY STOMATOCYTOSIS: A RARE BLOOD DISORDER IN A FATHER AND HIS SON

Shazia Malik, David Homa, Robert Baker

Western Michigan University School of Medicine, Family Medicine, Kalamazoo, MI

INTRODUCTION: Hereditary Stomatocytosis (HSt) is an autosomal dominant blood disorder that comprises a diverse group of conditions. These conditions, all very rare, are comprised of a hemolytic anemia, frequently macrocytosis and the presence of abnormal shape of red blood cells. Management of patients with HSt is unique because transfusion and splenectomy has been shown to lead to morbidity and mortality due to thromboembolic events.

CASE REPORT 1: Father: A 43 year-old Caucasian male with a known history of hereditary stomatocytosis presented initially with complains of sore throat and generalized body aches. His hemoglobin (Hgb) was 7.8 gm/dL; hence, he was given fluids and discharged home with pain medications. After two days, patient returned to ED with complains of more severe abdominal pain and headaches. His physical exam was remarkable for palpable splenomegaly and abdominal tenderness. At this time, his Hgb was 7.5 gm/dL from his baseline of 8.5-11.0 gm/dL and CT scan of abdomen showed marked splenomegaly but unchanged from 2005. A diagnosis of hemolytic crisis secondary to hereditary stomatocytosis was made; hence, he was admitted to the hospital. He was managed conservatively. Despite receiving pain medications and fluids, patient started to complain of weakness and light-headedness, subsequently his Hgb was 6.2 gm/dL. A decision was made to transfuse him with two units of packed red blood cell. After transfusion and continued pain control, the patient's condition improved and after several days he was discharged from the hospital.

CASE REPORT 2: Son: A 19 year-old Caucasian male with known history of hereditary stomatocytosis was admitted to the hospital a week after his father was discharged. Patient presented with left upper quadrant abdominal pain with nausea, vomiting and watery diarrhea. His physical examination was remarkable for jaundice appearance and marked palpable splenomegaly with mild hepatomegaly. Admission labs showed Hgb was 7.6 gm/dL lower than his baseline of 8.6-9.0 gm/dL and total bilirubin of 7.2 gm/dL. Ultrasound of abdomen was significant for enlarged spleen of 21.6 cm increased from 12.7 cm in 2003. He was conservatively managed with fluids and pain medications for his viral illness and hemolytic crisis. In few days, his Hgb was found to 6.3 gm/dL with worsening abdominal pain. He was given 2 unit of packed red blood cell resulting in increased Hgb of 7.6 gm/dL. After the transfusion, patient improved moderately. His Hgb remained stable and did not require any further transfusion. Even though patient's spleen enlarged significantly from 2003, splenectomy was not offered due to increased risk thromboembolic events.

CONCLUSION: Recognition of this disease is important because treatment differs from other RBC disorders such as hereditary spherocytosis or sickle cell anemia. These cases highlight two important principles of managing patients with hereditary stomatocytosis presenting with hemolytic crisis. First the decision to transfuse must take into account the patient's low baseline Hgb and tendency to iron overload. Second, that splenectomy is contraindicated due to risk of thromboembolic events.

HIGH, BUT VARIED, UTILIZATION FROM EMERGENCY DEPARTMENT TO HOSPITALIZATION FOR BOTH VICTIMS AND PERPETRATORS OF PARTNER VIOLENCE

Catherine L. Kothari, Rashmi Kothari, Thomas Rohs, Scott Davidson, Carrie Klein, Amy Koestner,
Mican DeBoer, Rita Cox, Kim Kutzko
Western Michigan University School of Medicine, Emergency Department, Kalamazoo, MI

INTRODUCTION: Intimate partner violence (IPV) assaults lead to hundreds of thousands of injuries every year; 51.3% of female and 41.5% of male victims receive injuries from such assaults. To date, IPV-identification and intervention has targeted victims within the emergency department setting, but with limited success. Although Trauma Surgeons have adopted universal victim-screening as well and trauma services treat the most severe sub-set of injured ED patients, there has been much less IPV research upon admitted trauma service patients.

RATIONALE: With longer treatment periods and more opportunities for privacy, IPV screening and intervention from the trauma service may have more promise than from the emergency department. Furthermore, there may be untapped potential for intervention with IPV perpetrators across trauma service settings. The study goal, then, was to identify the utilization of emergency department and trauma services by criminal-justice-involved domestic violence individuals, both victims and defendants.

MATERIAL & METHODS: This was a cross-sectional study linking secondary data from two Level-1-Trauma-Center hospitals and the county-prosecutor's office: (1) Hospital data included one year (2010) of emergency department (ED) visits, and eleven years of in-patient (IP) injury-related admissions. (2) Prosecutor data contained all charging requests for crimes between intimate partners (N=21,179 crimes, from 2000-2010). Data linking was completed electronically (using LinkPlus, CDC software probabilistic algorithm for linking alpha-numeric values) in two waves, each wave using different matching criteria. In the first wave, data was linked by, in order: Last name, first name, date of birth. Linking criteria for the second wave was: Date of birth, first name, last name. Manual checks were conducted at several steps across the linking process for quality and to verify uncertain matches.

RESULTS: Five percent of ED patients (N=4,563) had been victims of partner violence and four percent (N=4,044) had been defendants at some point in the prior decade (2000-2010). Two-and-a-half percent of patients hospitalized (N=637) had been victims of partner violence and three-and-a-half percent (N=920) had been defendants at some point in the prior decade (2000-2010). Incident-based utilization (within one day, six months and twelve months) varied by visit type and whether the individual was a victim or defendant, as seen in the tables below: INSERT TABLES (see attached abstract) Visits by victims or defendants within a day of the criminal incident, whether emergency department or in-patient, are rare. One hundred fifty-eight within-day ED visits by victims constitute less than one-one-hundredth of a percent (0.09% of 163,995 visits) and 38 within-day In-patient injury-related hospitalizations, while higher, are still only one-tenth of a percent (0.12% of 30,301 visits).

DISCUSSION: Consistent with prior studies, regardless of visit type (emergency department or in-patient) or timing (period before or period after the criminal justice incident), trauma service utilization by both IPV victims and defendants is higher than the general national population. How much higher does, in fact, depend upon visit type and timing, as well as whether the population is victim or perpetrator. Generally speaking, victims have higher emergency department utilization and perpetrators have higher hospitalization rates. Across the board, utilization is higher during the period after the criminal incident than the period before. Also common across the board is the infinitesimal co-occurrence of ED/in-patient injury hospitalization within a day of an IPV criminal incident.

CONCLUSION: Trauma service utilization by both victims and defendants is high, especially during the months after a criminal assault. Opportunities to intervene and identify within the in-patient setting, while low relative to total volume, are currently untapped, justifying further exploration.

SWEET SYNDROME ASSOCIATED WITH A BITTER HEMATOLOGICAL CONDITION

Arani D. Nanavati, Shrey V. Velani, Ross E. Driscoll

Western Michigan University School of Medicine, Internal Medicine Department, Kalamazoo, MI

INTRODUCTION: Sweet Syndrome, also known as acute febrile neutrophilic dermatosis, is considered to be a hypersensitivity reaction which may be idiopathic, a drug reaction or an associated condition of a malignancy. We report a case in which Sweet syndrome was associated with Refractory Anemia with Excess Blasts-2(RAEB-2).

CASE REPORT: 48 years old Caucasian female presented with confluent maculo-papular rash on her arms, legs and anterior part of her chest. She also complained of severe bilateral hip pain radiating to her knees. Patient also complained of easy bruising and bleeding on slight trauma. Vital signs were apparently normal. Pertinent labs- WBC count- 30.8, Absolute Neutrophil count- 15.3, 14% blasts, 12% metamyelocytes, 9 % myelocytes, Hb- 8.5, Platelets 37000. ESR-132, CRP-10.1. X-ray of right hip did not show any abnormalities so MRI was performed which showed avascular necrosis of bilateral femoral heads. 4 mm punch biopsy was performed on a lesion on her shoulder and histopathology of which showed neutrophilic dermatosis. Bone marrow Biopsy was performed and histopathology was sent. Initially differential diagnosis was Leukemoid reaction or Acute Leukemia based on the clinical picture and the lab findings. Meanwhile symptomatic treatment was given. Finally, the bone marrow biopsy histology showed RAEB-2 with associated reticulin fibrosis and aberrant mast cell component. The drug of choice for sweet syndrome was Prednisone but given the presence of avascular necrosis, it was not preferred. Second drug of choice was Colchicine but it was not advisable because of her refractory anemia. So she was given Doxycycline 100 mg bid. Orthopedic surgery was consulted who recommended bilateral hip replacement but during her hospital course, patient's platelet counts frequently dropped below 20,000 so surgery was not advisable so she was treated with Alendronate. Hematology-Oncology was consulted and they started chemotherapy with Vidaza. Finally as the disease process was controlled with chemotherapy, her rash, strength, pain control, alertness, anxiety and depression improved. Currently patient is discharged and she is following up with the Heme-Onc for chemotherapy.

DISCUSSION: Sweet syndrome is an acute inflammatory skin reaction presenting as macules, papules, pustules or nodules with fever and neutrophilia. Out of all the cases 21% of cases are malignancy associated and about 3% of cases are associated with Myelodysplastic syndrome. RAEB is a type of myelodysplastic syndrome which accounts for 25% of MDS. Our case is unique because it has two rare medical diagnoses including Sweet syndrome and RAEB-2- associated with each other along with other complications such as avascular necrosis.

CONCLUSION: Sweet Syndrome can be a presentation of hematological conditions such as malignancy or myelodysplasia. It can be symptomatically managed with Prednisone or other agents and controlling the underlying disease process is the ultimate therapy for the condition.

FIBROMUSCULAR DYSPLASIA PRESENTING AS BILATERAL VERTEBRAL AND CAROTID ARTERY DISSECTIONS WITH UNILATERAL HORNER'S SYNDROME IN THE POSTPARTUM PERIOD

Noah R. Smith, David V. Smullen, Philip A. Pazderka
Western Michigan University School of Medicine, Transitional Year, Kalamazoo, MI

INTRODUCTION: Arterial dissection occurs when a tear in the artery wall allows blood to flow along the laminar plane of the vessel. Major risk factors for dissection are trauma and connective tissue disorders, although spontaneous dissections have also been described. Postpartum cervical and coronary artery dissections have been reported, with difficult labor and prolonged pushing, along with pregnancy related hormonal and hemodynamic changes, suggested as possible etiologies.

CASE REPORT: A 34-year-old woman presented to the Emergency Department 11 days postpartum, complaining of bilateral posterior neck pain. She had an uncomplicated vaginal delivery with epidural block, and developed left-sided posterior neck pain the following day. Subsequently, she developed a similar right-sided posterior neck pain and intermittent headache worsened with reclined or supine position. She reported no known history of connective tissue disease. Physical examination revealed right-sided ptosis and miosis and decreased neck range of motion. CBC revealed slightly elevated platelet count and a normal WBC. Comprehensive metabolic panel was within normal limits. MRI scan was concerning for dissection of the right internal carotid artery (ICA), and CT angiogram confirmed dissection of the distal right cervical ICA, as well as the left vertebral artery (VA) and a short segment of the distal left ICA. A beaded appearance of the VAs was also noted. Patient was admitted to the hospital for initiation of anticoagulation therapy and monitoring. She was started on intravenous heparin drip and bridged to warfarin to prevent thromboembolic complications. The unilateral, right-sided Horner's syndrome was thought to be consistent with a pseudoaneurysm of the right ICA, impinging on sympathetic input. Patient was clinically stable with no new neurological deficits during hospital stay. She was discharged on enoxaparin and warfarin two days after admission, with a plan for at least three months of anticoagulation. Repeat CT angiogram 3 weeks later revealed slightly more prominent intimal flap of the distal left ICA, large lobular pseudoaneurysm of the right ICA, interval improvement of the left VA dissection, and a new, focal dissection within the distal right cervical VA. Cerebral angiogram performed four weeks after initial presentation revealed healing of the dissections of the left ICA, bilateral VAs, and beaded appearances of the bilateral ICAs and right common femoral artery. Horner's syndrome was noted to be improved at 2 month follow-up. MR angiogram of abdomen and renal arteries was normal 3 months after initial presentation.

DISCUSSION: Postpartum cervical artery dissection has previously been described as a rare cause of postpartum headache. A classic triad of unilateral head, face, or neck pain, partial Horner's syndrome, and ultimately cerebral or retinal ischemia is associated with carotid artery dissection, although this triad occurs in less than one third of patients. While postpartum arterial dissections are often spontaneous, this case presents a multivessel cervical artery dissection associated with an angiopathy. The beaded appearance of the patient's arteries is consistent with a diagnosis of underlying fibromuscular dysplasia (FMD). FMD is a nonatherosclerotic, noninflammatory angiopathy of unknown etiology that typically affects medium and large arteries of young to middle-aged women. FMD is classified into three types, based on layer of the arterial wall that is affected: intimal fibroplasia, medial fibroplasia, and adventitial fibroplasia. The medial type is the cause of FMD in 95% of cases, and the "string of beads" appearance on angiography, which represents tubular or focal arterial stenoses, is pathognomonic for medial fibroplasias. Interestingly, the extracranial cerebrovascular circulation (including the carotid and vertebral arteries), are the second most frequently involved vessels in FMD (25-30%) after the renal arteries (60-75%), with associated intracranial aneurysm present 7-50% of the time. The only other case of FMD-associated postpartum dissection presented in the scientific literature described a 29-year-old woman with multivessel coronary artery dissection.

CONCLUSION: Here we present an interesting case of a postpartum woman presenting to the Emergency Department with headache, neck pain, and unilateral Horner's syndrome. She was found to have multivessel extracranial cervical artery dissection, associated with the new finding of FMD on angiography. To our knowledge, this is the first presented case of FMD-associated postpartum cervical artery dissection.

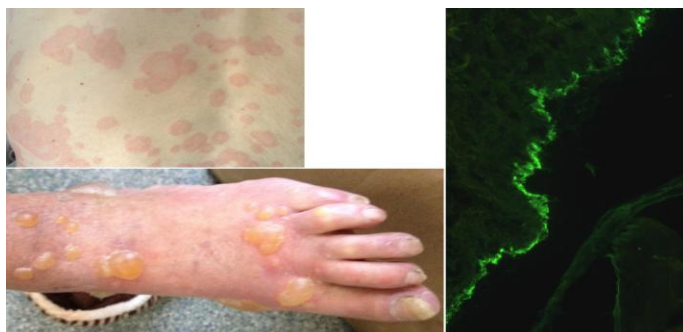
LINEAR IGA BULLOUS DERMATOSIS RESULTING FROM VANCOMYCIN THERAPY!

Shrey V. Velani, Arani D. Nanavati, Melissa Boulden, Pimpawan Boapimp
Western Michigan University School of Medicine, Internal Medicine Department, Kalamazoo, MI

INTRODUCTION: Linear IgA bullous dermatosis (LABD), is a rare autoimmune blistering disease characterized by the linear deposition of IgA at the dermoepidermal junction. Reports of disease incidence from various countries have ranged from less than 0.5 to 2.3 cases per million individuals/year

CASE REPORT: Patient is a 79 years old female who was admitted secondary to Right leg cellulitis and an open wound measuring 11cm x 7cm x 6cm in size which initially began from a thorn prick. The initial insult was 1 month back. Patient has severe diabetic neuropathy and hence does not feel pain. The thorn prick kept on increasing in size and resulted in full blown cellulitis. She was initially being treated as outpatient with rocephin and ciprofloxacin for cellulitis. Meanwhile, vascular surgery was also consulted who diagnosed her with Peripheral vascular disease and she was scheduled for femoral arterial angioplasty on right side. Her cellulitis and wound kept on getting worse and hence she was advised to visit ER 6 days before the scheduled surgery for cellulitis control. She was started on vancomycin and zosyn after admission for cellulitis and wound care management was initiated. She underwent the surgery as scheduled. Two days after the surgery, she started having severe rash which began as blisters cropping up at groins, palms and flexural surfaces like elbow pads, knee pads, axillae and then spreading to dorsum of foot, abdomen and proximal arms. She then also had a confluent rash on her abdomen, back and breast folds. Rash was not itchy. The roof of the blisters was tense and not easily broken. Nikolsky's sign was negative. Her antibiotics were stopped immediately. Infectious Disease service was consulted. Lab results showed normal CBC with differential, normal BMP, normal ESR, slightly elevated CRP at 4.5, negative blood cultures throughout, negative wound cultures and negative VZV viral culture. Punch biopsies were performed at two different locations and sent for Direct Immunofluorescence which came back as "Subepidermal Vesicular Dermatitis with neutrophilic predominance consistent with Linear IgA Bullous Dermatitis". Patient did not have any new lesion after Vancomycin was stopped. All of her blisters were broken manually. She was afebrile throughout. Rash was regressing rapidly. She was transferred to Skilled nursing facility in a stable condition.

DISCUSSION: Both humoral and cellular immune responses may be involved in the pathogenesis of this disease. In particular, tissue injury resulting from an antibody-induced local inflammatory response and the release of proteolytic enzymes by neutrophils and other inflammatory cells may contribute to the development of skin and mucosal lesions. Although multiple case reports have documented drug exposure as a precipitating factor, formal studies validating the existence of drug-induced LABD are lacking. Vancomycin is the pharmacologic agent most frequently reported as a potential inciting factor. Treatment in severe cases includes Dapsone as first line agent, which was not needed in this case.



BEHAVIOR OF BONE MARROW DERIVED MESENCHYMAL STEM CELLS IN COMMERCIALLY AVAILABLE BONE GRAFT AND SCAFFOLDING PRODUCTS

Katelynn E. Shaw, Debbie Reynolds, Terri A. Zachos
MSU/CHM, Kalamazoo, MI

INTRODUCTION: The incidence of nonunions in long bone fractures is estimated to be as high as 5-10%. Naturally occurring animal models of fracture healing may be superior to experimentally created in vivo fracture models due to their more realistic mechanisms of injury, regeneration, repair, and clinical function.

RATIONALE: Autogenous cancellous bone graft has been used to augment bone healing however a limitation of autogenous bone graft that can be obtained from the patient has led to the development of commercial products for use in fractures and non-unions. Commercial forms of freeze-dried corticancellous bone graft, Calcium phosphate scaffolding, and beta-tricalcium phosphate have been developed to enhance bone healing in human, canine, and feline patients. While all have been used to encourage union, less is known about the molecular mechanisms associated with their interactions with cells in the fracture environment.

MATERIAL & METHODS: Bone marrow was harvested from the iliac crests of healthy dogs and BMDMSC were isolated and expanded in monolayer culture. Each commercially available product was seeded with 2×10^6 BMDMSC. Samples were incubated for nine days and media samples were taken in triplicate for each group on days 0, 3, 6, and 9. Also on days 0, 3, 6, and 9 light microscopy and scanning electron microscopy were performed to evaluate cellular growth and attachment. A LIVE/DEAD[®] Viability/Cytotoxicity Assay (Invitrogen, Carlsbad, CA) was performed on samples from days 0, 3, 6, and 9. Real-time RT-PCR was performed on samples from days 0, 3, 6, and 9 to evaluate changes in gene expression in the BMDMSC of alkaline phosphatase, collagen types 1 and 2, BMP 2, and aggrecan. Protein expression was evaluated using ELISA. The genes and proteins evaluated are those consistent with osteogenic differentiation of BMDMSC.

RESULTS: Bone morphogenetic protein 2 (BMP 2) gene expression showed the calcium phosphat scaffold encouraging the greatest up-regulation. Aggrecan protein was detectable in the media through ELISA testing, but not in significant quantities ($p < 0.05$). Collagen 2 showed no significant gene expression changes. Alkaline phosphatase also did not appear to have any significant up regulation.

DISCUSSION: All three products appear to contribute to osteogenesis. Freeze dried corticancellous allograft, however seems to support cell growth more than the other two products. Missing from this study is an evaluation of the mechanical environment induced by loading of a healing fracture site in vivo.

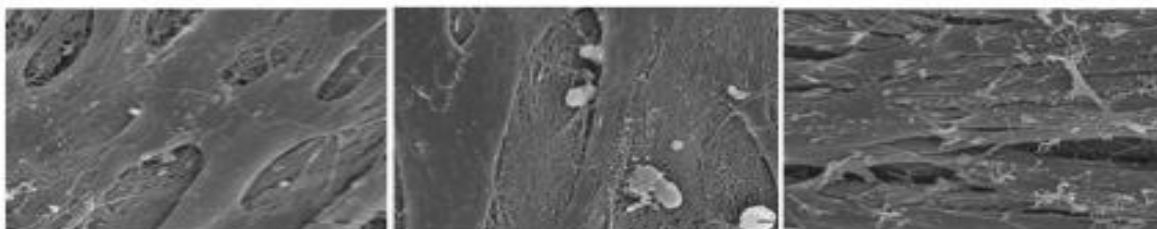
CONCLUSION: Results from this experiment suggest that the 3D matrix structure is an important factor in the biological benefit of these commercial products, rather than an innate ability of product traits to induce differentiation. Future studies should evaluate these commercial products in combination with other therapies, ideally in in vivo studies. This data could be useful in translational applications for the clinical management of delayed and non-union fractures in both veterinary and human patients.

Allograft

BD Scaffold

Cerasorb

Day 9



Magnification: x3000

STRENGTH OF LOCKING AND NON-LOCKING PLATE CONSTRUCTS SUBJECTED TO OBLIQUE LOADS IN SYNTHETIC OSTEOPOROTIC CANCELLOUS BONE WITH A CORTICAL SHELL

Daniel F. Tensmeyer, James R. Jastifer, Peter A. Gustafson, Joseph L. Chess, Bipin Patel
Western Michigan University School of Medicine, Orthopaedic Surgery, Kalamazoo, MI

INTRODUCTION: The last decade has seen a proliferation of locking plate technology in operative fracture care. Due to the perceived increased stability of a fixed angle construct against shear loads, locked plates are preferred by some when stabilization is a concern or when other fixation methods have failed. However, the screw diameter is of primary importance when failure is by normal pullout (along the axis of the screw). Locking and cancellous (non-locking) screws in a hybrid plate may have different outer diameters, yet surgeons must choose between them.

RATIONALE: In the clinical setting, oblique loading patterns are often seen, particularly in the setting of periarticular fractures which are a common justification for the use of locking screws. This oblique loading pattern is a combination of shear and normal loads which make the optimal choice of screw type unclear. Several recent studies have failed to consistently support the biomechanical superiority of locking plate and screw constructs compared to non-locking plate and screw constructs in osteoporotic bone and bone surrogate. The objective of this study was to differentiate the strength of locking and non-locking plate and screws in a hybrid construct subjected to oblique and normal loads in synthetic osteoporotic bone.

MATERIALS & METHODS: This study is an extension of prior work. Plates were affixed with screws to synthetic osteoporotic cancellous bone (density = 0.08 g cm⁻³). The bone was processed into 40 mm by 40 mm by 60 mm specimens and an 8-hole, 3.5 mm hybrid (locking or compression) plate was affixed with either two locking or two cancellous screws. Forces were applied at a 45 degree angle to the plate normal direction (i.e., an oblique load). The load frame crosshead was advanced at 5 mm/min to a displacement of 50 mm. Time (sec), crosshead displacement (mm), and load (N) were sampled at a rate of 128 Hz. In the prior study, cancellous screws were found to carry higher loads (mean 61.7 N vs mean 46.1 N, p=0.020), however, the synthetic bone lacked a cortical shell. In this study, specimens with a 1 mm synthetic cortical shell were used to study the effect of the cortex. As a further extension of the prior study, loads were also applied in the normal direction to the plate. Thus, the combined tests cover a broad range of physiologically relevant cortical thicknesses and load types.

RESULTS: For oblique loads with a cortical shell, the locking construct is stronger (167N vs 154N, p=0.053). For normal loads with a cortical shell, the non-locking construct is stronger (123N vs 108N, p=0.021). After clinical failure of the cortex, locking screws cut out whereas the cancellous screws pulled out. The results must be carefully interpreted in context of the failure mechanisms of the cortical shell and its thickness.

DISCUSSION: The current study suggests that clinical decisions about the use of locking or cancellous screws in hybrid fixation should take into consideration the physiological load mechanisms, the cortex thickness, and the screw diameter. In osteoporotic surrogate bone without a cortex, cancellous screws provide greater strength when an oblique load is applied. When the surrogate bone has a cortex, locking constructs provide greater strength.

CONCLUSION: The clinical significance of this study is that difference in fixation strength between locking and cancellous screws is more complicated than the contribution of the interface between the screw and the plate. It also includes the presence of a cortex, the physiologic loading mechanism, and the screw design.

SPLINTER HEMORRHAGES NOT CAUSED BY INFECTIOUS ENDOCARDITIS, AN EXTREME CASE OF THROMBOANGIITIS OBLITERANS.

Devin Malik, Kevin Struzzieri, Timothy Schubert, Gagan Preet, Sourabh Aggarwal, Heidi Egloff,
Mark Loehrke

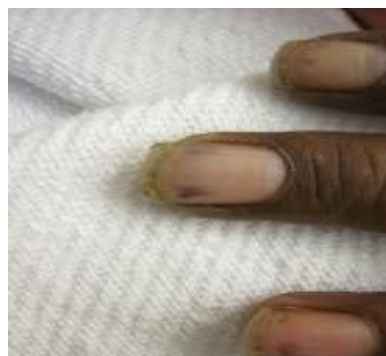Western Michigan University School of Medicine, Department of Internal Medicine, Kalamazoo, MI

INTRODUCTION: Splinter hemorrhages are small areas of bleeding that occur on finger and toenails as a result of damage from inflammation, embolic disease or trauma. It is most commonly associated with infective endocarditis and is a sign of systemic inflammatory disease. Upon review of the literature on thromboangiitis obliterans, we were unable to find many instances that documented the development of splinter hemorrhages.

CASE REPORT: We describe a 51 year old African-American man with no significant past medical history besides hypothyroidism. He endorsed a greater than 30 year history of smoking cigarettes, as well as occasional marijuana use. He presented to the ER with complaints of diffuse muscle pain for 2 weeks that was attributed to strenuous activity (riding his bicycle around town collecting scrap metal for money). On admission he had a mildly elevated creatine kinase of 560 and was started on IV fluids for suspected mild rhabdomyolysis. Over the next 3 days he developed severe pain in bilateral hands associated with splinter hemorrhages and petechiae, especially on distal fingertips. These lesions, as well as his pain, got progressively worse during the hospitalization period. A consulting rheumatologist performed an unremarkable workup which included the following negative tests: ANA, RF, ANCA, anti-centromere, and cryoglobulins. His CRP was elevated at 30.2 mg/L and he had an ESR of 53mm/hr. An arterial duplex ultrasound showed a normal flow proximal to the wrists in bilateral hands, but no flow distally. A transesophageal echocardiogram was performed to rule out endocarditis; and was negative for vegetations. Due to rapid progression of the symptoms, including risk of limb viability, the patient was transferred to a major medical center where interventions could be performed that was beyond the capabilities of the primary hospital. This treatment included IV prostaglandins. Upon admission to the major medical center, the patient provided a more comprehensive history. He admitted to periodic episodes of painful, pale digits that occurred during strenuous activity and/or exposure to cold temperatures. These symptoms are similar to those that present in Raynaud's phenomenon.

DISCUSSION: Thromboangiitis obliterans, also known as Buerger's disease, is an obliterative vasculitis that affects medium to small arteries, usually in distal extremities. The disease is associated with tobacco smoking and has a higher prevalence in men. This disease can lead to digital ischemia, necrosis, and gangrene. The treatment is smoking cessation; however, in advanced cases, this may not be sufficient to stop the progression of the disease. Other associated findings include a "cork-screw" appearance of arteries on an angiography. Unlike some other vasculitides, steroids are not the answer for treatment. Surgical bypasses are occasionally tried but not always successful. Patients who continue to smoke may end up requiring amputation of affected extremities. In the case of this patient, he opted to not cease tobacco use and eventually required amputation of his right arm distal to the elbow and several fingers on his left hand.

CONCLUSION: Subungual splinter hemorrhages are an uncommon presentation that precedes diagnosis of thromboangiitis obliterans. Early recognition of this disease followed by smoking cessation may represent the only potential preventative measure in avoiding limb amputation and the resultant physical handicaps.



OLD DRUG, NEW PROBLEM. A CASE OF LINES: LEVAMISOLE-INDUCED NECROTIC SKIN SYNDROME.

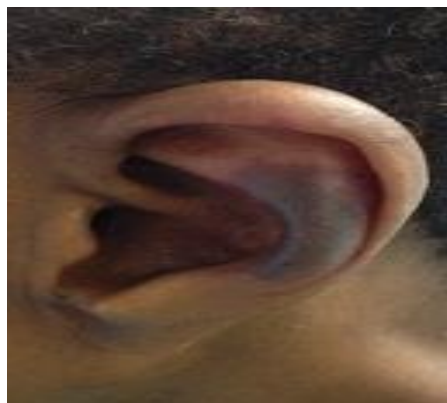Devin Malik, Lorenzo Zaffiri, Rasha Abdulmassih, Susan Bannon
Western Michigan University School of Medicine, Department of Internal Medicine, Kalamazoo, MI

INTRODUCTION: Levamisole is a veterinary antihelminthic and chemotherapy agent that was previously used in humans and animals for its immunomodulatory effect. The major side effects which led to it being taken off the market are fatal neutropenia and potential necrotizing skin rashes. Levamisole is increasingly being used as an adulterant in cocaine as it adds weight and augments the euphoric effect through the dopaminergic pathway. In 2009, the Drug Enforcement Agency estimated that 69% of the cocaine in the U.S contains levamisole.

CASE REPORT: We describe a case of a 59-year-old woman with past medical history significant for chronic hepatitis C and cocaine abuse who developed a painful violaceous purpuric rash on her extremities, cheeks, nose, and ears. During a previous hospitalization, she underwent an extensive work up for neutropenia including peripheral blood smear and bone marrow biopsy that showed no evidence of dysplasia, fibrosis or malignancy. And no conclusion was reached about the etiology. During the present admission laboratory investigations revealed significant neutropenia with an absolute neutrophil count of 300cells/mm³, positive ANA, c-ANCA, p-ANCA, cryoglobulins and cardiolipin antibodies, as well as negative HIV antibodies and RPR. Inflammatory markers were elevated with an ESR of 126 mm/hr and CRP of 6.5 mg/L. She last used cocaine 2 weeks prior to admission. The rash on her ear is pictured.

DISCUSSION: Levamisole-induced vasculitis has demonstrated the presence of autoantibodies including ANA, anticardiolipin, c-ANCA, and p-ANCA. It is still equivocal whether the drug induces the autoantibodies or if it is elicited after exposure to levamisole in people with genetic predisposition. The literature consistently describes purpuric skin lesions on the face, namely the helices of the ears and both upper and lower extremities in individuals with a history of repetitive cocaine use. This coupled with neutropenia raises the suspicion for levamisole toxicity. There have been reports of necrotic skin rashes so severe, that skin grafting and amputation were required. Furthermore, there is increased likelihood for an overwhelming life threatening infection as neutropenia develops. The mainstay of treatment is abstinence from levamisole which can lead to reversal of neutropenia. The skin rash may or may not improve after discontinuing the drug.

CONCLUSION: Health care providers need to be vigilant in recognizing the potential life-threatening effect of levamisole adulterated cocaine and be able to recognize the clinical scenario in which it presents.



UNCOMMON SIDE EFFECTS TO MEDICATIONS IN A PATIENT WITH CATATONIA

Brandon G. Moore, Mark Kanzawa

Western Michigan University School of Medicine, Psychiatry, Kalamazoo, MI

INTRODUCTION: We present a case of benign catatonia in a 26-year-old male who developed uncommon side effects to medications that complicated the clinical course of his treatment. The appearance of multiple uncommon side effects in the same patient raises the question if the patient's catatonic condition predisposed him to this fate. This case also reminds the clinician that even benign catatonia, can present with acute medical signs that must be quickly assessed and attributed to their proper cause so that the patient may emerge from their catatonia without sequelae.

CASE REPORT: Our case of a 26-year-old male with treatment resistant depression presented with initial agitation at home that developed into catatonia. He had ceased eating or drinking fluids since two days prior to admission. His catatonic symptoms included flaccid immobility and mutism. On the day of admission we started the patient on oral dissolving olanzapine to treat his mood as he was already receiving fluoxetine. He also received an intramuscular injection of lorazepam, which partially released his catatonia allowing him the ability to talk and swallow fluids and food. However, this medication started a cascade of uncommon side effects starting with singultus (hiccups) that lasted three days. The patient received a one time oral dose of chlorpromazine, (Thorazine) 50 mg, which is an accepted treatment modality for intractable singultus. Unfortunately within one day of receiving chlorpromazine, he developed a 102.7-degree fever, his pulse increased to 138, and he was diaphoretic. His serum iron level was low @ 24 (45-182). His fluoxetine, Zyprexa, and Thorazine were all discontinued. The patient's temperature, pulse and diaphoresis returned to normal values later that afternoon. Myoclonus and involuntary movements of the left arm complicated the diagnostic picture also as he now had some symptoms of both NMS and Serotonin Syndrome. Eventually his mood became less depressed and his thought blocking resolved when lithium 1,800 mg/day was added to Divalproex Sodium 1,500 mg/day.

DISCUSSION: The signs and symptoms of catatonia may be subtle and easily missed. In one study, catatonia was found in 1-2% of all medical admissions to a hospital, and another study found 9% of admissions to a psychiatric hospital were due to catatonia. It is our proposal that catatonia is often missed. Even though catatonia may be correctly diagnosed in a patient, their clinical course may quickly change. Some catatonic patients cease eating and drinking fluids thus increasing their chances of developing other serious conditions. Because of this, the clinician may decide to release the patient from catatonia by initially using intravenous or intramuscular lorazepam followed by oral lorazepam. In a handful of these cases, there are reports of males developing singultus, or hiccups, after receiving lorazepam, which is commonly treated with the use of chlorpromazine. In addition to receiving benzodiazepines to treat and prevent the recurrence of catatonia, patients are prescribed medications such as conventional and atypical anti-psychotics to treat their underlying psychiatric condition. Thus provided increased risk of side effects such as neuroleptic malignant syndrome (NMS). Early signs of NMS can develop especially when there is an increase in the dose of the anti-psychotic. However, the appearance of NMS within a day's introduction of an anti-psychotic is even less common. Our patient presented with only some of the classic sign of NMS but there is literature to support that these are indeed the beginnings of NMS and that low serum iron may be one of the earliest signs.

CONCLUSION: This case illustrates how a benign catatonic state may predispose the patient to uncommon side effects to medications and complications such as NMS, Serotonin Syndrome, or NMS. This case demonstrates the need for the entire treating staff to carefully observe the vital signs and symptoms of catatonic patients. The staff must be poised to detect any change or lack of change in mental status and make the appropriate changes in treatment to negotiate any complications to avoid a cataclysmic event. As a patient emerges from catatonia and can contribute his own subjective complaints, the treatment can become more focused. This will further enhance the chances of the patient making a complete recovery.

MULTILIGAMENTOUS KNEE INJURIES IN THE MIDDLE AGED AND ELDERLY PATIENTS

Paul J. Danielsky, Vani J. Sabesan, Vinay Sharma

Western Michigan University School of Medicine, Orthopaedic Surgery, Kalamazoo, MI

INTRODUCTION: Multiligament knee injuries (MKI's) are rare but serious injuries with significant morbidity to the patient. Despite proper treatment, patients can experience poor outcomes. The incidence of knee dislocations among orthopedic injuries is less than 0.02%, and thus there are few high level studies reporting the results of patients treated surgically. The combination of fractures and MKI's remains controversial but there are evolving treatment recommendations. Recent literature has shown that operative treatment with ligament reconstruction of MKI's leads to improved results compared to non-operative treatment with limb immobilization. Early ligamentous reconstruction within three weeks has been shown to improve functional and clinical outcomes. Currently, there are no studies focusing on elderly patients with MKI's in combination with tibia fractures, as previous studies include isolated MKI in patients mostly in their twenties through forties. Most studies do not consider surgical treatment for patients sixty or older. As a result, there is no well-established treatment algorithm for elderly patients with these complex injuries, leaving the surgeon with total knee surgery as a salvage operation, which may not be an appealing option for an active middle aged or elderly individual. We are reporting two cases of MKI's with concomitant fractures in patients fifty years of age or older. Our purpose is to provide a review of the literature and guidelines for more elderly patients with these types of complex traumatic injuries

METHODS: We are reporting two cases of MKI's with concomitant fractures in patients fifty years of age or older. Two patients were included s/p motorcycle and bicycle accident who both suffered MKI's with a concomitant tibia plateau fracture. Both patients underwent open reduction and internal fixation of their tibial plateau fractures, and were placed in a knee immobilizer postoperatively. Detail review of future surgical options including ligament reconstruction were discussed with both patients but they declined treatment.

RESULTS: For patient one, at follow up he developed some lateral subluxation of the tibia. He was referred to a joint specialist who recommended total knee arthroplasty once the patient's pain was no longer controlled by non-operative means. Nine months after his injury, he has not sought total knee arthroplasty despite persistent subluxation. The second patient underwent ORIF for his tibial plateau fracture with successful healing. He underwent aggressive physical therapy and was able to optimize his knee function and mobility. At six month follow up, the patient had regained his strength and was ambulating without assisted devices with a hinged knee brace.

DISCUSSION: Extensive review of the literature illustrates the limited evidence on these types of complex knee injuries. Patients with MKI and tibial plateau fractures require a complex treatment algorithm which after extensive review of the current literature and this cast can provide optimal treatment recommendations or guidelines.

ASSESSING THE COMPLIANCE OF TATTOO ESTABLISHMENTS WITH STATE REGULATIONS IN THE KALAMAZOO AND SURROUNDING COMMUNITIES

Scott J. Cressman, David A. Homa, Anny Ching, Richard R. Roach
Western Michigan University School of Medicine, Internal Medicine, Kalamazoo, MI

INTRODUCTION: Tattoos have historically been associated with a variety of medical complications and infections, including hepatitis C and HIV. Since the development of Universal Precautions in the medical environment, these same precautions have been adopted by body artists (tattoo artists) as a means to limit said complications. In addition, State and Federal regulations have been initiated to protect individuals receiving tattoos, including the December 2010 enactment of the Body Art Facilities Act or Public Act 375 in Michigan. This act requires all tattoo artists to operate within a licensed body art facility and follow specific protocols. The objective of this study is to evaluate and assess the compliance of area body art establishments with the Michigan Department of Community Health Requirements for body art facilities, as specified in the Body Art Facilities Act.

RATIONALE: Licensure of body art establishments is dependent on the owner/operator of each establishment, and not necessarily the individual artists. We wished to evaluate PA 375 knowledge and compliance among tattoo artists, as these are the individuals making actual contact with body art clients.

MATERIAL & METHODS: A list of all licensed tattoo establishments in Kalamazoo County, Michigan, was compiled (19 total). Questionnaires were distributed in person, and efforts were made to survey one tattoo artist at each body art establishment, with each one response serving as a representation for the practices within the respective establishment. No identifying names, addresses or other data to identify specific establishments were used in collection of questionnaires. Responses were recorded and analysis was performed.

RESULTS: Preliminary analysis of first 5 responses is as follows. Demographics include 80% (4/5) private contractors trained through apprenticeship, 20% (1/5) owners reportedly self-taught, with body art experience ranging from 3.5 to 11 years. 100% (5/5) of respondents reported that their establishment is licensed through and inspected by the MDCH. Of the respondents, 100% (5/5) follow the MDCH regulations regarding the non-smoking policy, minimum age requirement, parental consent for minors, and the refusal to work on intoxicated clients. In addition, 100% (5/5) of respondents report completing training on bloodborne pathogens and 80% (4/5) report having received at least one dose of the Hepatitis B vaccine, with 40% (2/5) reporting 3+ doses, 20% (1/5) reporting 2 doses, and 20% (1/5) unsure. In regards to a sterile environment, 100% (5/5) report using 3 or more gloves on each client, deposit used needles into a marked container, use an autoclave or a sterilizer, and perform spore detection tests on the sterilizer at least monthly. Screening for underlying diseases is reportedly performed by 80% (4/5) of the respondents, although some variants in particular diseases screened were reported.

DISCUSSION: Preliminary results show that levels of awareness and compliance with Public Act 375 are reported to be high among tattoo artists in licensed facilities in Kalamazoo County. A majority of artists report using sterile technique, providing education materials and consent information, and following many other guidelines laid out in the law. These results may reflect that those who completed the survey were those within licensed establishments who were most comfortable in their knowledge. This group of artists likely also represents the most informed and compliant fraction of local tattoo artists. Possible future studies may be aimed at assessing the level of compliance among unlicensed tattoo artists and/or artists lacking formal office space in comparison to licensed tattoo artists.

CONCLUSION: While accurately assessing compliance with the Body Art Facilities Act, including its safety oriented requirements and protocols, would require observing tattoo procedures from start to finish, this study shows that those operating in licensed facilities have a basic knowledge of the requirements and report compliance.

BLASTOSCHIZOMYCES CAPITATUS AS A RARE CAUSE OF INVASIVE FUNGAL INFECTION IN A 20 MONTH OLD GIRL WITH ALL

Christina G.R. Lang, Elizabeth R. Doherty, Katharina Elliott, Thomas Flynn
Western Michigan University School of Medicine, Kalamazoo, MI

INTRODUCTION: Invasive fungal infections (IFI's) are a well recognized cause of morbidity and mortality in immunocompromised patients. Risk factors include duration and severity of neutropenia, antibiotics, and use of cytotoxic chemotherapy or corticosteroids. The most commonly identified IFI's include *Candida* and *Aspergillus* species, but the emergence of rare fungi is increasing. We present a case of a 20 month old girl admitted for fever and neutropenia diagnosed with disseminated fungemia secondary to *Blastoschizomyces capitatus* (BC), an extremely rare and highly lethal fungal infection. Her presentation, course, outcomes and proposed risk factors will be reviewed. Epidemiology: The majority of BC cases have been identified in Europe, particularly in the Mediterranean. To date, 99 cases of invasive BC have been reported worldwide with 5 in the United States. This is the first documented US case of invasive BC in a pediatric patient.

CASE REPORT: JB was a 20 month old girl with MLL-rearranged pre-B ALL (high risk variant) undergoing consolidation therapy (Children's Oncology Group protocol AALL1131) when she was admitted with fever and neutropenia in the spring of 2012. She had completed a course of clofarabine, cyclophosphamide, and etoposide 4 days prior to admission. She presented with systemic inflammatory response syndrome and absolute neutrophil count (ANC) of zero. Tobramycin, vancomycin, and piperacillin-tazobactam were initiated with resolution of fever and improved hemodynamics within 36 hours. An initial blood culture grew *Streptococcus pneumoniae*. ANC did not recover, and all antibiotics were continued. On day 6, high fevers recurred and Amphotericin B (AmB) was started. Blood cultures from day 6 were positive for fungal yeast with branching hyphae, presumed *Candida*. On day 15, positive identification of BC was made. The patient was double covered with voriconazole and AmB. Throughout these two-plus weeks, JB showed decreased activity and increasing nausea, vomiting, and diarrhea. Her 6 week hospital course was tenuous with multiple complications including acute respiratory failure and small bowel obstruction requiring exploratory laparotomy with resection of a fungal fibrotic stricture. She returned to the OR approximately 2 weeks later to take down her ostomy and place a GJ tube. At that time, cholecystectomy for biliary obstruction and pancreatitis was also performed. The ileum leading up to the ostomy had patchy dark green spots and 36 cm were resected. Ultimately, JB had disseminated fungal disease from BC involving her blood, bowel, gallbladder, liver, spleen, sputum, and retinae. She was discharged home on AmB and voriconazole after modest ANC recovery. Months later, she was found to have pleiocytosis on cerebrospinal fluid surveillance, and MRI was consistent with fungal meningitis. Antifungals were temporarily escalated. As of the writing of this abstract, the patient is set to resume chemotherapy for her ALL.

DISCUSSION: While BC may be ubiquitous in the environment as a saprophyte that can colonize human skin flora and mucosa, it is increasingly recognized as an opportunistic fungal pathogen in select climates and hosts. Documented cases of BC in the US are extremely rare. Climatic factors appear to play a role as the geographic distribution of reported cases is restricted. Most cases (87%) are observed in Europe, primarily in the Mediterranean region during the hottest period of the year. Of the reported BC infections, approximately two thirds occurred in locations below 44° northern latitude, characterized by a climate with hot, dry summers and mild, wet winters. Our case has unique features, and to our knowledge is the sixth case reported in the US. Our patient presented in June after a mild winter and an unusually hot spring. Other suspected predisposing factors include her rural home and her mother's profession as a large animal veterinarian.

CONCLUSION: Disseminated BC has resulted in high rates of morbidity and mortality. We propose that this index case could prompt discussion of surveillance studies and a higher index of suspicion for this emerging fungal pathogen, particularly in neutropenic patients with underlying hematologic malignancy.

OPTIMAL AUGMENTED GLENOID IMPLANT SIZE FOR MODERATE TO SEVERE GLENOHUMERAL OSTEOARTHRITIS

Vani Sabesan, Mark Callanan, Vinay Sharma
Western Michigan University School of Medicine, Kalamazoo, MI

INTRODUCTION: Glenoid loosening is the leading complication associated with total shoulder arthroplasties and the main cause of component failure. The literature demonstrates that glenoid component malposition is associated with excessive retroversion, early component lucent lines, and component loosening. Excessive glenoid component retroversion is correlated with greater amounts of pre-operative glenoid retroversion with incomplete correction of retroversion particularly when using standard glenoid components. Historically the most commonly employed surgical interventions to correct posterior glenoid bone loss have been asymmetric anterior glenoid reaming or posterior glenoid bone grafting. This correction of moderate to severe glenoid retroversion by asymmetric reaming and use of a standard component will result in greater medialization of the joint line and use of an augmented component can minimize this effect.

RATIONALE: Currently there are no surgical guidelines to select optimal augment size for moderate to severe glenohumeral osteoarthritis. This study will identify guidelines for glenoid implant augment size based on restoration of glenohumeral biomechanics and anatomic joint line.

MATERIAL & METHODS: The pre-operative CT scans of twenty-nine patients indicated for total shoulder arthroplasty for the treatment of osteoarthritis were included in this study. Three-dimensional reconstructions of preoperative CT imaging were performed using image analysis software. For every 3D construct, solid computer models of a commercially available augmented glenoid component (DePuy Global APG and Step Tech APG Warsaw Indiana) are contained within the software and allowed for placement of each glenoid component at zero degrees with complete back side contact. For each patient, all three augments (3mm, 5mm, 7mm) were used to compensate for the posterior glenoid bone loss with the same full back side contact of the implant on the simulated reamed surface of the bone. For each case amount of medialization was measured as the linear distance from the lateral aspect of the glenoid vault model to the center of the articular implant surface when placing the best sized augmented component with full back side contact. Perforation of the glenoid wall by either the central or peripheral pegs of the glenoid implant was recorded.

RESULTS: The average pathologic retroversion of the 29 patients was $-21^{\circ} \pm 10.3$ with a range of $4.5 - 45^{\circ}$. With increasing glenoid retroversion there is an increasing difference in the amount of component medialization. The average distance of the post-operative joint line at neutral retroversion of the +3 mm augmented glenoid was 5.84 ± 3.56 mm, compared to the average distance of the post-operative joint line at 6° retroversion which was 4.76 ± 3.31 mm for the same augment size. Similarly, the average distance of the same measurement for the +5 mm augmented glenoid was 3.87 ± 3.6 mm at neutral retroversion, while it was 3.00 ± 3.18 mm at 6° retroversion. For the +7 mm augmented glenoid, the average distance of the post operative joint line was 2.31 ± 3.39 mm at neutral retroversion, and it was 1.76 ± 3.01 mm at 6° retroversion.

DISCUSSION: The technical goal for resurfacing the glenoid associated with acquired bone loss is to correct the pathologic version to its native state and to reduce eccentric loading of the prosthetic glenoid. Use of an augmented glenoid component will result in less medialization of the component, less central peg perforations, and removal of less bone for the same degree of correction than using a standard component. The results from this study provide guidelines for selection of optimal augmented glenoid size based on amount of preoperative glenoid retroversion. Selection of optimal glenoid implant size is based on restoration of joint line and prevention peg perforation to optimize implant performance and longevity.

CONCLUSION: Currently there are no surgical guidelines to select optimal augment size for moderate to severe glenohumeral osteoarthritis. This study identified guidelines for glenoid implant augment size based on restoration of glenohumeral biomechanics and anatomic joint line.

ALTERNATIVE MEDICINE: KNOW WHAT YOUR PATIENTS ARE TAKING!

Sakshi Vaishnav, Sourabh Aggarwal, Valerie Duhn, Ross Driscoll

Western Michigan University School of Medicine, Department of Internal Medicine, Kalamazoo, MI

INTRODUCTION: Generalized weakness is a highly non-specific symptom and is encountered in a number of medical and psychiatric disorders. The evaluation and differential diagnosis of weakness is often difficult and time consuming. Hypokalemia is one of the electrolyte problems that can lead to weakness. When hypokalemia is determined, underlying causes should be investigated.

CASE REPORT: A 60-year-old woman presented with complaints of generalized weakness. She was diagnosed with hypokalemia and hyponatremia of unclear etiology at an outside hospital in preceding week. She denied any other other complains. Her past medical history was significant for carcinoid tumor of the lung with metastases to liver for which she was taking an “Ayurvedic anti-cancer diet”. Her family history and social history were non-contributory. On examination, her vital signs were normal, but she appeared lethargic. She was oriented to person, place and time. The examination was otherwise unremarkable with a normal neurological examination and no focal deficits. The initial lab evaluation revealed a normal CBC. Initial electrolytes included sodium of 131 mmol/L, potassium 2.8 mmol/L, bicarbonate of 42 mmol/L and chloride of 87 mmol/L. Initial urinalysis was normal and serum creatinine was 0.9 mg/dL. She was hydrated and potassium supplements were given intravenously. However, she remained hypokalemic and it was quite resistant to correction. The following day her sodium was 135 mmol/L and potassium was 3.0 mmol/L. Urine creatinine was 24.0 mg/dL, urine osmolality was 327mOsm/kg, serum osmolality was 284 mOsm/kg, urine potassium was 49 mmol/L and urine sodium was 60 mmol/L. Her FENa was calculated to be 1.67% and transtubular potassium gradient was calculated to be around 14. Hence, she had a significant metabolic alkalosis, with resistant hypokalemia and inappropriate increased urinary excretion of potassium. She was given potassium replacements which improved her clinically with decreased weakness and lethargy. She later reported that she was taking an Ayurvedic medication “Amrit Kalash”, which is an herbal supplement, daily for the preceding 2 months. She purchased this from the Internet after consultation with an alternative medicine specialist and believed that it would be a better treatment for her carcinoid cancer than traditional allopathic regimens. It was noted that Amrit Kalash contained licorice as a primary ingredient. The patient met criteria for and was diagnosed with licorice induced hypokalemia and taken off this herbal medication. Her potassium levels improved over the course of her hospitalization. On the day of discharge, potassium was 3.4 mmol/L, chloride was 98 mmol/L and bicarbonate was 29 mmol/L.

DISCUSSION: Licorice induced hypokalemia is a rare but known condition. The active ingredient in licorice is called glycyrrhizic acid, which inhibits the 11 β -hydroxysteroid dehydrogenase enzyme responsible for conversion of cortisol to cortisone. As a result, there is over-stimulation of mineralocorticoid receptors by cortisol, causing excess mineralocorticoid production. It results in excess secretion of potassium in urine causing hypokalemia and metabolic alkalosis, as happened with our patient. Licorice induced hypokalemia has also been known to cause peripheral edema, arrhythmia and paralysis 1-5. Though the FDA regulates all non-herbal prescription and non-prescription drugs, patients still have ready access to many drugs and herbal products via internet resources. Licorice is an active ingredient of many herbal medications including Amrit kalash and Yokukansan (used for the behavioral and psychological symptoms of dementia) 6. Some studies have suggested a role for Glycyrrhizic acid in anti-viral, anti-cancer and anti-inflammatory treatments and that it may have a beneficial hepato-protective effect on immune-mediated cytotoxicity against hepatocytes, on Kaposi sarcoma-associated herpesvirus latency and anti-Helicobacter pylori activity. Consumption of licorice (glycyrrhizic acid) is difficult to control and regulate especially when it is openly marketed through resources on internet under the guise of “natural” remedies.

CONCLUSION: Clinicians should ask about alternative medicine and herbal product use and be aware that these may contain clinically significant substances, as in this case of licorice induced hypokalemia.

HYPEREOSINOPHILIC SYNDROME MIMICKING AS ACUTE CORONARY SYNDROME IN A 17 Y/O PATIENT: A CASE REPORT.

Subhankar Samal, Mary D. Moore
Western Michigan University School of Medicine, Kalamazoo, MI

INTRODUCTION: The hypereosinophilic syndrome (HES) is a rare form of disorder where persistent and marked overproduction of eosinophil ($> 1.5 \times 10^9/L$ for more than six consecutive months) is associated with eosinophil induced end organ damage. It is a leucoproliferative disorder and distinctiveness of the syndrome is eosinophil induced specific target organ damage especially the heart. Such cardiac disease is not unique to HES as cardiac damage can occur due to hypereosinophilic due to other causes. However in HES, marked eosinophilia occurs in absence of any allergic, parasitic or malignant disorders.

CASE REPORT: A 17 y/o Caucasian male with h/o Asthma and recurrent sinusitis presented to Emergency room with left shoulder and back pain for 3-4 weeks as his pain did not improve with ibuprofen and flexeril prescribed by his PCP. He was found to have marked eosinophilia with total eosinophil count of 6000, elevated CK-MB and troponin 0.18. In addition, generalized rash on his feet, hands, chest and back was found and was biopsied. EKG showed minimal ST elevation in lead V2 only. Echo-cardiogram showed trivial MR with MVP without any evidence of heart failure. He was started on prednisone with excellent response of symptoms. His skin biopsy showed superficial and deep perivascular lymphocyte and eosinophil infiltrate with evidence of fibrinoid necrosis. 6 months after his initial presentation, he was found to have eosinophilia again and was restarted on prednisone.

DISCUSSION: HES is a rare disease and true prevalence is unknown. Young to middle aged males are most commonly affected. Target-organ damage mediated by eosinophil can involve skin, heart, lungs, and central and peripheral nervous systems in more than 50% of cases. A number of HES subtypes, or variants, with distinct etiologies have recently been identified. The ability to distinguish between these HES variants along with the availability of new treatment modalities, including tyrosine kinase inhibitors and monoclonal antibodies, that target specific molecules involved in disease pathogenesis, have significantly improved the diagnosis and treatment of HES. Therapeutic management is usually directed towards disease severity, corticosteroids being the usual first line of treatment. Hydroxycarbamide, interferon-alpha, and imatinib are reserved for corticosteroid-resistant cases, as well as for corticosteroid-sparing purposes. Prognosis depends significantly on the irreversibility of heart failure as well as malignant transformation of lymphoid or myeloid cells.

CONCLUSION: Eosinophilic myocarditis can present as acute myocardial infarction in absence of other risk factors of myocardial infarction in a young patient. It should be considered in the differential diagnosis if the patient has history of asthma, allergy or peripheral eosinophilia.

THE SOUND OF MUSIC: EFFECTS ON POSTTRAUMATIC STRESS DISORDER

Sundeeep S. Randhawa, Micheal R. Liepman, David C. Dunstone, Peter L. Longstreet
Western Michigan University School of Medicine, Department of Psychiatry, Kalamazoo, MI

INTRODUCTION: Posttraumatic Stress disorder (PTSD) is an impairing condition that was first documented during the Civil War as “Irritable heart”. The lifetime incidence is estimated to be 9 to 15 percent of the general population. These individuals have experienced, witnessed, or confronted a life-threatening event and become significantly impaired in their activities of daily living. Pharmacotherapy and psychotherapy remain the mainstay treatment for PTSD, however short-term modalities also are being utilized on a case-by-case basis.

CASE REPORT: Lady R is a 54 year old Caucasian female who was seen for an initial evaluation in the outpatient psychiatry clinic. She was referred by her primary care physician and psychologist with the chief complaint of “I want to improve the noise in my head.” During the evaluation it was found that Lady R was leading a well-balanced life with her husband when suddenly things started changing after attending a court hearing 15 years ago in which her older brother was being accused of pedophilia. During this hearing, Lady R saw the testimony of the 4 year old victim who was explaining what happened along with the things she was forced to say during the encounter. Throughout the next few years, Lady R started experiencing increased anxiety, irritation, frustration, nightmares and a variable mood the source of which she was unable to pinpoint. Clonazepam 1mg and venlafaxine 37.5mg was initiated by her primary physician which helped her anxiety but sustained her depressive symptoms, initially. 2 years ago Lady R went out for a glass of wine with a friend, whom was a masseuse. It was an average night filled with conversation and laughter that culminated with Lady R receiving a cranial massage before returning home and going to bed. Upon waking, her husband approached her with caution asking if she remembered the previous night. He explained that when he tried to cuddle with her, she regressed into a fetal position and started crying-out “please don’t hurt me, please don’t hurt me” in a voice pattern similar to a young girl followed by “let her sleep, let her sleep” in a male voice when he attempted to wake her. Since this incident, Lady R experiences vivid flashbacks, avoids talking about her older brother, stopped working, became hypervigilant and has nonstop “noise” in her head as she explains it. Upon evaluation, treatment was started with supportive psychotherapy and her home medications (venlafaxine 150mg qday, bupropion 150mg BID, clonazepam 1mg qday, quetiapine 25mg qhs) were continued. After several sessions, Lady R continued to be distressed by this “noise” despite psychotherapy/medications. Listening to music had been mentioned during the sessions as an alleviating factor for Lady R, which was then encouraged. Music therapy continued to alleviate daytime symptoms and was then prescribed for Lady R as adjunctive treatment with her continued psychotherapy and medications. Since the addition of active/passive music therapy, her symptoms have decreased and Lady R continues to improve her functioning both socially and at home.

DISCUSSION: Music therapy can benefit patients suffering from mental health disorders. Active and passive listening to music that is unfamiliar to the individual can show increased symptom relief secondary to not having any linked memory to the song. Music is universal and can be utilized in any specialty for an individual experiencing a perceived stress. If music therapy is to be utilized for these individuals, does familiarity to the song have any correlation to a positive or negative response?

CONCLUSION: Posttraumatic Stress Disorder is an impairing disorder that has a variable presentation with each case and can be very difficult to treat. The initial trauma can ruminate in the victim’s mind and lead to symptoms of depression, anxiety, mania and even psychosis. Pharmacotherapy along with continued psychotherapy is the treatment of choice, but new treatment strategies (i.e. music therapy) also are being utilized with added benefit. This patient found relief in music that was familiar and unfamiliar to her, which decreased the initial “noise” and led to improved functioning on a day-to-day basis.

SECONDARY PARATHYROMATOSIS IN A PATIENT WITH NORMAL KIDNEY FUNCTION: REVIEW OF DIAGNOSTIC MODALITIES AND APPROACHES TO MANAGEMENT

Anda B. Tuncay Scorza, Andreea G. Moore, Marisa Terry, Lee A. Bricker
Western Michigan University School of Medicine, Kalamazoo, MI

INTRODUCTION: Parathyromatosis is a rare cause of elevated parathyroid hormone levels and hypercalcemia. A primary form occurs from embryonic parathyroid rest cell hyperplasia. Secondary parathyromatosis follows a parathyroidectomy. During resection, if the parathyroid gland's capsule is ruptured, freed tumor cells spill and replicate locally causing hyperparathyroidism. As is illustrated in this case, it can be difficult to treat once this seeding occurs, thus making this condition an important consideration for a surgeon. Of the 35 patients reported to date, 22 have occurred in association with chronic kidney disease. Herein we report an instance of secondary parathyromatosis in a post-parathyroidectomy patient with normal kidney function who later developed persistent hypercalcemia.

CASE REPORT: A 68 year old woman presented with primary hyperparathyroidism attributed to a left lower (confirmed) parathyroid adenoma. Levels of parathyroid hormone and serum calcium returned to baseline shortly after surgery but within 1 year nausea, abdominal pain and muscle weakness had recurred and serum calcium and parathyroid hormone (PTH) levels were again elevated. A second operation revealed multiple parathyroid implants in the prior surgical incision consistent with secondary parathyromatosis from a fractured parathyroid adenoma. Her parathyroid glands remained normal. Symptoms persisted and multiple explorations were performed with removal of more parathyroid tissue and other structures. Her PTH normalized immediately after surgery and remained so for several months, but later rose again along with her calcium. Persistent symptoms have accompanied her elevated calcium and PTH levels. The patient had bipolar disorder and was without kidney disease but with persistent osteopenia. Her family history is negative for MEN syndromes. Currently she is being treated with cinacalcet and alendronate with mild improvement in her symptoms and chemistry. Earlier she had been treated unsuccessfully with zoledronic acid, furosemide and basiliximab.

DISCUSSION: If one suspects parathyromatosis, various diagnostic modalities may be employed. Ultrasonography may help to visualize and direct resection of disseminated parathyroid tissue. Its appearance may mimic disseminated locoregional malignancy, complicating surgical planning. These areas correspond with delayed tracer uptake of Tc 99m sestamibi, the radionuclide of reference for parathyroid scanning on MIBI scintigraphy. Tc 99m sestamibi (MIBI) single-photon emission CT is used to locate hyperactive parathyroid tissue but has limitations in distinguishing various types of hyperplasia and parathyromatosis. Our patient underwent MIBI scintigraphy with removal of parathyroid tissue but the symptoms have remained. A few studies have also shown that FNA is not associated with an increased risk of parathyromatosis. Other intraoperative modalities have been explored to predict successful removal of hyper-functioning parathyroid tissue such as intraoperative PTH and calcium measurements. Studies have found that intraoperative changes do not predict success because this may only be a reflection of changes in physiology. The mainstays of treatment are calcimimetics and bisphosphonates though the literature reviews these in CKD and ESRD. Paricalcitol and ibandronate suppress PTH partially but increases in phosphate and calcium occur. Cinacalcet can be a favorable option instead of ibandronate. Calcimimetics, beyond their allosteric modulation of the calcium sensing receptor, can inhibit proliferation of parathyroid cells and upregulate the expression of calcium sensing and vitamin D receptors. This may help prevent or retard the growth of parathyroid cells and inhibit PTH secretion. Calcimimetics in high doses may also increase apoptosis of parathyroid cells.

CONCLUSION: Secondary parathyromatosis is a rare, complex condition resulting from parathyroidectomy where medical and surgical treatments have high failure rates. These patients undergo countless surgeries and often have persistent symptoms. Further research is needed to determine definitive management for these patients including those with normal kidney function as in this patient.

GENDER AND CHOICE OF MEDICAL SPECIALTY IN MEDICAL STUDENTS

Samantha Shaw, Terri A. Zachos, Shiwei Zhou, Sandra V. Sheppard, Luis Toledo, Clare Luz,
Elizabeth A Burns
MSU CHM, Kalamazoo, MI

INTRODUCTION: In 2012 48.9% of all US graduating medical students were women. Female medical students, however, tend to pursue different specialties than their male counterparts. Numerous studies have investigated this, but few definitive conclusions have been drawn.

RATIONALE: Medical student perceptions and experiences of gender disparity in different medical specialties and the effect of these experiences on career choice have not been quantitatively evaluated. The purpose of this study is to quantify gender-related pressures in the career choice of 3rd and 4th year medical students at the Michigan State University College of Human Medicine (MSU-CHM), particularly the difference between male and female students in the way they experience and respond to these pressures.

MATERIAL & METHODS: An anonymous survey was distributed to MSU-CHM students in their clinical years. The first ten questions pertained to the role gender plays in career choice. The latter part of the survey addresses considerations such as income and lifestyle. Differences between responses of male and female students were evaluated using the Mann-Whitney U test. A p-value of < 0.05 was considered statistically significant.

RESULTS: The first 20 respondents to the survey includes 15 men (75%) and 5 women (25%), with a response rate of 100% for both men and women. Thirteen out of 20 (65%) students agreed/strongly agreed that it was more socially acceptable for persons of a particular gender to enter in to certain specialties. Male and female students did not differ significantly in their response to this question ($p=0.86$). Nine out of 19 (47%) respondents agreed or strongly agreed that they have felt uncomfortable because of their gender in a clerkship or shadowing experience. Male students endorsed this item more than the female students, especially in their OB/GYN clerkship (Figure 1) ($p = 0.19$). Nine out of 20 (45%) students agreed/strongly agreed that being a member of an underrepresented gender would deter them from entering a specific specialty. Male students again endorsed this item more than their female counterparts, with a mean of 3 compared to 1.8 ($p = 0.19$).

DISCUSSION: A majority of students felt it was more socially acceptable for persons of certain genders to enter into certain specialties. However, there was no difference between the perceptions of male compared to female students. Several factors may play roles in these findings. First, this is a select population of students from a public, allopathic medical school in the Midwest. More conservative perceptions regarding gender roles may be more commonly expressed in students at our institution than those expressed by students at universities in other geographic locations. Male students especially report feeling uncomfortable during OB/GYN rotations. This is a finding that has been replicated in other studies.

CONCLUSION: In a cohort of 3rd and 4th year medical students, there was no significant disparity between genders in the perception of gender disparities between various specialties. Male students tended to experience more feelings of being out of place due to their gender, especially on the OB/GYN rotation. More male than female students report that they would be deterred from entering a specialty where they were the minority gender.

POSTER PRESENTATIONS

Rooms 1035/1045/1055

1. **Arsenic Compromises the Airway Epithelial Barrier.** Cara L. Sherwood, Andrew E. Liguori, Colin E. Olsen, R. Clark Lantz, Jefferey L. Burgess, Scott Boitano
2. **Characterization of Specter, a Zebrafish Cyclin B1 Mutant.** Amber Bard, Jyotika Singh, Laura Bakke, Rachel Warga, Donald A. Kane
3. **Generation of Two Tanapoxvirus Deletion Mutants and Their Replication in Human Cancer Cell Lines.** Yogesh R. Suryawanshi, David Jeng, Karim Essani
4. **Mapping the Microglial/Immune Response to Two Methods of Olfactory Bulb Deafferentation in Zebrafish.** Amanda K. McKenna, Christine A. Byrd-Jacobs
5. **Is a Mutation in the Homolog of CDC 20 Causing the Zombie Mutant Phenotype in Zebrafish?** Damir Musaev, Travis Dams, Emily Morgan, Rachel Warga, Donald Kane
6. **The Tanapox 15L Knockout Virus is Replicatively Attenuated in Human Endothelial Cells.** David Jeng, Karim Essani
7. **Vaccinia Virus F11L Protein Enhances Tanapoxvirus Replication and Improves its Oncolytic Potential.** Yih Wen Goh, David Jeng, Bruce Bejcek, Karim Essani
8. **Performance Assessment of Prehospital Neonatal Resuscitation Using Simulation.** Richard Lammers, Maria Willoughby-Byrwa
9. **Emergency Medical Service Crew Performance in a Simulated Pediatric Multi-Casualty Incident.** Joseph R. Michalsen, Richard Lammers, Maria Willoughby-Byrwa, William Fales
10. **Antithrombin III Deficiency with Superior Sagittal Sinus Thrombosis in Pregnancy.** Michael J. DeGrand, Philip A. Pazderka
11. **A Case of Transverse Myelitis Casued by Varicella Zoster Virus in an Immunocompetent Patient.** Neha Gupta, Kimberly C. Gygi, Carrie R. Janiski
12. **Chromosome 3p25 Deletion in a Female Infant.** Kunal Agarwal
13. **Development of a Database for the Assessment of Weight Bearing in Osteomyoplastic Reconstruction.** Casey Rathburn, Leandra Burke, Christian Ertl, Tim Darling
14. **Routine Cholangiography with Cholecystectomy: A Retrospective Review.** Lisa A. Miller, Jonathan Iglesias, Alexander Connaughton, Elbert Williams III, Leandra Burke
15. **Diplopia and Ptosis as Complications Arising from Isolated Unilateral Frontal Sinusitis.** L. Steven Szeles, Jonathan Iglesias
16. **Thyroid Broke My Heart Twice! A Case Report of Recurrent Takotsubo Cardiomyopathy.** Ravikanth Papani, Sourabh Aggarwal, Abhijit Kolla, Vishal Gupta
17. **Circulating Tumor Cells (CTC) or Carcinocythemia: A Case Report.** Ravikanth Papani, Pramod Acharya, Sreenivasa R. Chandana
18. **Cardiac Sarcoidosis: A Case Presentation.** Leah R. VanEnk, Christina G.R. Lang, Bronco Grinfield
19. **Moyamoya Disease: A Rare Cause for Stoke-Like Symptoms in an Adult.** Richa Varshney, Amy Attaway, Arvind Nehra
20. **Microscopic Polyangitis Presenting as Isolated Myopathy-A Rare Presentation.** Richa Varshney

21. **Cryptococcal Meningoencephalitis in an Immunocompetent HIV-Negative Patient.** Richa Varshney, Melissa Olken
22. **Primary Squamous Cell Carcinoma of the Colon: A Case Report & Review of Literature.** Ravikanth Papani, Chintan Pareshbhai Shah, Sreenivasa Chandana
23. **Splinter Hemorrhages Not Caused by Infectious Endocarditis, an Extreme Case of Thromboangiitis Obliterans.** Kevin Struzzieri, Devin Malik, Heidi Egloff, Mark Loehrke
24. **Jod-Basedow Phenomenon in a Patient with Graves.** Aaron C. Roberts
25. **Not Every Rise in Procalcitonin is a Bacterial Infection.** Sourabh Aggarwal, Lisa Ryan, Devin B. Malik, Mark Schauer
26. **Retroperitoneal Mass and the Diagnostic Dilemma.** Sourabh Aggarwal, John Lund, Lisa Ryan, Mark Schauer
27. **Isolated Right Ventricular Non-compaction with ST elevation in Chest Leads.** Sourabh Aggarwal, Jagadeesh Kalavakunta, Vishal Gupta
28. **Fake Pneumonia! Acute Monocytic Leukemia Presenting as Pulmonary Leukostasis: A Case Report.** Ravikanth Papani, Mark Loehrke
29. **Management of Von Gierke.** Shannon E. McCormack, Sourabh Aggarwal, Gagan Preet, Amanda Gittus
30. **Recurrent Myocardial Infarction with a Rare Anomaly; Right Coronary Artery Arising from Mid Left Anterior Descending Artery.** Kwabena O. Adu-Gyamfi, Christopher Rogers
31. **Epidemiology of Takot-Subo Cardiomyopathy in US: What Does Nationwide Inpatient Sample Data Say?** Sourabh Aggarwal, Ravikanth Papani, Vishal Gupta
32. **Mononeuritis Multiplex- An Uncommon Manifestation of this Summer's Common Infection.** Arani D. Nanavati, Shrey V. Velani, Ross E. Driscoll
33. **A Follow-Up Survey to Assess The Number of Incident/Occurrence Reports Submitted by Resident and Attending Physicians at Local Medical Facilities.** Susan F. Bannon, Mark Schauer, Sarah Polcher, Eric Yoder
34. **Evaluating Clinical Outcomes After Implementation of an Advanced Practice Provider Led Rapid Response Team.** Deb Lee-Ekblad, Susan Mastenbrook, Glenn Ekblad, Wendy Beckwith, Paul Birchmeier, Ravikanth Papani, Jeffrey L. Wilt
35. **Detective Work! Suspecting and Investigating Secondary Immune Dysfunction in Adults: A Case Report.** Ravikanth Papani, Sangeeth Dubbireddi, Thomas E. Flynn
36. **Leukocytoclastic Vasculitis Caused by Nateglinide: A Case Report.** Sourabh Aggarwal, Richard Chang, Christine Dugan, Kevin Kavanaugh
37. **Watch out! Red Flags of Chronic Back Pain in Adults: A Case Series.** Ravikanth Papani, Sourabh Aggarwal, Nicholas Demark, Sarah J. Polcher, Richard R. Roach
38. **Anaplasmosis Presenting as Meningismus in Michigan: an Unusual Presentation in an Unusual Location.** Sourabh Aggarwal, Arani Nanavati, Dustin Bivins, Susan Bannon
39. **Chronic Pain Management at an Internal Medicine Residency Clinic: Data Analysis on Patterns and Policy Adherence.** Sourabh Aggarwal, Ravikanth Papani, Shrey Velani, Susan Bannon
40. **Sarcoidosis: Diagnostic and Therapeutic Challenge.** Chintan Shah, Ravikanth Papani, Richard Roach

41. **AirTraq-Successful Use in an Air Medical Transport System.** William Selde, Kyle English, Matthew Heffelfinger, Jan Eichel, Glenn Ekblad
42. **Methamphetamine Abuse, Poor Dental Hygiene, and its Effect on Mechanically Ventilated Patients.** Sergey B. Gukasov, Ryan W. Bradstreet, Luis H. Toledo-Pereyra
43. **Interdisciplinary Health Fair and the Tendency for Young Adults to Receive Follow Up Health Care** Kaelyn M. Monroe, Abby J. Smith, Alexandra M. Scheidt
44. **Matching Osteochondritis Dissecans Lesions in Identical Twin Brothers: A Case Report.** Lucas B. Richie, Mark J. Sytsma
45. **The Effect of Carprofen on Osteogenic Differentiation of Mesenchymal Stem Cells.** Eric M. Zellner, Debbie Reynolds, Mark C. Fuller, Jeffery C. Gandy, Lorraine M. Sordillo, Terri A. Zachos
46. **The Current Quality and Content of Musculoskeletal Curriculum in US Medical Schools.** Nicole Van de Velde, Craig Smith Abby Childs, Vani Sabesan
47. **VSD Following Blunt Cardiac Trauma: MRI Findings.** Andrew E. Liguori, Benjamin A. Maertins, Randy Richardson
48. **A Survey of Simulation Fellowship Programs.** Eric Kotal, Ryan Sivertson, Scott Wolf, Richard Lammers, David Overton
49. **Interviewer Intra-Rater Reliability of Morning and Afternoon Residency Interviews.** Cara Hollmer, Tyler Johnson, Philip Pazderka, David Overton
50. **Medical Residents** Joanne K. Baker, Tracey L. Mersfelder
51. **Use of Intranasal Influenza Vaccine in Pediatric Inpatients.** Richard A. Van Enk, Aaron Lane-Davies, Neelakanta Kanike, Rushabh Shah, Mary Woodhouse
52. **Headaches in a Fifteen Year Old Female: A Case Report.** Nilam Patel, Angela Hanson, Colleen Dodich
53. **Autoimmune Hepatitis Type 2.** Danielle G. Hirsch, Angela J. Hanson, Megan E.F. Sikkema, Colette A. Gushurst
54. **Glucose Transporter Type 1 Deficiency Syndrome: History and Diagnosis in a 6-month-old Male.** Shazia Malik, Todd Anderson, Faiza Wajid, Amaan Haq, Robert Baker
55. **Hydronephrosis Caused by Sickle Cell Disease Vaso-Occlusive Crisis.** Usman Saeed, Megan Brown
56. **Cheilitis Granulomatosa.** Neelakanta Kanike, Rushabh Shah, Mary Moore
57. **Pharmacokinetics in Morbidly Obese Patients in ICU: A Case Report.** Ravikanth Papani, Sangeeth Dubbireddi, Erasmo Ruggeiro
58. **Requip for a Dream! A Case of Vivid Hallucinations Secondary to Ropinirole.** Sonia Motin, Paul D. Harcourt, Sara L. Galdys, Tracey L. Mersfelder, Lorenzo Zaffiri
59. **Factors Associated with Improvement of Depression Among Peripartum Women Under Psychiatric Care.** Katie Q. Yang, Ruqiya S. Tareen, Michael R. Liepman, Catherine L. Kothari, Remitha M. Charoth, Kathleen A. Gross, Benedict P. Dormitorio

ARSENIC COMPROMISES THE AIRWAY EPITHELIAL BARRIER

Cara L. Sherwood, Andrew E. Liguori, Colin E. Olsen, R. Clark Lantz, Jefferey L. Burgess and Scott Boitano
Western Michigan University School of Medicine, Kalamazoo, MI

INTRODUCTION: Arsenic is a lung toxicant that can lead to respiratory illness through inhalation and ingestion, although the most common exposure is through contaminated drinking water. Lung effects reported from arsenic exposure include lung cancer and obstructive lung disease, as well as reductions in lung function and immune response. As part of their role in innate immune function, airway epithelial cells provide a barrier that protects underlying tissue from inhaled particulate and pathogens found in inspired air.

RATIONALE: To determine if exposure to environmentally relevant levels of arsenic via drinking water can alter both the function and structure of airway epithelial barrier constituents. We hypothesized that arsenic increases susceptibility to lung infection in part by compromising the conducting airway epithelial barrier, a key innate immune defense mechanism in the lung, and thus contributes to respiratory disease.

MATERIAL & METHODS: (1) Mouse tracheal epithelial (MTE) cells were seeded onto semipermeable filters. Cell monolayers reached an adequate transepithelial resistance and were supplemented with or without arsenic (0, 0.8, 3.9 μM ; added as NaAsO_2) for 5 days prior to experimentation. Transepithelial resistance (TER) measurements were then calculated. (2) Immortalized human bronchiole epithelial cells (16HBE14o-) were used as a reliable in vitro model for the study of tight junction properties and grown to confluence with/without exposure to arsenic-supplemented media for 5 days. Electrophoresis was performed and proteins were transferred and blotted with primary antibodies specific for tight junction proteins of interest using GAPDH as a control. mRNA expression studies using real-time RT-PCR were performed.

RESULTS: (1) After 5-day exposure, MTE cells cultured without arsenic maintained full TER. In contrast, MTE cells cultured for 5 days with 0.8 or 3.9 μM arsenic displayed a significantly reduced TER ($P < 0.05$). (2) Immunostaining for tight junction proteins, claudins (Cl-1, Cl-4, Cl-7) and occludin, at the end of exposure showed specific changes in localization. Cl-1 and occludin staining at cell-cell contacts in the treated cultures displayed an increasing unevenness throughout the junction compared to controls. Cl-4 staining was present at cell-cell contacts in both treated and untreated cultures with an increase in cytosol punctate staining of the treated cultures. Finally, Cl-7 staining displayed consistently brighter signal with increased arsenic concentration, indicative of increased protein at cell-cell contacts. (3) Arsenic exposure resulted in three distinct patterns of protein and mRNA expression compared with controls. The first pattern, displayed by Cl-4 and Cl-7, showed increased protein and mRNA levels following arsenic exposure ($P < 0.05$). Although both mRNA levels were affected by arsenic, Cl-4 mRNA expression required 3.9 μM arsenic before significant increases were observed, whereas Cl-7 displayed a dose-dependent increase in mRNA following exposure. The second pattern, represented by Cl-5, showed increases in protein expression without significant changes in mRNA levels following exposure. A third pattern, displayed by Cl-1, Cl-3, and JAM-A, mRNA and protein expression were not significantly changed following exposure. A final pattern manifested with occludin. Similar to the previous pattern, there were no significant changes in levels of mRNA or protein expression following exposure; however, immunoblots of occludin exposed to arsenic resulted in an additional protein band due to differential phosphorylation.

DISCUSSION: Comparisons among the 5-day exposures showed a dose-dependent reduction in barrier function measured by TER. The immunocytochemical changes seen are suggestive of transmembrane tight junction rearrangements. The mRNA and protein results demonstrate that exposure alters the molecular expression, physical presence, and posttranslational modifications of select tight junction proteins in airway epithelial cells.

CONCLUSION: Epidemiological studies examining the chronic effects of low-dose arsenic exposure in humans similar to those currently in U.S. drinking water suggest arsenic toxicity near recommended maximum levels (i.e., 10-100 $\mu\text{g/L}$). The arsenic concentrations used in the study are well within those ranges and can help evaluate the potential for arsenic dysfunction on conducting airway epithelial monolayers (i.e., TER) in mouse and human cell cultures. We propose that arsenic-induced loss of barrier function reported herein represents yet another mechanism of disruption of cellular-based innate immunity.

CHARACTERIZATION OF SPECTER, A ZEBRAFISH CYCLIN B1 MUTANT

Amber Bard, Jyotika Singh, Laura Bakke, Rachel Warga, Donald A. Kane
Western Michigan University, Department of Biological Sciences, Kalamazoo, MI

INTRODUCTION: Cell cycle gene products, including cyclins and cyclin-dependent kinases, are essential proteins for the regulation and completion of mitosis. Mutations in cell cycle regulatory genes are the culprits in many types of cancer, and studies have indicated that manipulation of these genes can aid in the treatment of such cancers. Here we characterize specter (*spr*), a zebrafish mutant whose mitotic abnormalities lead to developmental arrest beginning at about 20 hours of development, when maternal reserves of mRNA expire. Mapping and sequence data reveal that a mutation is introduced in the cyclin B1 gene of *spr*.

RATIONALE: The study of zebrafish genes can cultivate a better understanding of homologous genes in related vertebrates, including humans; cell cycle genes in particular are highly conserved. The product of the cell cycle gene cyclin B1 regulates the transition from G2 to M phase, which is essential for the successful completion of the cell cycle. As such, cyclin B1 has been studied as a potential target for cancer therapy. Previous studies include the reduction of cyclin B1 protein levels as possible treatment for lung cancer, as well as the knockdown of cyclin B1 to enhance cell sensitivity to chemotherapeutic agents in the treatment of esophageal squamous cell carcinoma.

MATERIAL & METHODS: Examination and characterization of the mutation in *spr* required the use of standard molecular biology laboratory techniques, including antibody staining and in situ hybridization. Embryos were collected from zebrafish heterozygous for the *spr* mutation.

RESULTS: Phospho histone H3 antibody staining of *spr* is less than in wildtype embryos, and shows that neural stem cells do not migrate properly to the midline to divide as in WT embryos. In situ hybridization of *deltaA* at the 20-somite stage shows less expression in *spr* than in WT. The staining of nucleic acids by Sytox Green reveals nuclear fragmentation at the 15-somite stage. Widespread phosphorylated caspase-3 antibody staining occurs as early as 13 somites. We mapped the *spr* mutation to a small interval on chromosome 5 that includes the cell cycle gene cyclin B1. Sequencing of cDNA indicates that a nonsense mutation is introduced early in exon 2. Preliminary results from in situ hybridization of cyclin B1 indicate the mRNA transcripts are expressed less robustly in *spr*.

DISCUSSION: The less robust expression of phospho histone H3 antibody staining in *spr* reveals that fewer cells are entering mitosis than in WT. The fact that *deltaA*, a marker of neural precursors, is expressed less in *spr* verifies that there are fewer neural precursors in *spr* than in WT. The nuclear fragmentation evident through Sytox Green staining is related to apoptosis, and this is reinforced by the wide-scale apoptosis visualized by the phosphorylated caspase-3 antibody staining. Because sequencing indicates that the nonsense mutation is introduced very early in the cyclin B1 gene, the putative gene product is likely a null. The diminished expression of cyclin B1 mRNA in *spr* provides support that nonsense-mediated degradation is occurring in the mutant embryo.

CONCLUSION: The nervous system of *spr* seems particularly sensitive to the mitotic irregularities resulting from the mutation in cyclin B1. This may be related to the fact that the nervous system is derived from stem cells that undergo asymmetric cell division. Presently we are examining potential mitotic irregularities in other tissues that derive from asymmetric cell divisions, with the overall aim of deepening our understanding of the cell cycle.

GENERATION OF TWO TANAPOXVIRUS DELETION MUTANTS AND THEIR REPLICATION IN HUMAN CANCER CELL LINES

Yogesh R. Suryawanshi, David Jeng, Karim Essani
Western Michigan University, Kalamazoo, MI

INTRODUCTION: Tanpoxvirus (TPV) is poxvirus that causes a mild self-limiting infection in human and monkeys. Our laboratory is interested in developing a variety of TPV mutants that can potentially be used as oncolytic viruses for the treatment of various human cancers. To achieve this goal, we plan to genetically modify the virus such that it will selectively replicate in human cancer cells but not in human normal cells. In this study, we demonstrate that deleting certain genes can potentially alter the virus ability to replicate in human cancer cell lines. Host range in poxviruses is highly regulated. Most poxviruses only infect specific hosts. Ankyrin repeat genes in poxviruses are characterized by repetitive motifs and have been shown to play a role in determining cell tropism. One of the ankyrin repeat genes in TPV is T146R. A similar gene in vaccinia virus has been shown to prevent apoptosis in infected cells. Another gene, T15L in TPV has been shown to encode a protein that mimics human neuregulin. Neuregulin plays a role in embryonic cell development, acetylcholine receptor localization and epithelial morphogenesis.

OBJECTIVE: Major goal of this study is to investigate the roles of TPV genes, namely T146R and T15L in determining cell tropism. This has been achieved by generating knockout (KO) viruses (TPV-T146R and TPV-T15L) and evaluating their ability to replicate in various human tumor cell lines derived from colorectal and ovarian tissues.

METHODS: TPV-T146R and TPV-T15L were constructed by deletion of the required gene and replacing with a red fluorescent protein (mCherry). The mCherry expression cassette was driven by an early/late synthetic poxvirus promoter. The recombinant KO viruses were plaque purified by 3 viral replication cycles. Replication ability of both the recombinant viruses (TPV-T146R and TPV-T15L) and TPV-Kenya was tested in vitro by one-step growth curve in different human colorectal and ovarian cancer cell lines together with normal cell lines routinely used for TPV cultivation. The cells in monolayers were infected with 0.1 plaque forming unit (pfu) per cell. Total virus yields were determined at 240 hours post-infection by plaque assay in Owl Monkey Kidney (OMK) cell monolayers.

RESULTS: a) TPV-T146R showed approximately 2 to 10 folds higher titers as compared to the TPV-Kenya, in human fetal lung fibroblasts, human colorectal cancer cells (HCT 116 and Caco-2), and human ovarian cancer cells (SW 626). b) TPV-Kenya replicated better than TPV-T146R in Owl Monkey Kidney cells, human colorectal cancer cells (WiDr), and human ovarian cancer cells (CAOV4). c) TPV-T15L replicated similar to TPV-Kenya in most cells, with the exception of a human colorectal cancer cell (WiDr) which demonstrated a roughly 30% increase in virus yield.

DISCUSSION: Replication with high specificity in human cancer cells is an essential requirement for an oncolytic virus. To enhance the susceptibility of human cancer cells to oncolytic viruses, it is necessary to investigate the role of specific viral genes. This approach will guide our efforts towards increasing the specificity of viruses to replicate selectively in human cancer cells, and not in normal human cells. TPV-T146R has shown better replication ability as compared to TPV-Kenya in some of the human cancer cell lines used in the study. However, the replication ability of TPV-T146R in human cancer cells was poor as compared to the normal cell lines. Additionally, there are six more ankyrin repeat genes present in the TPV genome. Experiments are now in progress to evaluate the role these genes play in cell tropism.

CONCLUSION: Recombinant TPV-T146R was able to replicate in all the normal and cancer cells of human origin, which indicates that T146R a non-essential gene. TPV-Kenya and TPV-T146R replicated better in normal human cells as compared to the human cancer cells used in this study. This suggests that the TPV replicated less efficiently in human cancer cells than normal human cells. However, TPV-T146R showed better replication in human colorectal cancer cells (HCT 116 and Caco-2), and human ovarian cancer cells (SW 626) than normal human cells, as indicated by the lower yield of virus in the later.

MAPPING THE MICROGLIAL/IMMUNE RESPONSE TO TWO METHODS OF OLFACTORY BULB DEAFFERENTATION IN ZEBRAFISH

Amanda K. McKenna, Christine A. Byrd-Jacobs
Western Michigan University, Kalamazoo, Michigan

INTRODUCTION: Microglia are the immune cells of the brain. They respond to damage by phagocytizing debris. There is still ambiguity over the role of microglia in healthy and degenerating brains. The current study aims to better understand the microglial/immune system response to neurological degeneration using a model system, the zebrafish olfactory bulb. Two different methods of peripheral deafferentation were applied to the zebrafish olfactory system: permanent removal with a cautery iron and temporary ablation with infusion of the detergent Triton X-100. This allows us to better understand the immune system response at varying degenerating severities. To label microglia, we used phagocytosis-dependent labeling, where a fluorescent tracer dye is applied to the afferent axons and is ingested by the microglia as they eat the debris. Axonal labeling with an antibody was used to investigate how the microglia/immune system response correlates to the presence of existing degenerating axons. Our hypothesis was that permanent deafferentation would evoke a stronger and more aggressive immune response within the zebrafish olfactory bulb than temporary ablation.

MATERIAL & METHODS: Adult zebrafish were anesthetized with tricaine and the lipophilic fluorescent tracer DiA was applied to both olfactory organs and allowed to transport the length of the olfactory receptor cells and their axons. The fish were anesthetized again and one olfactory organ was either removed permanently with a cautery iron or ablated temporarily with 0.07% Triton X-100 detergent infusion. Fish were then perfused with fixative, dissected, embedded, and sectioned on a cryostat following survival periods of 1, 3, 5 or 7 days after the deafferentation surgery. Sections were viewed to observe the pattern of phagocytosis-mediated labeling of putative immune cells. They were also stained with anti-KLH to visualize the olfactory axons.

RESULTS: As early as 1 day following cautery treatment, a noticeable increase in irregularly shaped, labeled profiles was visible and persisted through day 7. After a single treatment with detergent, an increase in profile labeling was observed as soon as 1 day but was reduced by 3 days. Anti-KLH staining revealed an obvious loss of labeled axons in permanently deafferented zebrafish in 1 day specimens which continued to decrease until day 7 when no axonal labeling was observed. Anti-KLH labeled axons appeared to decrease in Triton X-treated specimens from 1 to 5 days post treatment. At 7 days post detergent treatment anti-KLH labeling appeared to return to near control levels. At all the time points the phagocytosis-dependent labeled profiles congregated in areas with remaining anti-KLH labeled degenerating axons.

CONCLUSION: Permanent deafferentation appeared to elicit a more aggressive microglial/immune response within the zebrafish olfactory bulb. Treatment with Triton X-100 elicited a shortened time course of the immune response and axon clearing. This is consistent with our previous finding of reinnervation occurring quickly after detergent treatment. The presumptive microglia also appeared to correlate to the anti-KLH labeled axonal debris. Putative microglia were present in the olfactory bulb of permanently deafferented specimen until all labeled axonal debris was no longer present. The microglia/immune response also appeared to congregate in areas of the degenerating axons further illustrating the correlation between the microglial/immune response and remaining degenerating axons. Our hypothesis was supported in that permanent deafferentation elicited a more aggressive, robust, and longer lasting immunological response than a single application of detergent. This study is one step in better understanding the immune response of the brain to peripheral damage and the potential role of microglia in both deafferentation and reinnervation processes.

IS A MUTATION IN THE HOMOLOG OF CDC 20 CAUSING THE ZOMBIE MUTANT PHENOTYPE IN ZEBRAFISH?

Damir Musaev, Travis Dams, Emily Morgan, Rachel Warga and Donald Kane
Western Michigan University, Kalamazoo, MI

INTRODUCTION: The cell cycle is essential for proper growth and development in organisms. Many diseases, including cancer result from defects with control of the cell cycle. Here we characterize the zebrafish recessive, lethal cell cycle mutant zombie (*zom*), whose chromosomes arrest in the metaphase-anaphase transition of mitosis.

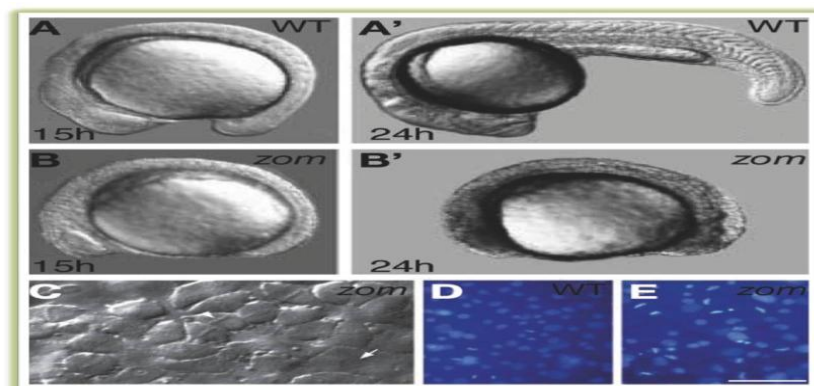
RATIONALE: CDC20 is an activator of the Anaphase Promoting Complex, which helps chromosomes separate during the metaphase-anaphase transition. In support of this, a mutation in the CDC20 homolog in the *Drosophila m.* also causes arrested mitosis. The mutation in this gene is the most possible explanation for *zom* phenotype.

MATERIAL & METHODS: *Zom* was mapped to a small interval in chromosome 2 using z-markers upstream and downstream of CDC20. In addition to this, mutated and wild type CDC20 was isolated and sent off for sequencing. Antisense splice blocking oligonucleotides were used to knock down CDC20 gene function in an attempt to recapitulate the mutant phenotype. In-situ analysis was done to compare the expression of CDC 20 gene between mutants and wild type. Currently, we are using CDC20 mRNA to attempt rescue of the mutant phenotype.

RESULTS: Mapping data indicated on CDC20 gene as a locus of possible mutation. Sequencing data showed that a transversion occurred in exon 7 of the CDC20 gene producing a nonsense mutation. However, we are yet unable to reproduce the mutant phenotype using antisense splice blocking oligonucleotides. In situ analysis shows there are fewer CDC20 transcripts in the mutant.

DISCUSSION: Mapping data strongly supported our predictions along with sequencing results. Maternal wild type mRNA is being used in mutants and as a result of nonsense mutation the amount of the transcribed gene should be depleted. In situ with CDC20 mRNA result is indicating to a nonsense-mediated degradation of mRNA, a common feature of premature termination. The reason why we were unable to get expected results using antisense splice blocking oligonucleotides is perhaps because the resulting mRNA product is only altered by 3 nucleotides.

CONCLUSION: Identifying the gene mutated in *zom* will enable us to better understand control of the cell cycle. Also the knowledge generated as a result of this discovery has a high potential to be used in a treatment of diseases involving abnormal cell division cycle.



THE TANAPOX 15L KNOCKOUT VIRUS IS REPLICATIVELY ATTENUATED IN HUMAN ENDOTHELIAL CELLS

David Jeng, Karim Essani

Western Michigan University, Department of Biological Sciences, Kalamazoo, MI

OBJECTIVE: Oncolytic poxviruses, such as vaccinia virus, has been moderately successful in clinical trials. To avoid normal cell destruction, the vaccinia thymidine kinase and the EGF-like growth factor genes have been ablated, showing safety in preclinical models. However, the immunity generated towards the virus is both robust and life-long, necessitating additional species for oncolytic poxvirus development. One potential candidate is the tanapoxvirus (TPV), which presents a mild, self-limiting disease that infects humans and monkeys without immune cross-reactivity with vaccinia. We have previously reported that the TPV derived, EGF-like growth factor (TPV-15L) is a viral mimetic to human neuregulin (hNRG) with the ability to phosphorylate neuregulin receptors (ErbB2 and ErbB3 heterodimer). Neuregulins represent a large family of EGF-like growth factors that play important roles in embryonic endocardium development, Schwann and oligodendrocyte survival and differentiation, localized acetylcholine receptor expression at the neuromuscular junction and epithelial morphogenesis. Furthermore, certain neuregulins target specific tissues through interactions with heparin sulfate proteoglycans via an immunoglobulin (Ig)-like domain. Analyses on TPV-15L revealed no Ig-like domain, but retains the ability to bind heparin while phosphorylating neuregulin receptors, providing evidence that TPV-15L is a viral mimetic of neuregulin. However, the precise role of this protein in host-virus interaction remains to be deduced. Therefore, our objective is to assess whether or not TPV-15L plays any role in virus replication for the purpose of understanding the potential safety of an oncolytic TPV. A mutant TPV-15L knockout virus (TPV-15L^Δ) was generated and demonstrated attenuation in human umbilical vein endothelial cells (HUVEC) which possess hNRG receptors when compared to wild-type TPV (wtTPV).

METHODS: (1) Using homologous recombination, the TPV-15L^Δ knockout virus was generated using a plasmid (pBSII-KS+) that included stretches of genomic TPV DNA flanking both sides of the TPV 15L ORF. In between the flanking sequences, a synthetic early/late poxvirus promoter was used to drive the expression of mCherry (Clontech) reporter. This plasmid was transfected following manufacturer's protocol (Superfect, Qiagen) into 60mm tissue culture dishes containing owl monkey kidney cells (OMK) infected with TPV. After 8 days, the virus was harvested, plaque purified three times and confirmed through PCR amplification of a stretch of DNA unique to TPV-15L. (2) The isolated TPV-15L^Δ was amplified in OMK cells and concentrated to 100x using ultracentrifugation and resultant virus titered on OMK cells. HUVEC were plated at a density of 5x10⁴ cells/well in a 24 well dish. The cells were infected with TPV-15L^Δ and wtTPV at 0.1 plaque forming units/cell (MOI) and 5 MOI. After infection, the cells received 1 ml of HUVEC growth medium and were incubated for 48, and 96 hours. After their respective incubation, infected cells were harvested, lysed with deionized water and three freeze/thaw cycles. The infected cell lysate was pooled with infected supernatant and serially diluted for virus titration in OMK cell monolayers.

RESULTS: (1) The generation of TPV-15L^Δ which displays similar plaque size and replication kinetics to that of wtTPV suggests that TPV-15L is non-essential for virus replication. (2) The TPV-15L^Δ knockout virus displays attenuation in HUVEC possessing hNRG receptors.

CONCLUSIONS: This study provides compelling evidence that TPV has evolved a cytokine mimetic that is capable of phosphorylating the hNRG receptors and bind heparin, but also plays a role in virus replication. The TPV-15L^Δ knockout virus demonstrates no observable replication defects in OMK cells, but demonstrates attenuation in HUVEC cells possessing ErbB receptors. These results provide important information for the future development of an oncolytic TPV.

VACCINIA VIRUS F11L PROTEIN ENHANCES TANAPOXVIRUS REPLICATION AND IMPROVES ITS ONCOLYTIC POTENTIAL

Yih Wen Goh, David Jeng, Bruce Bejcek, Karim Essani

Western Michigan University, Department of Biological Sciences, Kalamazoo, MI

OBJECTIVE: Tanapoxvirus (TPV), a member of the genus Yatapoxvirus, is being investigated for its potential as a form of oncolytic virotherapy. It was previously shown that TPV replicates unlike other poxviruses in that it has a longer replication cycle and significantly lower yield of mature virions compared to vaccinia virus (VACV). The long replication cycle of TPV has been a major hurdle in progressing towards the experimental use of TPV as an oncolytic virus. To increase the virus productivity, we decided to manipulate the host cells to hasten TPV replication without altering the virus itself. VACV F11L protein has the ability to inhibit RhoA-mDia signaling, which has been shown to alter the overall effects in releasing poxviruses from infected cells. Hence, we postulated that inserting VACV F11L gene in host cells would greatly increase TPV yield, while improving TPV replication kinetics. To accomplish this, we generated several stably transfected Owl Monkey Kidney (OMK) cell lines expressing VACV F11L that notably increases the virus plaque size.

METHODS: (1) OMK (ATCC) cells were grown in DMEM containing 10% v/v fetal bovine serum, 2mM L-glutamine and antibiotic. (2) OMK-F11L cell line was generated using a plasmid (pcDNA3.1/myc-His A) that has F11L ligated into the multiple cloning sites at the end of the T7 promoter region. This plasmid was transfected into OMK cell monolayers following manufacturer's protocol (jetPRIME, Polyplus-transfection, Illkirch, France). After 48 hours, the transfected monolayer was supplemented with 0.8 microgram/ml geneticin for selection. Media supplemented with geneticin was replaced every 2-3 days for over a month. (3) Stably transfected OMK-F11L cell colonies were isolated and cultivated in DMEM containing 10% v/v fetal bovine serum, 2mM L-glutamine and antibiotic. (4) Plaque size experiments were performed by infecting 6 well-plates with 0.1 plaque forming units/cell of TPV, containing 4 individual OMK-F11L colonies (OMK-F11L1, 2, 3, 5 and pcDNA3.1). Infected cell monolayers were overlaid with growth medium containing 0.5% methylcellulose and were incubated for 5 days before staining with plaque staining solution. The diameters of 10 plaques from each cell line were measured and average calculated.

RESULTS: (1) Average size of the plaques isolated from cell lines expressing VACV F11L (OMK-F11L1, 2, 3 and 5) was 1.22 mm, 1.07mm, 1.16 mm and 1.20 mm respectively. Concomitantly, the average size of the plaques isolated from control cell line not expressing VACV F11L and transfected with pcDNA3.1 (OMK-pcDNA) was 0.57 mm. The average increase in plaque size in every case nearly doubled. (2) Stably transfected OMK-F11L produced countable plaques approximately 3 days faster (5 days post-infection) compared to regular OMK cells (8-10 days post-infection).

CONCLUSION: The results indicate that in micro-environments containing vaccinia virus F11L protein, TPV is able to generate plaques twice the size of normal OMK cells in culture. This will contribute to the understanding of TPV replication and greatly assist the efforts of generating an oncolytic TPV for treating human cancers. Further investigations are currently underway to assess whether the plaque size increase translates to a higher yield of mature virions.

PERFORMANCE ASSESSMENT OF PREHOSPITAL NEONATAL RESUSCITATION USING SIMULATION

Richard Lammers, MD, Maria Willoughby-Byrwa, BS, EMT-P, I/C
Western Michigan University School of Medicine, Kalamazoo, MI

INTRODUCTION: Prehospital neonatal resuscitation is a rare occurrence, which makes skill assessment of prehospital care providers challenging.

RATIONALE: The objective of this observational study was to identify performance gaps in crews of prehospital care providers during a simulated precipitous delivery and neonatal resuscitation.

MATERIAL & METHODS: Two-person EMS crews from five, geographically diverse agencies participated in a 20-minute simulation of a precipitous delivery followed by newborn cardiopulmonary arrest. Crews used their own equipment and drugs in a simulation trailer designed to resemble a house and the interior of an ambulance. A scoring protocol that was reviewed and modified by an expert advisory panel was used to identify performance gaps. Performance gaps were reported using descriptive statistics.

RESULTS: Eighty-eight EMS providers participated in 40 simulated exercises over a three month period. The most common and clinically significant performance gaps were identified in three categories: delivery skills, neonatal assessment, and neonatal resuscitation. (See Table 1.)

DISCUSSION: This study identified gaps in some area of performance and other tasks that were executed skillfully by EMS crews. The majority of EMS crews assessed heart rate, respiratory effort, reflex irritability, muscle tone, and skin color, but few calculated an Apgar score. Some performed assessments but did not correctly interpret the findings. Paramedics struggle with pediatric drug dosing for a variety of emergent conditions, including the use of epinephrine during neonatal resuscitation. Several recommendations for avoiding future errors were sent to participating EMS agencies.

CONCLUSION: Simulation identified skill performance gaps in the prehospital management of precipitous delivery, newborn assessment, and neonatal resuscitation. This information can be used by EMS instructors to provide targeted educational activities.

Table 1: Selected Task Completion Rates

Delivery	
Instruct mother to stop pushing once head is delivered.	6/40 (15%)
Dry the newborn.	29/40 (73%)
Dry the newborn within 30 seconds.	22/40 (55%)
Assessment	
Recognize bradycardia (80 bpm).	27/40 (68%)
Identify slow respirations (20/min).	35/40 (88%)
Check muscle tone.	30/40 (75%)
Identify decreased muscle tone.	27/40 (68%)
Check for reflex irritability.	25/40 (63%)
Identify grimace response.	28/40 (70%)
Identify central cyanosis.	40/40 (100%)
Verbalize one-minute Apgar score.	10/40 (25%)
Correctly calculate one-minute Apgar score (4).	1/40 (3%)
Verbalize five-minute Apgar score.	2/40 (5%)
Correctly calculate five-minute Apgar score (9).	1/40 (3%)
Resuscitation	
Deliver ventilations for 30 seconds.	32/40 (80%)
Check heart rate (40/min) and respiratory rate (apnea) after 30 seconds of ventilations.	29/40 (73%)
Ventilate at a rate of 30/minute.	30/40 (75%)
Perform chest compressions at a rate of 100-120/minute.	36/40 (90%)
Don't interrupt chest compressions for > 30 seconds.	31/40 (78%)
Performed endotracheal intubation.	18/40 (45%)
If intubated, inserted ET tube to proper depth (9-11 cm).	13/18 (7%)
If intubated, auscultated chest after intubation.	11/18 (6%)
Establish introsseous or umbilical vein access.	
Intraosseous	23/40 (58%)
Umbilical vein	13/40 (33%)
Draw epinephrine into a smaller, 1 mL syringe.	4/40 (10%)
Deliver epinephrine.	27/40 (68%)
If epinephrine given, deliver correct dose.	14/27 (52%)

EMERGENCY MEDICAL SERVICE CREW PERFORMANCE IN A SIMULATED PEDIATRIC MULTI-CASUALTY INCIDENT

Joseph R. Michalsen, Richard Lammers, Maria Willoughby-Byrwa, William Fales
Western Michigan University School of Medicine, Emergency Medicine, Kalamazoo, MI

INTRODUCTION: Systematic evaluation of pre-hospital provider performance during pediatric multi-casualty incidents (MCI) is difficult.

OBJECTIVE: The objective of this study was to identify errors and exemplary performance during a simulated pediatric MCI.

METHODS: Institutional Review Board approval was obtained for this study. Four-person emergency medical service (EMS) crews from 5 demographically diverse agencies participated in a simulation of a pediatric MCI involving 4 patients of varying acuities. Various realistic, pediatric simulators were used to depict the patients. Crews were “dispatched” in 2-person EMS units to a simulated scene involving multiple damaged structures with entrapped patients following a tornado. The scene was outside of their usual service area. Upon arrival participants were briefed and directed to establish a forward triage area in a provided tent using their own equipment, supplies, and medications. Their assigned objective was to treat and stabilize patients as they were rescued from the rubble until additional transporting EMS units arrived. Crews were staffed by 2 to 4 paramedics. Patients arrived sequentially over 25 minutes at fixed time intervals that were intended to increase situational stress. Patient #1 (Pt1) was a 6-year-old with a closed femur fracture who gradually deteriorated. Patient #2 (Pt2) was a 5-year-old with a severe traumatic brain injury, a fixed and dilated pupil from cerebral herniation, and a subsequent 3-minute seizure. Patient #3 (Pt3) was an infant in a non-survivable cardiac arrest. Patient #4 (Pt4) was an 8-year-old with a closed humerus fracture. Both Pt1 and Pt4 had obviously painful conditions. All activities were digitally recorded (audio and video), allowing for post-simulation scoring. An advisory panel derived a scoring protocol consisting of 91 expected actions to measure performance. All simulations were scored by a single investigator (MB). We used surveys to obtain demographic information; participants assessed realism, challenge, and stress on 5-point Likert scales. All data were analyzed using descriptive statistics.

RESULTS: Twenty-five crews completed the study. Eighty-eight percent of participants were licensed at the paramedic level; 87% were male. The average number of years of experience was 9.6 +8.4 (range <1-35). Crews completed an average of 67% +5.5% of the 91 expected actions (range 55-75%). A cervical collar was applied by 72% of crews to Pt1, 52% to Pt2, and 20% to Pt4. Only 8% of crews provided analgesia to Pt1, and none provided analgesia to Pt4. Eighty-four percent of crews identified hemodynamic deterioration in Patient #1; interventions included oxygen (67%), a fluid bolus (76%), or both (57%). Only 16% of crews administered a benzodiazepine to Pt2 for the seizure. Incorrect triage decisions included: failure to select Pt1 first for transport (84%); continuation of CPR on Pt3 (96%); and selecting Pt3 first for transport (84%). The mean duration of CPR was 124 +111 (range 9-360) seconds. All crews eventually terminated CPR. Participants found the simulation to be realistic (median = 4; IQR 4-5), challenging (median = 4; IQR 4-5), and stressful (median = 4; IQR 3-4).

CONCLUSIONS: Simulation using current patient simulation technology combined with audiovisual recording and scoring metrics is a useful tool to assess the performance of pre-hospital providers in a multi-casualty incident. Immobilization, medication and triage errors were identified.

ANTITHROMBIN III DEFICIENCY WITH SUPERIOR SAGITTAL SINUS THROMBOSIS IN PREGNANCY

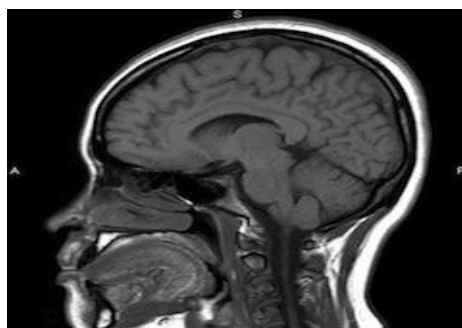
Michael J. DeGrand MD, Philip A. Pazderka MD
Western Michigan University School of Medicine, Kalamazoo, MI

INTRODUCTION: Antithrombin III is a serum protein produced in liver and endothelial cells that inactivates thrombin and other serine proteases to promote an anti-coagulant state. This is accomplished by inactivation of several clotting factors including thrombin and factors IXa, Xa, XIa and XIIa. Deficiency occurs in 1 of 5000 healthy blood donors. Patients with antithrombin III deficiency inherit the disease in an autosomal dominant manner and are divided into two subtypes. Patients with type I deficiency have normal plasma levels of antithrombin, but the protein has reduced biological activity or is dysfunctional. Type 2 deficient patients have decreased plasma levels of fully functional antithrombin. Normal concentration of the protein is 150 micrograms/ml with thrombosis occurring with levels dropping to 75% of this amount.

CASE REPORT: The patient is a 29-year-old (G-2 P-0-0-2-0) at 11 weeks gestation by dates with a past medical history of antithrombin III deficiency diagnosed after suffering a lower extremity DVT that was followed by a subsequent miscarriage. She presented to the Emergency Department with a one-week history of frontal headaches, which were constant in nature and non-radiating. She denied any associated visual disturbances, photophobia or phonophobia. She described having some left upper extremity weakness and numbness, which was typically more pronounced on waking in the morning. She stated this tended to resolve throughout the day but had not gotten back to her baseline. She denied any lower extremity or right-sided symptoms, any difficulties with mentation, speech or swallowing.

DISCUSSION: Treatment of acute thrombosis is with low-molecular-weight heparin because antithrombin deficiency may cause resistance to unfractionated heparin. Resistance to unfractionated heparin may be an initial clue to the presence of deficiency. Prophylactic treatment of asymptomatic individuals is considered controversial and tends to be limited to high-risk situations such as pregnancy or surgery. Several changes in the hemostatic system during pregnancy necessitate this treatment including increased platelet number and adhesiveness and elevations in clotting factors VII, IX and fibrinogen. In the pregnant patient, long-term treatment is with unfractionated heparin as warfarin is associated with multiple birth defects including skeletal abnormalities and bleeding complications in the fetus as the medication passes through the placental barrier. Anti-coagulation therapy is continued throughout the course of the pregnancy with reversal occurring at the time of delivery. Following delivery, however, therapy is reinstated for the duration of the puerperal period. Several studies and case reports have an increased risk of ischemic stroke during this period. Several factors have been implicated in this including the large decrease in blood volume and rapid changes in hormonal status that follow delivery. Studies have shown that alterations in estrogen level can interfere with the return of normal antithrombin III activities during the puerperium. This would be of particular concern in the type II deficient patient with decreased levels of functional protein at base line.

CONCLUSION: For our patient, lovenox was started after MRA recognition of the intracranial thrombosis and consultation with neurology and OB/GYN services. She was subsequently admitted for the initiation of her anti-coagulation therapy and discharged two days later when therapeutic levels were attained. On discharge, she was instructed to continue to follow up with OB/GYN and neurology for subsequent monitoring.



A CASE OF TRANSVERSE MYELITIS CAUSED BY VARICELLA ZOSTER VIRUS IN AN IMMUNOCOMPETENT PATIENT

Neha Gupta, Kimberly C. Gygi, Carrie R. Janiski

Western Michigan University School of Medicine, Family Practice, Kalamazoo, MI

INTRODUCTION: Transverse myelitis(TM) is a rare focal inflammatory disorder involving the spinal cord. Symptoms include loss of motor and sensory function that corresponds to the level of the spinal cord at which the inflammatory lesion occurs; as well as autonomic dysfunction. Transverse Myelitis has been linked to viral diseases, vaccinations, mixed connective tissue disorders, vasculitis, multiple sclerosis, IV drug use and trauma. 20-40% of cases of TM are due to viral etiologies, with 0.3% of cases secondary to Varicella Zoster Virus(VZV) infection. Timely diagnosis is important in order to initiate medical and physical therapy, leading to improved prognosis. The following is a case of Transverse Myelitis caused by Varicella Zoster Virus.

CASE REPORT: We report the case of a 69 year old male presenting to the emergency department with a ten hour history of increasing weakness in his legs as well as a new painful rash on the left side of his abdomen. The weakness occurred after his daily two-mile walk. A detailed history revealed an otherwise negative review of systems, no significant exposure or injury, and a history of hypertension and pulmonary embolism. Physical exam revealed normal strength sensation and reflexes in all extremities. The patient was able to stand and walk on his own with minimal difficulty. The left flank rash was blanching, bruise-like in appearance, dermatomal in distribution, and without vesicles. Initial laboratory data revealed an elevated creatine kinase(626 U/L) and an elevated lactic acid (3.6 MMOL/L). CBC, CMP, CRP, ESR, PT/INR were all within normal limits. On day two of the hospital stay the patient developed increasing weakness, parathesias of the left foot and toes, and urinary retention. At this time he was unable to support his own weight or walk on his own. Neurology and dermatology consultants reviewed the case. An MRI of the lumbar spine was obtained which showed enhancement of the conus medullaris extending from T12 to L1-L2 level. These findings, along with EMG, suggested Transverse Myelitis. The finding of the rash was further suggestive of a viral etiology, likely varicella zoster virus. Continued testing included normal B12, Folate, methylmalonic acid and angiotensin converting enzyme, along with negative B. burgdorfi antibodies, as well as viral, bacterial, and fungal cultures of cerebrospinal fluid, along with Epstein-Barr virus, Herpes Simplex Virus, Varicella Zoster, Lyme antibodies, Enterovirus, and VDRL. Based on clinical symptoms therapy was initiated with IV acyclovir along with a five-day course of one gram IV solumedrol daily per the consultants' recommendations. Upon conclusion of treatment, the patient's care was transferred to rehabilitation services at Mary Free Bed Hospital. The patient is currently doing well, has greatly regained sensation, and is ambulating with minimal assistance from a cane.

DISCUSSION: This patient's presentation was atypical in a number of ways. Firstly, Transverse Myelitis secondary to VZV is uncommon in immunocompetent individuals. Also, median time from rash to myelopathic symptoms is 12 days, while our patient became symptomatic almost simultaneously with appearance of the rash. Lastly, our patient's serologic and CSF analysis did not show a VZV source for his symptoms. However literature review revealed that PCR for VZV can be falsely negative when the sample is taken 1-2 days after the onset of symptoms as was the case with this patient's testing.

CONCLUSION: In this case, transverse myelitis was likely secondary to varicella zoster virus, and was treated as such. Diagnosis and treatment of TM are important because early recognition and management may alleviate the severity of future neurologic complications.

CHROMOSOME 3P25 DELETION IN A FEMALE INFANT (CASE REPORT)

Kunal Agarwal

Western Michigan University School of Medicine, Kalamazoo, MI

INTRODUCTION: A 3p25 deletion is a very rare chromosome disorder, with around 40 cases reported in the literature. Frequent features include low birth weight, microcephaly, developmental delay, vision and hearing impairments, polydactyly, congenital heart defects, seizures, and learning disability among others. We present another female infant diagnosed with this chromosome deletion.

CASE REPORT: The 10 month old African American female patient was the second child of non-consanguineous parents, born after a fairly uneventful pregnancy via emergency cesarean section due to breech position and oligohydramnios at 37 weeks gestation. Birth weight was 4 pounds 10 ounces (<3rd percentile), birth length was 20 inches (50-75th percentile). The mother reported head circumference was small. During the neonatal period, the patient presented with bilateral preauricular pits, wide spaced eyes, depressed nasal bridge, low set ears, bilateral postaxial polydactyly of the fingers, sacral dimple and a large umbilical hernia. The polydactyly was treated by tying off the excess digits. The patient's 2D echocardiogram revealed a patent foramen ovale and trivial patent ductus arteriosus but otherwise normal exam. The renal, hepatic, and spinal ultrasounds were normal. The patient did have hyperbilirubinemia, which did resolve. The patient has bilateral foot inversion and right shoulder blade protrusion. Per the mother, the patient has poor vision but passed her newborn vision exam. She also reported that she is chronically congested and has dry skin. A chromosome analysis revealed an abnormal female karyotype of 46, XX, del (3) (p25). A chromosomal microarray revealed 3pter-p25.1 (48,914-12, 697, 982)x1 [hg18]. The deletion is approximately 12.6 megabases and contains 74 genes including the ITPR1 and VHL genes.

DISCUSSION: 3p25 deletion is a very rare chromosome disorder that is likely caused by a de novo event in the egg, sperm or embryo or is the result of a chromosome translocation due to one of the parents being a carrier. The first signs of the disorder usually include developmental delay and dysmorphic features and diagnosis can be made with chromosome analysis, including FISH, and or amniocentesis. Affected children typically have multiple dysmorphic features such as extra fingers and toes, upper eyelids that do not open fully, widely spaced eyes, small chins, low and oddly shaped ears, a thin upper lip that may turn down at the corners, broad nasal bridge, long philtrum, epicanthal folds, micrognathia, hypertelorism, trigonocephaly, synophrys, cleft palate, flat occiput, narrow forehead, upslanting palpebral fissures, bushy eyebrows that may join in the middle, and preauricular pits among others. Children often have learning disabilities, speech and growth delay, and feeding difficulties. Around 1/3 of infants are born with a congenital heart defect with the most common being an atrioventricular septal defect, in addition to them experiencing seizures, having temporary or permanent hearing loss, and vision loss that may include abnormalities of the vitreous body, optic atrophy, and strabismus. Given our patient's deletion includes the VHL gene associated with von Hippel Lindau syndrome located at 3p25.3, she may develop features associated with VHL including retinal and CNS hemangioblastomas and renal cell cancer. Screening involves regular neurological assessments, retinal exams for angiomas, periodic MRI scans of the brain once puberty is reached, and annual abdominal ultrasounds after age 16.

CONCLUSION: A 3p25 deletion is a very rare chromosome disorder typically caused by a de novo event, diagnosed by chromosome analysis, and characterized by low birth weight, developmental delay, dysmorphic features, and congenital heart defects among others. Screening involves annual evaluations for hearing, vision, neurology, growth, and development. Patients do have a good prognosis.

DEVELOPMENT OF A DATABASE FOR THE ASSESSMENT OF WEIGHT BEARING IN OSTEOMYOPLASTIC RECONSTRUCTION

Casey Rathburn, Leandra Burke, Christian Ertl, and Tim Darling

Western Michigan University School of Medicine, Department of Surgery, Kalamazoo, MI

INTRODUCTION: Throughout history, countless advances have occurred in amputation surgery. Dr. Janos Ertl (1880-1951) developed the Ertl osteomyoplastic reconstruction in effort to find a suitable way to give WWI veterans a functioning extremity following limb loss. Dr. Christian Ertl currently performs this technique in the Kalamazoo community for primary amputations as well as reconstruction of amputated limbs. Literature exists confirming that prosthetic use improves patients' functional ability and psychiatric outlook, and central to the success of the Ertl amputation is the ability of the patient to use a prosthesis. This ability is evaluated by load-bearing capabilities and gait. Although there is perceived data of end-bearing capabilities and gait based on clinical observation, there is not a lot of support from objectively measured data.

RATIONALE: Creating a database containing pressure mapping from trans-tibial osteomyoplastic reconstruction patients' provides data that will yield objective information on whether reconstruction correlates to a decrease in the measured load of the unaffected limb, and an increase in the measured load of the amputated extremity.

MATERIAL & METHODS: Data will be collected from information obtained during the course of care of transtibial osteomyoplastic reconstruction patients, prior to surgery, and at 3, 6, 9, and 12 months post-operatively. The pressure-monitoring device used was Zebra, by Sensortech Corporation (Greenville, SC), which works by measuring electricity and resistance changes via plastic conductors at select anatomic locations of the amputated extremity, and a shoe sole sensor in the unaffected limb. This system offers a means of obtaining objective, quantitative data of the load-bearing capabilities of osteomyoplastic amputee patients.

RESULTS: Nineteen patients were measured between July 2012 and January 2013. Of the nineteen participants, only two have measurements prior to surgery and 3 months post-operatively. Of the two patients, one objectively shows improvement with respect to load-bearing capabilities with use of a prosthetic.

DISCUSSION: This research currently lacks the appropriate number of subjects to conclude with any certainty that the Ertl reconstruction is of any real benefit. There is evidence of one patient who has increased their ability to ambulate more efficiently. And, although the other patient has not yet shown signs of improvement, the data can be used for improving treatment. In this case, we are working to alter the fit of the prosthetic.

CONCLUSION: At this time is not enough information to draw conclusions for the research. However, there are indications of patients' improvement after going through the reconstructive surgery. Until there is sufficient data, this measuring technique can offer care providers with objective information to improve individual patients' situations.

ROUTINE CHOLANGIOGRAPHY WITH CHOLECYSTECTOMY: A RETROSPECTIVE REVIEW

Lisa A. Miller, Jonathan Iglesias, Alexander Connaughton, Elbert Williams III, Leandra Burke
Western Michigan University School of Medicine, Department of Surgery, Kalamazoo, MI

INTRODUCTION: Laparoscopic cholecystectomy has largely replaced open cholecystectomy as the procedure of choice for the treatment of gallbladder pathology. Despite the dramatic increase in minimally invasive surgery, a significant number of cases are still converted to the classic open procedure. It is believed that biliary imaging has value in predicting the rate of intra-operative conversion.

RATIONALE: This study aims to review and compare the rates of post-operative complications and operating room time in cholecystectomy patients who received an intra-operative cholangiogram (IOC) versus those who do not receive IOC, in a community hospital setting. At this time, we will utilize a convenience sample of approximately 50 patients per group (IOC or no IOC), and use the results of statistical analysis to determine the sample size needed for a larger, more comprehensive study in the future.

MATERIAL & METHODS: The study team retrospectively reviewed a convenience sample of 103 charts of patients who had undergone either open or laparoscopic cholecystectomy, with or without an intra-operative cholangiogram.

RESULTS: In our sample, regardless of laparoscopic or open surgical approach, 59 patients received an IOC, and 44 patients did not receive an IOC. Of the patients receiving IOC, only 2 returned with post-operative complications. Meanwhile, of the group not receiving an IOC, only 2 patients returned with post-operative complications as well. In the IOC group, 13 out of 59 cases were converted to open cholecystectomy, while 7 out of 44 cases were completed as open procedures in the non-IOC group. The average operating time for laparoscopic cholecystectomy with IOC was 101.94 minutes (SD=37), compared to the average time for a laparoscopic cholecystectomy without IOC at 68.89 min (SD = 25.5). This time increase to complete an IOC was significantly longer in our sample (P=0.0002). There was not a large enough sample to calculate this time for patients receiving an open cholecystectomy.

DISCUSSION: Many surgeons champion the routine use of cholangiography sighting a reduction in common bile duct (CBD) injury, decreased patient morbidity associated with retained calculus and additional post-operative procedures, as well as cost-effectiveness. These benefits are thought to outweigh the inherent risks of imaging the biliary tree. In our sample, we found that conducting an intra-operative cholangiogram adds significant OR time to laparoscopic cholecystectomies. Our sample size was not large enough to detect a true difference in the rates of cholecystectomies that are converted from a laparoscopic to open approach. Also of note, the same number of patients (n=2) experienced post-operative complications in both the IOC as well as the non-IOC group.

CONCLUSION: IOC added significant intra-operative time to laparoscopic cholecystectomies in our sample.

DIPLOPIA AND PTOSIS AS COMPLICATIONS ARISING FROM ISOLATED UNILATERAL FRONTAL SINUSITIS

L. Steven Szeles and Jonathan Iglesias

Western Michigan University School of Medicine, Department of Surgery, Kalamazoo, MI

INTRODUCTION: Chronic sinusitis is an inflammatory condition involving the mucosal lining of the paranasal sinuses, which persists for a minimum of 12 weeks despite attempts at medical management. Multiple sinuses are usually involved and symptoms tend to be diffuse and rather vague, such as congestion, rhinorrhea, and headache. Less commonly, a single sinus is involved, and symptoms tend to be more localized and specific, but still centering on the involved sinus. Complications of sinusitis usually relate to involvement of the orbit or CNS and the presentation is usually dependent on the virulence of the organism involved. Complications of bacterial origin are typically acute and severe, such as: pre-orbital/orbital cellulitis, meningitis, and abscess formation. Complications due to less virulent organisms, in contrast, tend to have a slow more insidious onset and are generally less severe in presentation.

CASE REPORT: We present an atypical case of isolated chronic left frontal sinusitis caused by *Staphylococcus aureus* presenting with a four month history of slowly progressive lid lag and diplopia, secondary to erosion through the floor of the sinus. Multi-faceted surgical debridement of the affected sinus using both external and endoscopic approaches was used. The patient was then started on a six week course of minocycline. Two months post-operatively, the patient's presenting symptoms of lid lag and double vision has dramatically improved.

DISCUSSION: Isolated unilateral chronic frontal sinusitis is a relatively uncommon entity. Most cases of unilateral chronic frontal sinusitis are found in the setting of chronic ethmoid and maxillary disease. The microbiology can be similar to that of bilateral disease, but when a single sinus is involved, fungal and less virulent bacterial infections become the likely candidates. When dealing with indolent isolated unilateral sinus disease neoplastic processes need also be considered. Common symptoms of chronic sinusitis include nasal congestion, chronic rhinitis, dysosmia, and facial pressure. Complications from chronic sinusitis typically result from an acute bacterial supra-infection, and manifest as acute fulminate symptoms involving the central nervous system and/or orbit. Periorbital diseases resulting in symptoms such as diplopia and lid ptosis, as seen in our patient, are commonly the result of aggressive infectious processes such as preseptal cellulitis and orbital abscesses; which are well known causes of rapidly progressing periorbital disease. The present case demonstrates several atypical features. The patient suffered from chronic isolated left frontal sinusitis as demonstrated by the hypertrophic bone formation, seen on CT scan, and wide erosion of the floor of the sinus. There was extensive bone formation obstructing the area of the nasal frontal duct. Some of this likely represents fibrous dysplasia which is a known factor contributing to the development of the chronic sinusitis. The patient's presenting symptoms were also atypical: slowly- progressive lid ptosis, then diplopia, and then cutaneous sinus development. This presentation lead us to consider an indolent invasive process, such as a neoplasm, "smoldering" inflammatory process, less virulent bacterial process, or other atypical infection.

CONCLUSION: Complications of sinus disease often occur in the context of subtle clinical signs. A high level of suspicion is needed when dealing with disease that does not respond to conventional therapies. A broad differential diagnosis is paramount, as a variety of etiologies should be considered.

THYROID BROKE MY HEART TWICE! A CASE REPORT OF RECURRENT TAKOTSUBO CARDIOMYOPATHY

Ravikanth Papani MD, Sourabh Aggarwal MD, Abhijit Kolla MBBS, Vishal Gupta MD MPH.
Western Michigan University School of Medicine, Department of Internal Medicine, Kalamazoo, Michigan

INTRODUCTION: Takotsubo cardiomyopathy (TC) also known as broken heart syndrome or apical ballooning syndrome is an increasingly reported entity. It consists of transient systolic dysfunction involving the apical and/or mid segments of the left ventricle with compensatory hyperkinesia of the basal segments. Recurrence of TC is extremely rare.

CASE REPORT: We present a 64 year old lady who woke up with severe chest pain on the day of admission. Her initial EKG in the field demonstrated infero-lateral ST segment elevations. She was directly taken to the cath lab. Her coronary angiography was unremarkable. Left ventriculography and echocardiography revealed apical ballooning with hyperkinetic base consistent with TC. A repeat Echo within 48 hours showed reversal of left ventricular dysfunction. Patient had a similar episode 11 months prior, making this a recurrent TC. She is a known hypothyroid patient on Synthroid replacement. She was not on any other medications. She had undetectable TSH and high Free T4 levels during both hospital admissions with normal TSH and Free T4 levels in the intervening period. Her Synthroid dose was reduced and was advised a close follow up.

DISCUSSION: Thyroid hormone has many direct and indirect actions on the cardiovascular system. Hyperthyroid state enhances the sensitivity to catecholamines and can induce cardiac events including but not limited to arrhythmias, heart failure and acute coronary syndrome. Literature review revealed 8 case reports which described TC associated with hyperthyroid state in different contexts, including Grave's disease, post thyroid surgery or radio iodine therapy. With no triggering stress event in our patient, an iatrogenic Synthroid induced hyperthyroid state causing recurrent TC is most the most plausible explanation.

CONCLUSION: To the best of our knowledge, this is the first ever reported case of recurrent Takotsubo cardiomyopathy associated with iatrogenic hyperthyroid state. Literature review also suggests a possible relation between hyperthyroid state and TC. More research is needed to define the association and management of recurring TC in hyperthyroid patients.

CIRCULATING TUMOR CELLS (CTC) OR CARCINOCYTHEMIA: A CASE REPORT

Ravikanth Papani MD, Pramod Acharya MD, Sreenivasa R Chandana MD PhD

Western Michigan University School of Medicine, Department of Internal Medicine, Kalamazoo, Michigan

INTRODUCTION: Presence of cancer cells in the circulating blood in patients with metastatic solid organ malignancy is called as Carcinocythemia or Circulating Tumor Cells (CTC). Their role in Oncology as a prognostic marker is of increasing value in the recent years.

CASE REPORT: We present a 66 year old Caucasian lady who was admitted for inpatient palliative chemotherapy for recently diagnosed Stage IV metastatic invasive right breast carcinoma. Laboratory evaluation included peripheral blood smear as a work-up for pancytopenia. Peripheral smear showed few highly abnormal cells that are very similar to the cells from patient's known pleomorphic lobular carcinoma. Flow-cytometric immunophenotyping of peripheral blood was negative for Leukemia/Lymphoma cells. In spite of holding chemotherapy and multiple transfusions, patient's blood counts continuously dropped and eventually she expired 16 days after admission.

DISCUSSION: Capturing tumor cells on a peripheral smear is a very rare phenomenon. Near thirty case reports have been published since the first description by Ashworth in 1869. CTC have been described in malignancies involving several organs including lung, breast, prostate, pancreas, muscle, skin melanoma. The rarity of CTC in blood makes their detection extremely challenging, but technological advances in recent years made it possible to detect and enumerate CTC. The potential clinical implications of CTC detection or enumeration are of increasing interest, including the use of CTC as prognostic biomarker. The presence of five or more CTC per 7.5cc blood has been shown to be associated with poor prognosis and increased mortality. Serial CTC enumerations in one patient can also be used to monitor and compare the efficacy of systemic cancer therapies.

CONCLUSION: Circulating Tumor Cells is an extremely rare phenomenon and is associated with poor prognosis and increased mortality. More research is required to validate and establish CTC as a tool in clinical practice.

CARDIAC SARCOIDOSIS: A CASE PRESENTATION

Leah R. VanEnk, Christina G.R. Lang, Bronco Grinfield
Western Michigan University School of Medicine, Kalamazoo, MI

INTRODUCTION: Sarcoidosis is a non-caseating granulomatous disease of unknown etiology that can involve almost any organ in the body. Cardiac involvement is one of the least common clinically, but also has some of the most fatal complications including sudden death. The presenting symptoms of cardiac sarcoid are often ambiguous resulting in an extensive and challenging differential diagnosis. Moreover, the diagnosis requires a clinical suspicion and often becomes a diagnosis of exclusion as the clinical and pathologic criteria are difficult to define. This case study illustrates a case of acute heart failure secondary to cardiac sarcoidosis. The diagnosis was primarily based on cardiac MRI findings, biopsy proven granulomatous inflammation (liver) in the setting of multiple granulomas seen in multiple organs, and laboratory values including elevated ACE level. The etiology, clinical manifestations, diagnostic criteria, treatment, and outcomes will be reviewed.

CASE REPORT: A 64 yo Caucasian female with PMH significant for DM2, HTN, CAD, and OSA was admitted by her cardiologist for worsening SOB, peripheral edema, abdominal bloating, and cough suggestive of acute on chronic CHF. Upon admission, physical exam was significant for JVD, 3+ pitting edema, and RUQ tenderness. Lab work-up was significant for a slight anemia, elevated BNP, mildly elevated alkaline phosphatase and AST, elevated PT, aPTT, and D-dimer, and elevated blood sugars. TSH, cardiac enzymes, and calcium were all normal. EKG showed 1st degree AV block, bradycardia, and non-specific T-wave changes. Echo showed septal dyskinesia and stage 2 diastolic dysfunction. CXR showed cardiomegaly and a RLL pulmonary nodule. Chest CT as part of PE protocol showed pulmonary and liver lesions/nodules. A follow up abdominal MRI verified innumerable liver and splenic lesions, and a subsequent liver biopsy showed granulomatous inflammation with hyalinizing parenchymal fibrosis consistent with a diagnosis of sarcoidosis. Cardiac MRI was performed (to be included in poster) demonstrating patchy foci of hyperenhancement in the basal septum and mild global hypokinesis. Supporting laboratory studies to rule in the diagnosis included an elevated ESR, ACE, and RF factor as well as a positive ANA. A second EKG verified a 2nd degree Mobitz (Type 1) heart block. Pertinent infectious disease and autoimmune tests to rule out other etiologies included Histoplasmosis antibody and antigen, quantiferon TB test, brucella antibody, Lyme disease antibody, P and C-ANCA, blood cultures, and fungal and bacterial blood and biopsy cultures. Persistent AV block necessitated placement of a permanent pacemaker. The patient was encouraged to follow up with rheumatology outpatient for further management but declined as she was not interested in any form of steroid therapy. She followed up with her cardiologist 2 weeks after discharge and was still doing well at that time.

DISCUSSION: Cardiac manifestations only occur in ~2% of sarcoid diagnoses making it a rare and difficult diagnosis. Although the diagnostic criteria are still unclear for sarcoid, in 2006, the Japanese guidelines were revised by the Japan Society of Sarcoidosis and Other Granulomatous Disorders. These guidelines identify cardiac sarcoidosis by either of two methods: 1) Histological diagnosis (through the presence of noncaseating granuloma on myocardial biopsy) in addition to the histologic or clinical diagnosis of extracardiac sarcoidosis. 2) The presence of a histologic or clinical diagnosis of extracardiac sarcoidosis plus a combination of major and minor cardiac criteria. At least three major criteria or at least one major and three minor criteria are required. Major criteria include advanced AV block, basal thinning of the interventricular septum, cardiac gallium uptake, and LVEF <50 percent. Minor criteria include abnormal ECG findings (PVCs or VT, RBBB, axis deviation or abnormal Q wave), abnormal echocardiography, perfusion defect detected by thallium or technetium scintigraphy, late gadolinium enhancement on cardiac magnetic resonance imaging, and more than moderate monocyte infiltration or interstitial fibrosis on endomyocardial biopsy.

CONCLUSION: Unfortunately, our patient reports a significant "negative reaction" to steroids, the mainstay of therapy and thus has declined further evaluation at a larger center. She did have a permanent pacemaker placed, which should improve potential poor outcomes secondary to fatal arrhythmias and/or conduction abnormalities. Among patients with cardiac sarcoidosis, sudden death due to ventricular tachyarrhythmias or conduction block accounts for 30 to 65 percent of deaths.

MOYAMOYA DISEASE: A RARE CAUSE FOR STROKE-LIKE SYMPTOMS IN AN ADULT

Richa Varshney, Amy Attaway, Arvind Nehra
Western Michigan University School of Medicine, Kalamazoo, Michigan

INTRODUCTION: Moyamoya disease has been under recognized as a cause of ischemic and hemorrhagic strokes in Western countries. The purpose of this report is to describe the case of a Caucasian patient with Moyamoya disease and to review the literature on other such cases.

CASE REPORT: We report a 30 year old Caucasian male with no past medical history who presented with right sided facial and upper extremity hemiparesis. MRI/MRA of the brain revealed multifocal areas of acute to sub-acute trans-cortical infarction involving the frontal and parietal lobes bilaterally with angiographic findings suggestive of Moyamoya disease. A cerebral angiogram confirmed these findings with significant collateral circulation. The patient was started on aspirin and plavix with partial improvement in hemiparesis with physical therapy and speech therapy.

DISCUSSION: Moyamoya disease is a rare chronic progressive vascular disease characterized by bilateral stenosis of the vessels of the Circle of Willis and prominent arterial collateral formation. Patients with the angiographic appearance of moyamoya and no known risk factors are considered to have moyamoya disease, while those with one of the well-recognized associated conditions (neurofibromatosis type 1, cranial irradiation, Down syndrome, and sickle cell disease) are classified as having moyamoya syndrome. The etiology of moyamoya disease is unknown. The high incidence among the Japanese and Asian population, together with a familial occurrence of approximately 10 percent of cases, strongly suggests a genetic etiology. It may develop in children and adults, but the clinical features differ. Ischemic cerebrovascular events, either TIA or infarction, are more prevalent than hemorrhagic events in children with moyamoya, while hemorrhagic stroke is more common in adults. Cranial CT and/or MRI are useful for the detection of brain infarction and hemorrhage in patients with moyamoya. Vascular imaging with MRA, CTA, or conventional catheter angiography is essential to demonstrate stenotic or occlusive lesions in the distal internal carotid arteries and the arteries around the circle of Willis.

CONCLUSION: There is no cure for Moyamoya disease. Secondary stroke prevention is largely centered on surgical revascularization techniques. Untreated patients often suffer cognitive and neurologic decline due to repeated ischemic stroke or hemorrhage. Clinical trials are ongoing to investigate biological mechanisms and focus on finding ways to prevent, treat and cure them. We underlined the necessity of Functional MRI and PET scanning which may provide more objective criterion on the outcome in patients with Moyamoya disease.

MICROSCOPIC POLYANGITIS PRESENTING AS ISOLATED MYOPATHY - A RARE PRESENTATION

Richa Varshney

Western Michigan University School of Medicine, Kalamazoo, MI

INTRODUCTION: This is an unique case of microscopic polyangitis(MPA) presenting as isolated myopathy. There have been only one case report of pulmonary-muscle syndrome in MPA but isolated muscle involvement has not been previously described.

CASE REPORT: A 77 year old Caucasian female with no significant medical history admitted with progressive proximal weakness worse in lower extremities for 6 months which is getting worse for 3 weeks. Review of system was unremarkable. On examination she has 1/5 hip flexion and 2/5 shoulder abduction bilaterally. Few months ago he was referred to the University of Michigan and was diagnosed with Muscular Dystrophy. No muscle biopsy was done during that assessment. An extensive laboratory work-up was performed during this hospitalization that yielded some key positive findings. The patient's c-ANCA, smooth muscle antibody were positive along with raised ESR and CRP. Although normal CK levels provided initial clue against an inflammatory myopathy, patient's CT angiogram of the abdomen showed signs of significant vasculitis. Subsequently right biceps muscle biopsy report reviewed in Mayo clinic confirmed the presence of severe myopathy in the setting of vasculitis. Institution of cyclophosphamide and steroid resulted in improved (3/5) muscle strength.

DISCUSSION: Common symptoms and signs of vasculitis include fatigue, weakness, fever, arthralgias, abdominal pain, hypertension, renal insufficiency (with an active urine sediment containing red and white cell and occasionally red cell casts), and neurologic dysfunction. ANCA positivity either PR3/MPO by immunofluorescence and confirmed by ELISA strongly argues against PAN and in favor of one of the ANCA associated vasculitides. The histopathologic findings segmental necrotising vasculitis within skeletal muscle (and no granuloma unlike GPA), combined with ANCA positivity by both immunofluorescence and ELISA is required for the diagnosis of MPA. The distinction of MPA is a frequent clinical problem due to variable clinical presentation, non-specific histologic findings, imperfect association with p-ANCA (anti-MPO) as c-ANCA (anti-PR3) can be positive in MPA.

CONCLUSION: Prompt diagnosis of microscopic polyangiitis (MPA) is important to permit initiation of therapy that may be life-saving and organ sparing. This may be difficult since presenting signs and symptoms are hard to distinguish from those of a patient with non-vasculitic processes such as infection or malignancy.

CRYPTOCOCCAL MENINGOENCEPHALITIS IN AN IMMUNOCOMPETENT HIV-NEGATIVE PATIENT

Richa Varshney, Melissa Olken
Western Michigan University School of Medicine, Kalamazoo, MI

INTRODUCTION: Diagnosis of cryptococcal meningoencephalitis can be challenging due to subacute onset of symptoms and nonspecific presentation. The objective is to present a rare case of cryptococcal meningoencephalitis in an immunocompetent patient and review the pertinent literature, especially in relation to non AIDS versus AIDS patients.

CASE REPORT: A retired 88-year-old man with NHL in remission for 3 years was admitted with a 2-3 days history of reduced mobility and confusion. He was fully functional before this episode. PMH was significant for allergic rash for which he has been taking oral prednisolone intermittently for 2 months. Review of symptoms was unremarkable. Physical examination, laboratory findings, CT scan and MRI Head were unremarkable. He was treated for presumed community acquired pneumonia. Over the following week, he remained increasingly confused and hemodynamically unstable. Lumbar puncture was performed. Cryptococcal meningoencephalitis was diagnosed with positive cryptococcus culture and antigen titer in cerebrospinal fluid/serum. The patient died.

DISCUSSION: Cryptococcal meningoencephalitis is the most frequently encountered manifestation of cryptococcosis. Most patients with cryptococcal meningitis are immunocompromised. The most common forms of immunosuppression other than HIV include glucocorticoid therapy, solid organ transplantation, cancer (particularly hematologic malignancy), and other conditions such as sarcoidosis and hepatic failure. Clinical presentation is variable. Some patients have symptoms for up to several months prior to diagnosis, whereas others present with an acute illness of only a few days. Fever is observed in approximately 50 percent of cases. Typically headache, lethargy, personality changes, and memory loss develop over two to four weeks. Patients may also present with disseminated disease. A lumbar puncture is necessary for diagnosis of cryptococcal meningoencephalitis. The opening pressure should be measured, along with India ink evaluation, cryptococcal antigen testing, fungal culture, and routine spinal fluid studies. The diagnosis is established definitively by culturing the organism from the spinal fluid. Radiographic imaging of the brain with computed tomography (CT) or magnetic resonance imaging (MRI) prior to lumbar puncture is important in the setting of focal neurologic signs, papilledema, or impaired mentation. Serum cryptococcal antigen testing is useful for evaluation of patients without HIV infection, although a negative result cannot be used to rule out cryptococcal meningoencephalitis.

CONCLUSION: In the presence of neurological symptoms, cryptococcal meningoencephalitis is a rare but possible differential diagnosis in daily routine. Diagnosis is made with culture of cerebrospinal fluid as well as antigen detection in most cases. Unfortunately, treatment failures and mortality remain high. Consequently, pathogenesis and immune responses to this organism are active areas of research that provide exciting opportunities for innovative therapies. Further work is needed to better define the scope of the problem and track the epidemiology of this infection, in order to prioritize prevention, diagnosis, and treatment strategies.

PRIMARY SQUAMOUS CELL CARCINOMA OF THE COLON: A CASE REPORT & REVIEW OF LITERATURE

Ravikanth Papani MD, Chintan Pareshbhai Shah MD, Sreenivasa Chandana MD PhD
Western Michigan University School of Medicine, Department of Internal Medicine; WMCC, Department of Hematology/Medical Oncology, Kalamazoo, Michigan

INTRODUCTION: Primary squamous cell carcinoma (PSC) is a rare occurrence in colon. Fewer than hundred cases were reported in the literature. It's clinical profile, biological behavior and management strategies are not entirely clear.

CASE REPORT: Our patient is an 81-year old Caucasian female, presented with abdominal pain for 3 months duration. Her past medical history is significant for pulmonary embolism, achalasia cardia and left breast cancer. Her past surgical history was significant for breast lumpectomy with negative sentinel lymph node biopsy. She underwent an abdominal computer tomography (CT) and a colonoscopy on an outpatient basis. CT abdomen showed a colonic splenic flexure mass with extension into surrounding structures and liver lesions. Patient underwent exploratory laparotomy with segmental resection of splenic flexure and wedge biopsy of liver lesions. Pathology revealed poorly differentiated infiltrating squamous cell carcinoma of colon with involvement of regional lymph node and liver. She was discharged on the post-operative day 6 with a readmission within 4 days with multiple medical complications. As patient's general condition declined, she elected to go to hospice care.

DISCUSSION: PSC is an extremely rare clinical entity with an incidence of one per 10,000 colorectal carcinomas. With first case reported in 1919, fewer than 100 cases were reported in literature. It is more common in Caucasian males, with increased incidence in fifth and sixth decades of life. Abdominal pain is the most common presenting symptom. Criteria for the diagnosis of PSC includes- evidence of squamous histopathology from colonic mass, no evidence of any other primary source in the body causing secondary metastasis and no evidence of involvement of anal canal. No clear etiology has been established. Several risk factors, including inflammatory bowel disease and human papilloma virus, have been described. Surgical resection is the preferred choice in management for PSC. Adjuvant/neo-adjuvant chemo radiation has a role in patients with advanced stage. Prognosis of PSC is difficult to establish because of the rarity of these tumors. But in general, it carries worse prognosis than adenocarcinoma.

CONCLUSION: PSC of the colon is an extremely rare condition, with worse prognosis than adenocarcinoma. We report a rare case of PSC of sigmoid colon in an elderly woman with dismal prognosis. A national/international registry of this condition would help in understanding risk factors, clinical profile, and biology.

SPLINTER HEMORRHAGES NOT CAUSED BY INFECTIOUS ENDOCARDITIS, AN EXTREME CASE OF THROMBOANGIITIS OBLITERANS.

Devin Malik, Kevin Struzzi, Timothy Schubert, Gagan Preet, Sourabh Aggarwal, Heidi Egloff,
Mark Loehrke

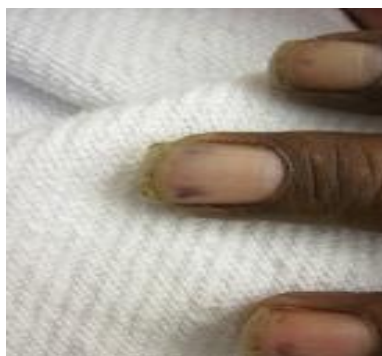Western Michigan University School of Medicine, Department of Internal Medicine, Kalamazoo, MI

INTRODUCTION: Splinter hemorrhages are small areas of bleeding that occur on finger and toenails as a result of damage from inflammation, embolic disease or trauma. It is most commonly associated with infective endocarditis and is a sign of systemic inflammatory disease. Upon review of the literature on thromboangiitis obliterans, we were unable to find many instances that documented the development of splinter hemorrhages.

CASE REPORT: We describe a 51 year old African-American man with no significant past medical history besides hypothyroidism. He endorsed a greater than 30 year history of smoking cigarettes, as well as occasional marijuana use. He presented to the ER with complaints of diffuse muscle pain for 2 weeks that was attributed to strenuous activity (riding his bicycle around town collecting scrap metal for money). On admission he had a mildly elevated creatine kinase of 560 and was started on IV fluids for suspected mild rhabdomyolysis. Over the next 3 days he developed severe pain in bilateral hands associated with splinter hemorrhages and petechiae, especially on distal fingertips. These lesions, as well as his pain, got progressively worse during the hospitalization period. A consulting rheumatologist performed an unremarkable workup which included the following negative tests: ANA, RF, ANCA, anti-centromere, and cryoglobulins. His CRP was elevated at 30.2 mg/L and he had an ESR of 53mm/hr. An arterial duplex ultrasound showed a normal flow proximal to the wrists in bilateral hands, but no flow distally. A transesophageal echocardiogram was performed to rule out endocarditis; and was negative for vegetations. Due to rapid progression of the symptoms, including risk of limb viability, the patient was transferred to a major medical center where interventions could be performed that was beyond the capabilities of the primary hospital. This treatment included IV prostaglandins. Upon admission to the major medical center, the patient provided a more comprehensive history. He admitted to periodic episodes of painful, pale digits that occurred during strenuous activity and/or exposure to cold temperatures. These symptoms are similar to those that present in Raynaud's phenomenon.

DISCUSSION: Thromboangiitis obliterans, also known as Buerger's disease, is an obliterative vasculitis that affects medium to small arteries, usually in distal extremities. The disease is associated with tobacco smoking and has a higher prevalence in men. This disease can lead to digital ischemia, necrosis, and gangrene. The treatment is smoking cessation; however, in advanced cases, this may not be sufficient to stop the progression of the disease. Other associated findings include a "cork-screw" appearance of arteries on an angiography. Unlike some other vasculitides, steroids are not the answer for treatment. Surgical bypasses are occasionally tried but not always successful. Patients who continue to smoke may end up requiring amputation of affected extremities. In the case of this patient, he opted to not cease tobacco use and eventually required amputation of his right arm distal to the elbow and several fingers on his left hand.

CONCLUSION: Subungual splinter hemorrhages are an uncommon presentation that precedes diagnosis of thromboangiitis obliterans. Early recognition of this disease followed by smoking cessation may represent the only potential preventative measure in avoiding limb amputation and the resultant physical handicaps.



JOD-BASEDOW PHENOMENON IN A PATIENT WITH GRAVES DISEASE VISITING FROM AN IODINE DEFICIENT REGION.

Aaron C Roberts, MD

Western Michigan University School of Medicine, Kalamazoo, MI

INTRODUCTION: Jod-Basedow phenomenon is described as a thyrotoxic event caused by exposure to increased amounts of iodine. It has historically been documented in regions deficient in iodine. However, this phenomenon has been increasingly reported as a consequence of administration of iodine-containing contrast for imaging studies. We present an interesting case of recurrent atrial flutter and pulmonary edema secondary to Jod-Basedow phenomenon induced by increased iodine exposure in a patient with Graves disease.

CASE REPORT: The patient is a 48-year-old female who presented with a sudden onset of tachycardia, chest pain and shortness of breath. She was visiting a family member in the United States and was planning on returning to Tanzania the next day. She was previously treated with carbimazole for her Graves disease for six months with marked improvement of her symptoms. On admission, physical exam was significant for a large multinodular goiter, tachycardia with an irregular rhythm, bibasilar crackles on lung auscultation and trace pedal edema. EKG demonstrated atrial flutter. CT chest with iodine contrast showed enlarged pulmonary arteries, cardiomegaly and peribronchial cuffing suggestive of heart failure. Her TSH was 0.01 U/mL and her free T4 was 2.5 ng/mL. The rest of the laboratories were within normal limits. She was admitted to the intensive care unit (ICU) for non-invasive positive pressure ventilation and management of her atrial flutter. Treatment with propylthiouracil 200 mg three times a day and propranolol was initiated as well as furosemide intravenously with rapid clinical improvement. However, she refused to undergo cardioversion so she could return home to Tanzania. Within 24 hours of being discharged, the patient was admitted again with signs and symptoms of pulmonary edema. EKG again demonstrated atrial flutter. Her respiratory status quickly deteriorated requiring emergent intubation for acute respiratory failure. During this admission, hydrocortisone 50 mg every 12 hours was added to the previous regimen. Cardiac catheterization showed a markedly elevated left ventricular diastolic pressure of 35 mmHg, but no evidence of coronary artery disease. An echocardiogram showed an ejection fraction of 35-40%. The patient was extubated after 3 days and discharged in good condition.

DISCUSSION: Iodine is a required element needed for the synthesis of thyroid hormone. Iodine deficiency leads to elevated levels of thyroid stimulating hormone (TSH) in the blood and produces a goiter. Thyrotoxicosis is due to an independent production and release of thyroid hormones by autonomous areas within the thyroid gland. An increased iodine supply induces the production of thyroid hormones independently by a normal regulatory mechanism. Upon further review, several factors prompted the thyrotoxic manifestations seen in our patient. Firstly, she was visiting from an endemic iodine deficient region of Africa. Her physical exam was significant for a multinodular goiter indicative of absent autoregulation of her thyroid. Moreover, the combination of an iodine-rich diet and administration of a large amount of iodine-containing contrast contributed to the Jod-Basedow phenomenon and tachycardia-induced cardiomyopathy.

CONCLUSION: Clinicians should be careful when administering any iodine-containing substance to patients with an endemic goiter and pay special attention to their travel history. Upon review of the literature, there were four other case reports demonstrating Jod-Basedow phenomenon although none resulting in tachycardia-induced cardiomyopathy. This case highlights the significant complications of inducing thyrotoxicosis in a patient with a goiter visiting from an endemic iodine deficient region.

NOT EVERY RISE IN PROCALCITONIN IS A BACTERIAL INFECTION

Sourabh Aggarwal, Lisa Ryan, Devin B. Malik, Mark Schauer

Western Michigan University School of Medicine, Department of Internal Medicine, Kalamazoo, MI

INTRODUCTION: Procalcitonin (PCT), a peptide precursor of calcitonin, is produced by the parafollicular cells of the thyroid and neuro-endocrine cells of lung and intestine. PCT level is now used increasingly as a marker of bacterial infection. An elevated PCT (>2 ng/mL) is advocated as indicator to initiate antibiotic therapy in patients with presumed infection. However, not every rise in PCT is a bacterial infection

CASE REPORT: A 49 year old woman presented in July complaining of fever (102 °F at home), nausea, vomiting, diffuse headache, confusion, light-headedness, neck stiffness and photophobia for one day. She also had dull, diffuse, non-radiating abdominal pain without any association to meals/constipation/diarrhea. Her past medical history, family history and social history were non-contributory. Physical examination was unremarkable except for a temperature of 99.5 °F, tachycardia (pulse 115/min) and dry oral mucosa. Labs revealed WBC count of 18,000/mm³, pro-calcitonin level - 145.88 ng/mL, AST - 560 Units/L, ALT - 213Units/L, ALP - 201Units/L. Otherwise, remainder of complete blood count and metabolic panel was normal. CT scan of head was normal. Lumbar puncture was done, blood cultures sent and she was started on Vancomycin and Ceftriaxone and hydrated intravenously. All cultures were negative; lumbar puncture and urinalysis results were normal. Viral meningitis panel was negative. Chest X-ray and CT scan of abdomen and pelvis with contrast did not show any acute abnormality. Hepatitis panel was negative for Hepatitis A and B and was positive for Hepatitis C IgG antibody. The next day, she became afebrile, WBC dropped to 11,300/mm³, PCT to 92.3 ng/mL, AST - 57 Units/L, ALT - 86 Units/L and ALP - 111 Units/L. On further questioning, she reported that she was in the sun the entire day of admission moving to a new apartment in 95° F heat and did not drink any fluids. She was diagnosed with heat stroke and antibiotics were stopped. The patient responded well and was discharged the following day with normalization of her labs.

DISCUSSION: This patient had highly elevated PCT without an underlying infectious etiology. The PCT levels started trending downwards the next day which correlates with the PCT half-life of 25 to 30 hours. Heatstroke is a life-threatening illness, which usually presents clinically with systemic inflammatory response syndrome and can have elevated PCT values. A recent meta-analysis found that PCT distinguished sepsis from non-septic systemic inflammation with a sensitivity of only 71% and a specificity of 71%.

CONCLUSION: Thus, in a patient with high PCT, clinicians should not forget to have an index of suspicion for other non-infectious inflammatory etiologies.

RETROPERITONEAL MASS AND THE DIAGNOSTIC DILEMMA

Sourabh Aggarwal, John Lund, Lisa Ryan, Mark Schauer

Western Michigan University School of Medicine, Department of Internal Medicine, Kalamazoo, Michigan

INTRODUCTION: A retroperitoneal mass can have a varied and diverse etiology and pose a diagnostic challenge to clinicians.

CASE REPORT: A 28 year-old Caucasian male presented with complaint of left sided abdominal pain for 2 days. The pain was sharp, constant, 8/10 in severity and radiating to left flank. It was associated with fever, night sweats and non-bilious vomiting for 4 days. He reported a 15 lbs unintentional weight loss in 1 month with decreased appetite. There were no other complaints. Past medical history was significant for multicystic dysplastic kidney disease with right kidney regressing before birth and only left functional kidney. He reported a similar pain episode 8 months prior which was treated by pain medication in local emergency department without further evaluation. Otherwise, family history and social history were non-contributory. Physical exam revealed tachycardia (pulse 110 beats/min) and left sided abdominal tenderness without guarding or rebound tenderness and with normal genital exam. Labs were significant only for WBC count of 14,300/mm³, CRP of 14 mg/L and ALP level of 253 Units/L. Urinalysis was normal. CT scan of abdomen and pelvis with contrast revealed three discrete heterogeneous peripherally enhancing fluid collections in the left retroperitoneum. The largest demonstrated several foci of gas, measured 9.2 cm and resulted in hydronephrosis. Tentative diagnosis of retroperitoneal abscesses was made and Ceftriaxone and Metronidazole was started. Interventional radiology was consulted for percutaneous drainage. However, the drains showed only minimal serosanguinous fluid. Gram stain and culture from drain and peripheral blood were negative. Cytology of aspirates revealed malignant cells suggesting either a germ cell tumor or malignant lymphoma. Core needle biopsy revealed malignant cells staining positive for OCT-4 and CD117 consistent with a germ cell tumor. Alpha-feto protein and hCG levels were normal. Testicular ultrasound revealed an abnormal echogenicity in the left testicle suggesting fibrosis and mild atrophy. MRI of abdomen and pelvis revealed heterogenous left testicular lesion, with necrotic left hemipelvis and retroperitoneal mass. Radical left inguinal orchiectomy was done and pathology revealed a 0.2 x 0.2 cm residual seminoma. He was diagnosed with metastatic seminomatous testicular cancer and was referred for post-op chemotherapy. At the time of abstract submission, he is still receiving chemotherapy.

DISCUSSION: Retroperitoneal lesions can pose a great diagnostic dilemma. Our patient had a metastatic testicular malignancy despite having a benign genital exam and negative tumor markers. Internists should have high suspicion for malignancy even in the absence of classical signs and symptoms. Testicular germ cell tumors (GSTs) are the most common malignancies affecting adult men between the ages 15 to 35 years. The majority of men with a testicular tumor present with a painless mass. Less commonly, local symptoms (such as pain or heaviness in the lower abdomen), gynecomastia, or symptoms due to metastases may be the presenting manifestation. The initial evaluation of patient with suspected testicular tumor should include scrotal ultrasound, measurement of serum tumor markers, chest x-ray and CT or MRI of the pelvis and abdomen to look for evidence of regional lymph node metastases. Prior to definitive treatment, the possible need for cryopreservation of sperm should also be considered. Radical inguinal orchiectomy is used both to provide the histologic diagnosis and local tumor control.

CONCLUSION: Clinicians should have a high index of suspicion and have low threshold for malignant etiologies as early detection and treatment can have a great impact on prognosis.

ISOLATED RIGHT VENTRICULAR NON-COMPACTION WITH ST ELEVATION IN CHEST LEADS

Sourabh Aggarwal, Jagadeesh Kalavakunta, Vishal Gupta

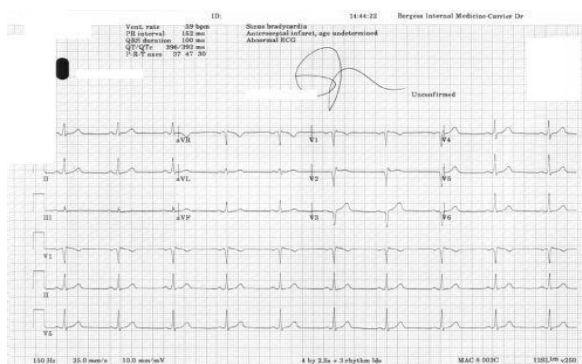
Western Michigan University School of Medicine, Department of Internal Medicine, Kalamazoo, Michigan

INTRODUCTION: Non-compaction of ventricular myocardium (NCVM) is a rare genetic disorder caused by intrauterine arrest of endomyocardial development. Left ventricle is the usual site of NCVM with rare reports of isolated right ventricular non-compaction (IRVNC). We describe a first case of asymptomatic patient IRVNC with abnormal EKG finding.

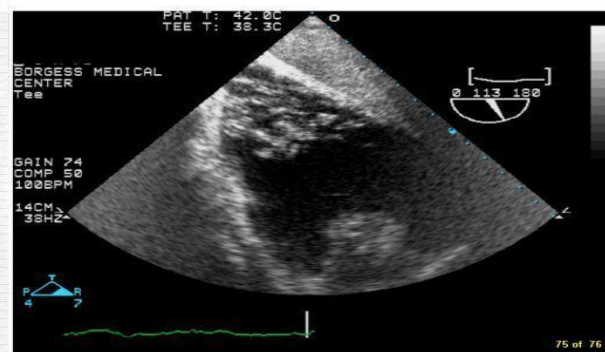
CASE REPORT: A 51 year old asymptomatic gentleman presented to our cardiology clinic after EKG at his physician's office was found abnormal. He had hyperlipidemia and history of smoking with non-contributory family history. Physical examination was unremarkable. EKG showed sinus bradycardia, normal QRS duration, with poor R-wave progression and ST-segment elevation in leads V1 - V3 as shown in panel 1. Transthoracic Echocardiography showed spongy right ventricle with hypertrophied trabeculae and deep inter-trabecular recesses without any signs of hypokinesia. Transesophageal echocardiography revealed spongy appearance of right ventricle with trabeculations with deep fissures and grooves located in the RV apical wall consistent with apical non compaction in right ventricle as shown in panel 2. Left atrium and ventricle were normal sized. A follow up TTE done a year later showed no changes. The patient stays asymptomatic till date.

DISCUSSION: We report, to our best knowledge, 1st case of asymptomatic IRVNC with ST-elevation in V1-V3 leads. Ventricular non-compaction results from failed obliteration of inter-trabecular spaces and regression of ventricular sinusoids between 5th- 8th week of embryonic development. The diagnostic criteria include finding a two-layered structure of LV wall, with the end-systolic ratio of the non-compacted to compacted myocardial layer >2 , predominantly in the apical and mid-ventricular areas. EKG findings in NCVM include non-specific changes and intra-ventricular conduction delay. The most important clinical manifestations include heart failure, sudden cardiac death, cardio-embolic events, and syncope. Patients with NCVM have variable prognosis, ranging from prolonged asymptomatic course to severe cardiac disability, leading to heart transplantation and death. The worse prognostic indicators include patients with heart failure NYHA classes III-IV, the Left Ventricle end diastolic diameter >60 mm, the left bundle branch block, chronic atrial fibrillation, a ratio of non-compacted to compacted myocardium greater than 3 and involvement of three or more segments.

CONCLUSION: We report, to our best knowledge, 1st case of asymptomatic IRVNC with ST-elevation in V1-V3 leads. EKG findings in NCVM include non-specific changes and intra-ventricular conduction delay. ST-elevation in IRVNC has never been reported. Clinicians should have high index of suspicion for diagnosis of IRVNC in patient with ST elevation in V1-V3 leads and differentiate it from Brugada syndrome which is accompanied by coved or saddle back pattern. Follow-up of patients with Echocardiography is recommended



Panel 1 - EKG at time of presentation



Panel 2 - "Spongy" appearance of right ventricle

FAKE PNEUMONIA! ACUTE MONOCYTIC LEUKEMIA PRESENTING AS PULMONARY LEUKOSTASIS: A CASE REPORT

Ravikanth Papani MD, Mark Loehrke MD

Western Michigan University School of Medicine, Department of Internal Medicine, Kalamazoo, Michigan

INTRODUCTION: Leukostasis or symptomatic leukocytosis is a complication of acute leukemias, characterized by an extremely elevated white cell count with symptoms of decreased tissue perfusion. We report a patient who was initially admitted for pneumonia but found to have pulmonary leukostasis from undiagnosed leukemia on further work up.

CASE REPORT: The patient is a 75 year old Caucasian male who presented to his primary care physician's office with chief complaints of fevers, dyspnea and dry cough. He started a five day course of oral Azithromycin with minimal response. As the symptoms worsened, he went to a nearby emergency department where chest imaging revealed right basal pulmonary infiltrates. He was admitted to the floor and received intravenous antibiotics. He was discharged in three days with oral course of antibiotics. Unfortunately his fevers returned again and the patient came to our tertiary care hospital for further evaluation. Initial work up showed leukocytosis, anemia and thrombocytopenia. Inflammatory markers including sedimentation rate, C-reactive protein and ferritin were extremely high. Chest radiograph has right basal infiltrates and Computer Tomography (CT) of the chest confirmed right lower lobe and left mid lower lobe consolidations. He was admitted to the floor and started on broad spectrum intravenous antibiotics. Aggressive attempts to isolate an organism failed including pleural fluid and bronchoalveolar lavage studies. His fevers persisted and the white count continued to rise. Parallel work up for anemia revealed bone marrow failure with a very low reticulocyte count. A bone marrow biopsy made the diagnosis of acute monocytic leukemia. The patient was immediately transferred to a higher center for emergent chemotherapy.

DISCUSSION: Leukostasis is a fatal complication of granulocytic leukemias. It is a pathological diagnosis in which white cell plugs are seen in the microvasculature. Its incidence varies with leukemia type and patient population. Leukostasis is more common in acute myelogenous leukemias. Exact pathophysiology is unknown but various theories have been postulated. Lungs and brain are the most commonly involved organs. Pulmonary signs and symptoms include dyspnea with or without interstitial or alveolar infiltrates on imaging studies. Nearly 80% of patients are febrile. White counts are usually above 50,000/cc. The diagnosis is mostly empirical when a patient with known leukemia and hyperleukocytosis presents with respiratory or neurological distress. It is considered as a medical emergency and efforts should be made to rapidly lower the white cell count. Cytoreduction can be achieved through the use of chemotherapy or leukopheresis. If left untreated, the one-week mortality is 20-40%. Our patient was not a known leukemic patient. His presentation was similar to a community acquired pneumonia. He did not respond to the initial pneumonia treatment so other diagnoses were sought. Further work up revealed an acute leukemia and patient was transferred to higher center for emergent cytoreduction therapies.

CONCLUSION: Leukostasis is a fatal complication and medical emergency of known acute leukemias. The diagnosis becomes challenging in patients not known to be leukemic. Our case also reiterates that in patients with a non-resolving pneumonia, physicians should suspect malignant and other autoimmune conditions mimicking pneumonia.

MANAGEMENT OF VON GIERKE'S DISEASE IN PATIENT'S INTOLERANT TO CORNSTARCH

Shannon E. McCormack, Sourabh Aggarwal, Gagan Preet, Amanda Gittus

Western Michigan University School of Medicine, Department of Internal Medicine, Kalamazoo, Michigan

INTRODUCTION: Von Gierke disease is an autosomal recessive disorder resulting from deficiency of the enzyme glucose-6-phosphatase which impairs the liver's ability to produce free glucose. It leads to deranged supply of glucose to rest of the body during fasting resulting in hypoglycemia. These patients, however, are able to digest complex starches like cornstarch allowing them to feed every 4-6 hours rather than every 2 and prevent life-threatening episodes of hypoglycemia.

CASE REPORT: Here, we discuss a 25 year old male with a known diagnosis of Von Gierke's disease and developmental delay who presented to our hospital with complaint of dizziness and a recorded blood sugar at home of 62 mg/dL. There were no other complains. Because of this patient's intolerance to cornstarch, he was on Polycose, a glucose polymer with a peak glucose response in 30 minutes. His brother is also a known case of Von Gierke's disease and is also managed with Polycose. His blood glucose upon arrival to the emergency room was 32mg/dL. His complete cell count, basic metabolic panel and urinalysis were unremarkable. The patient's mother reported that the Polycose being used at home was exposed to sunlight and "looked different". He was admitted to the hospital and his blood sugar was monitored and tightly controlled with a glucose drip. The Polycose that was being used by his brother was brought to hospital and given to the patient. His blood sugar was monitored for 24 hours without recurrence of the hypoglycemia while on the new Polycose. A new batch of polycose was ordered and he was discharged home. He has not reported any other episodes of hypoglycemia to date.

DISCUSSION: Management of patients with inherited metabolic disorders is a challenge that was formerly reserved for pediatricians. However, as more and more of these patient's live into adulthood, the internist may be called upon to learn about the presentation and management of such diseases. Intolerance to cornstarch in infants and children with von Gierke's disease is not uncommon but has been rarely reported in adults. Polycose in these patients should be administered cautiously at frequent intervals as hypoglycemia can have severe implications.

CONCLUSION: As more and more patients with congenital metabolic derangement survive into adulthood, internists should be more vigilant and cautious in management of these patients. Patients with von Gerke's disease should be given appropriate diet at frequent intervals and closely followed up.

RECURRENT MYOCARDIAL INFARCTION WITH A RARE ANOMALY; RIGHT CORONARY ARTERY ARISING FROM MID LEFT ANTERIOR DESCENDING ARTERY.

Kwabena O. Adu-Gyamfi, MD, Christopher Rogers DO

Western Michigan University School of Medicine, Internal Medicine Department, Bronson Advanced Cardiac Healthcare, Kalamazoo, MI

INTRODUCTION: Origin of the Right Coronary Artery (RCA) from the Left Anterior Descending (LAD) is an extremely rare subtype of the single coronary artery anomaly. It has estimated prevalence of 0.015% of the population corresponding to 1.2% of all coronary artery anomalies. The recognition of the condition is important to prevent serious events as myocardial infarction and sudden death. We present a case of a patient presenting with recurrent acute myocardial infarction in the setting of this unique anomaly.

CASE REPORT - BODY 1: A 59 year-old African American female with history significant for hypertension, diabetes mellitus and hyperlipidemia, who presented to the Emergency Department with new-onset epigastric pain. Her EKG was consistent with acute anterior inferior ST Elevation Myocardial Infarction (STEMI). Emergent catheterization showed no RCA arising from the right coronary cusp or proximal aorta; the RCA was found to originate from the midpoint of the LAD, which subsequently gave rise to the Posterior Descending Artery. The LAD had significant stenosis proximal to the origin of the RCA and total occlusion of the distal segment. The remaining coronary arteries, including the anomalous RCA, showed no significant disease. She underwent angioplasty, thrombectomy and stent placements to the proximal and mid LAD.

BODY 2: After an uneventful post-operative course, she presented 15 months later with another STEMI. Cardiac catheterization showed diffuse proliferative in-stent restenosis of the proximal LAD. The patient underwent successful coronary bypass grafting of the Left internal mammary artery to the LAD. She is recuperating well post-operatively.

CONCLUSION: Previous studies on this anomaly have suggested that there is increased risk of coronary artery disease secondary to stenosis occurring at bifurcations and increased association with atherosclerosis. Proximal disease is also associated with more extensive ischemic myocardial damage. The choice of treatment for this coronary anomaly is controversial. It is important for practitioners to be aware of this anomaly and optimize management to prevent catastrophic outcomes

EPIDEMIOLOGY OF TAKOT-SUBO CARDIOMYOPATHY IN US: WHAT DOES NATIONWIDE INPATIENT SAMPLE DATA SAY?

Sourabh Aggarwal, Ravikanth Papani, Vishal Gupta

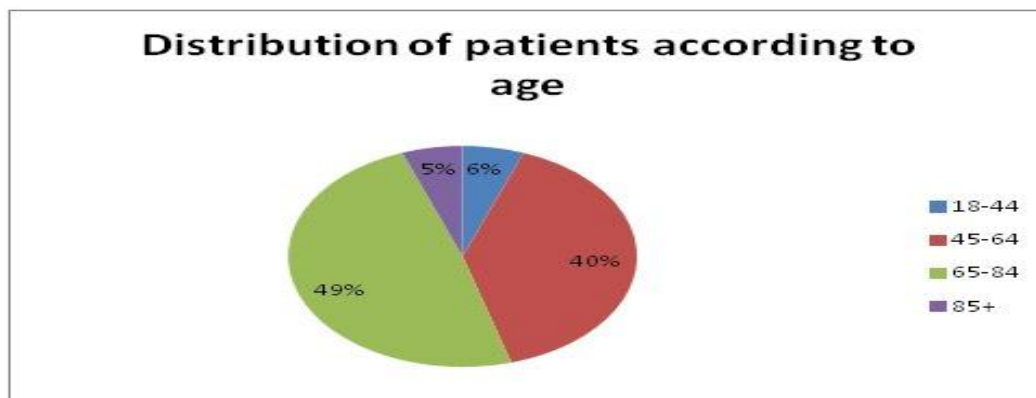
Western Michigan University School of Medicine, Department of Internal Medicine, Kalamazoo, Michigan

INTRODUCTION: Takot-subo cardiomyopathy is a transient systolic dysfunction of the apical and/or mid segments of the left ventricle that mimics myocardial infarction (MI) but in the absence of obstructive coronary artery disease. Takot-subo cardiomyopathy is an increasingly reported entity with an unclear etiopathogenesis. This study was done to identify the epidemiology of Takot-subo cardiomyopathy patients in US.

METHODS: We used Nationwide Inpatient Sample (NIS) data for the purpose of this study which is an inpatient data from a national sample of over 1,000 hospitals and approximates a 20-percent stratified sample of U.S. community hospitals. We identified all the patients discharged with principal diagnosis of Takot-subo cardiomyopathy in year 2010 by International Classification of Diseases- Ninth revision (ICD-9) code 9 of 429.83. The data related to age, gender and average length of stay was extracted.

RESULTS: A total of 5,159 patients were discharged with primary diagnosis of Takot-subo cardiomyopathy. It represents the 0.013% of all discharges during 2010, with mean length of stay of 3.6 days. Age group of 65-84 was most commonly affected 48.84%. Age-wise distribution of patients is depicted in figure 1. Females were more commonly affected than males (92.51% versus 7.49%) but had shorter length of stay [Mean \pm Standard error (3.6 \pm 0.1 days versus 3.9 \pm 0.3 days)]. Mean length of stay was highest for patients with age >85 years (4.0 \pm 0.3 days) followed by 65-84 years (3.7 \pm 0.2 days). Mean length of stay was 3.4 days for patients below age of 65 years. There was no in-hospital mortality reported.

CONCLUSION: Takot-subo cardiomyopathy is more commonly found in patients greater than 65 years of age and far more common in females as compared to males. Mean length of stay of patients is 3.6 days with good in-hospital prognosis.



MONONEURITIS MULTIPLEX- AN UNCOMMON MANIFESTATION OF THIS SUMMER'S COMMON INFECTION

Arani D. Nanavati, Shrey V. Velani, Ross E. Driscoll
Western Michigan University School of Medicine, Kalamazoo, Michigan

INTRODUCTION: Knowing the fact that this summer the US experienced a noticeable epidemic of West Nile virus infection; we present here a case of mononeuritis multiplex as an uncommon presentation of the most discussed infection this summer.

CASE REPORT: A 49 years old male presented in August; with left arm, right leg weakness and mild left leg weakness. Other symptoms included high grade fever, chills, headache, nausea and vomiting. Relevant vital signs include Temperature of 103 F and Heart rate-100/minute. Neurological exam revealed muscle strength of 2/5 in left deltoid and 4/5 in left biceps and triceps. Left hip flexors were 3/5 and hamstrings, quadriceps were 4/5. Right hip flexors, hamstrings and quadriceps were 2/5. Reflexes were 2+ in right arm, 1+ in left arm and 2+ in left leg with areflexia in right leg. Pertinent lab findings include WBC count of 15.2 with 85% Neutrophils and 8% lymphocytes, ESR of 55. CSF examination revealed clear, colorless fluid with RBC count- 15, WBC count-534, Monocytes- 69, segmented neutrophils- 31, Glucose- 50 and Protein 109. Patient's clinical condition was confounding so Infectious diseases and Neurology were consulted. Blood culture, serum ANA, anti Ro/SSA, anti La/SSB antibodies, anti RNP, anti Sm, Anti Ds-DNA antibody, ANCA, anti cardiolipin antibody, HIV- ELISA, Lyme disease antibody titre, Rocky Mountain Spotted Fever serology, RF, serum meningo-encephalitic panel, paraneoplastic panel, rickettsial serology, nasopharyngeal swab for Influenza A and B, parainfluenza virus was ordered. CSF was tested for bacterial and fungal culture, HSV, VZV, CMV PCR, VDRL, West Nile virus serology and cryptococcal antigen. MRI of brain revealed mild scattered white matter hyperintensities. Patient was treated with Vancomycin, Ceftriaxone, Doxycycline and Acyclovir while awaiting the test results. EMG was performed which showed reduced left median and ulnar, absent left and reduced right peroneal nerve compound motor action potentials. It also showed slowed sensory conduction in bilateral medial and ulnar nerves. All the lab tests came back negative except West Nile serology which was positive on the 8th day of hospitalization. All the antibiotics were discontinued and IvIg treatment was not thought to be beneficial so patient was given supportive therapy and rehabilitation.

DISCUSSION: Mononeuritis Multiplex is simultaneous or sequential involvement of individual noncontiguous nerve trunks resulting in loss of motor and/or sensory function. Diagnoses can be confounded by such a presentation and West Nile encephalitis may be misdiagnosed as Guillain-Barré syndrome or other inflammatory neuropathies. Therapies like IvIg administration were considered but not started. Patients usually achieve better quality of life with rehabilitation and supportive treatment.

CONCLUSION: West Nile Virus infection is a rare cause of acute flaccid paralysis/mononeuritis multiplex. Our case depicts an uncommon presentation of a fairly common infection.

A FOLLOW UP SURVEY TO ASSESS THE NUMBER OF INCIDENT/OCCURRENCE REPORTS SUBMITTED BY RESIDENT AND ATTENDING PHYSICIANS AT LOCAL MEDICAL FACILITIES

Susan F. Bannon MD, Mark Schauer MD, Sarah Polcher DO, Eric Yoder DO
Western Michigan University School of Medicine, Kalamazoo, Michigan

OBJECTIVE: To determine the total number of incident/occurrence reports filed by current resident and attending physicians and effectiveness of recent education in proper protocol of how and when to submit an incident/occurrence report.

BACKGROUND: In 2000, the report titled “To Err is Human: Building a Safer Health System,” highlighted the number of medical errors that occur on a yearly basis. It stated that anywhere from 44,000 to 98,000 people die in hospitals as a result of medical errors each year. Subsequent research has demonstrated that despite physicians understanding the importance of disclosing medical errors, incident reporting remains low. It is essential to report and evaluate adverse outcomes so that processes and procedures can be assessed to improved patient safety and quality of medical care provided.

METHODS: Education in the form of an email to existing resident and attending physicians was sent regarding proper protocol and where to find further details on the Western Michigan University School of Medicine (WMU School of Medicine) Intranet Site. A session at orientation for incoming residents was held regarding the same. Surveys with a short questionnaire were sent to resident and attending physicians via email inquiring about the number of incident reports they have filed at WMU School of Medicine, Bronson Methodist Hospital and Borgess Medical Center.

RESULTS: In a post-education survey, a total of 104 surveys were submitted of which 98 (94.2%) were completed. The total number of resident surveys submitted was 74 and the total number of attending surveys submitted was 30. Total number of physicians who have submitted incident/occurrence reports in the past: Resident physicians (n=72): 12.5% have submitted a report, 87.5% have not. Attending physicians (n=29): 55.2% have submitted a report, 44.8% have not. If the resident physician has reported an incident, 77.4% have submitted 1-2 reports, while 22.2% have submitted 3-4 reports. Reasons resident physicians gave for not submitting a report were 56 (90.3%) stated they did not have an incident to report, 4 (6.5%) stated they did not know how to submit a report, 1 (1.6%) were fearful of the consequences of filing a report and 1 (1.6%) listed other as their reason. Of the attending physicians, 31.3% submitted 1-2 reports, while 43.8% have submitted 3-4 reports, and 25% have submitted 5 or more reports. Reasons attending physicians gave for not submitting incident/occurrence reports were 12 (92.3%) stated they did not have an incident to report and 1 (17.7%) stated other as their reason. When asked if the physician knew how to submit reports at the different institutions the results were as follows: At WMU School of Medicine 27.8% of residents (n=72) responded yes, while 48.3% of attending physicians (n=29) stated yes. At Bronson 36.1% of residents responded yes and 41.4% of attendings responded yes. At Borgess 26.4% of residents said yes, while 48.3% of attendings said yes. 61.1% of residents (n=72) stated they were aware of the type of incidents and occurrences to report while 89.7% of attending physicians (n=29) stated they were aware of the type of reports to file. 24% of respondents had completed our previous survey while 32% had not with 7% identifying themselves as new to WMU School of Medicine since our prior survey. 37% did not remember if they completed our last survey.

CONCLUSION: Direct comparison of data between a survey in December 2011 (pre-education) and January 2013 (post-education) shows no change in the number of incident reports filled by either resident or attending physicians. However, an increase in resident physicians reporting knowing how to submit an incident report at each of our facilities with the same number of attending physicians reporting knowing how to file a report was seen. There was an increase for both resident and attending physicians in knowing what type of incidents to report. Despite this improvement seen in reported knowledge of how and what to report, there is still a large number of both resident and attending physicians who report they do not know how or what to submit for incident/occurrence reporting. It remains apparent that continued education regarding incident/occurrence reporting is beneficial to our resident and attending physicians and needs to continue to be present in our curriculum.

EVALUATING CLINICAL OUTCOMES AFTER IMPLEMENTATION OF AN ADVANCED PRACTICE PROVIDER LED RAPID RESPONSE TEAM

Deb Lee-Ekblad, Susan Mastenbrook, Glenn Ekblad, Wendy Beckwith, Paul Birchmeier, Ravikanth Papani,
Jeffrey L. Wilt

Western Michigan University School of Medicine, Department of Internal Medicine; Borgess, Adult Critical
Care Department, Kalamazoo, Michigan

INTRODUCTION: Implementation and development of Rapid Response Teams (RRT) has been recommended by the Institute for Healthcare Improvement's 5 Million Lives and 100,000 Lives campaign to reduce incidents of avoidable medical harm and reduce unnecessary deaths. Their effectiveness in reducing cardiac arrests and overall hospital mortality is not well established. Borgess Medical Center (BMC), a level one trauma and regional medical referral center, instituted a dedicated RRT team in September, 2010 consisting of Advanced Practice Providers (APP).

HYPOTHESIS: Developing a Rapid Response Team led by an APP will decrease cardiac arrests outside the intensive care unit (ICU), decrease overall hospital mortality, and improve utilization of the service through improved continuity of care, increased communication, increased staff education, and adherence to best practices. In addition, this will be accomplished through the development of protocols to improve medical management, implementation of an early warning system, proactive rounding, and increased communication with staff and providers by the APP.

MATERIAL & METHODS: A retrospective cohort study of 386 cardiac arrests and 3,154 rapid response calls at BMC was conducted. All patients that developed cardiac arrest or had a rapid response called between January 1, 2009 to June 30, 2012 were included in the study. Patients excluded were those that had a cardiac arrest in the emergency department.

RESULTS: Since January 2009, there has been a 15.5% reduction in cardiopulmonary arrests outside the ICU. The frequency of activations per 1000 discharges has increased from 17.7 in 2009 to 73.5 in 2012. This increased utilization of the team and the reduction in non-ICU-treated cardiac arrests has not been associated with lower hospital mortality rates.

DISCUSSION: a) Since inception, the RRT has shown markedly increased utilization. From FY 2009 to FY 2012, the activation rate has increased by a factor of 4.1. b) Implementation of the RRT has reduced the percentage of cardiac arrests outside of the ICU by 48%. This is likely due to identification of prearrest conditions with early intervention or transfer to the ICU. c) Overall hospital mortality has not changed at this juncture. This may be in part due to the change in code status of critically ill patients by the RRT or ICU service after transfer. This would translate into lower code rates without an improvement in overall hospital mortality.

CONCLUSION: An APP led Rapid Response Team has shown to reduce non-ICU-treated cardiopulmonary arrests and increase frequency of activations. This has not correlated to a reduction in overall hospital mortality. This may be in part owing to establishment of DNR status of critically ill patients by the RRT which removes the severely ill from the cardiopulmonary arrests data without an improvement in overall mortality rates.

DETECTIVE WORK! SUSPECTING AND INVESTIGATING SECONDARY IMMUNE DYSFUNCTION IN ADULTS: A CASE REPORT

Ravikanth Papani, Sangeeth Dubbireddi, Thomas E. Flynn

Western Michigan University School of Medicine, Department of Internal Medicine, Kalamazoo, Michigan

INTRODUCTION: Secondary immune dysfunction in adults can result from wide variety of disease processes including malignant, autoimmune and metabolic conditions. We present a patient with Streptococcal poly septic arthritis who was found to have Multiple myeloma on further work up for immune dysfunction.

CASE REPORT: 62 year old African American male presented with pain and swelling in multiple joints of the body. Symptoms started initially in the left elbow joint and progressed to other joints in the body including left shoulder, left ankle and right hand joints. Blood cultures and Synovial fluid from left elbow grew group B beta hemolytic streptococci. Orthopedic service was consulted who took the patient to operating room and performed incision, drain and wash of the affected joints. Meanwhile, a work up has been initiated to find a cause for the Strep agalactiae bacteremia and poly septic arthritis. Secondary immunosuppression from conditions like Diabetes, malignancy or HIV was proposed. Serum total Immunoglobulin G (IgG) level was 4,390mg/dl (normal range 750-1,560mg/dl). Serum protein electrophoresis showed an abnormal band in the gamma region consistent with monoclonal protein. Serum immunofixation revealed an IgG kappa monoclonal protein. Serum free kappa light chain level was 7.65 (normal range 0.33-1.94mg/dl) with kappa/lambda free chain ratio 4.27 (normal range 0.26-1.65). Bone marrow biopsy revealed 10-20% of kappa light chain restricted plasma cells in the marrow confirming a plasma cell proliferation disorder. A Diagnosis of Multiple myeloma was made according to the International Myeloma Working Group criteria. Hematology/Oncology service was consulted and patient was initiated on appropriate chemotherapy on outpatient basis.

DISCUSSION: Immune function in adults is altered by many underlying disease processes. As with primary immune deficiency, secondary immune dysfunction leads to an increased susceptibility to infections. Conditions like diabetes, uremia, cirrhosis and malnutrition affect immune system by causing imbalance in blood chemistry, nutrients and metabolic waste products. Whereas in Multiple myeloma- factors like impaired lymphocyte function, suppression of normal plasma cell function, hypogammaglobulinemia, and chemotherapy induced neutropenia-contribute to increased risk of infections. And certain disorders such as nephrotic syndrome, protein losing enteropathy and peritoneal dialysis can result in hypogammaglobulinemia due to protein loss. Environmental exposures that can result in immune dysfunction include ionizing, ultraviolet radiation and toxic chemicals. It is crucial to find the underlying cause early to initiate appropriate treatment. This may require few detective skills from the physicians in evaluating these patients. Our patient had poly septic arthritis with Streptococcus agalactiae which usually colonizes genitourinary tracts in humans. An underlying immunosuppression was suspected and a cause for the same was investigated. Patient's Multiple myeloma was disclosed at an early phase and he was started on chemotherapy with very good response.

CONCLUSION: Many conditions can cause secondary immunosuppression in adults including metabolic, malignant and autoimmune diseases. Every attempt should be made to find the underlying cause so that the treatment can be initiated at an early phase.

LEUKOCYTOCLASTIC VASCULITIS CAUSED BY NATEGLINIDE: A CASE REPORT

Sourabh Aggarwal, Richard Chang, Christine Dugan, Kevin Kavanaugh

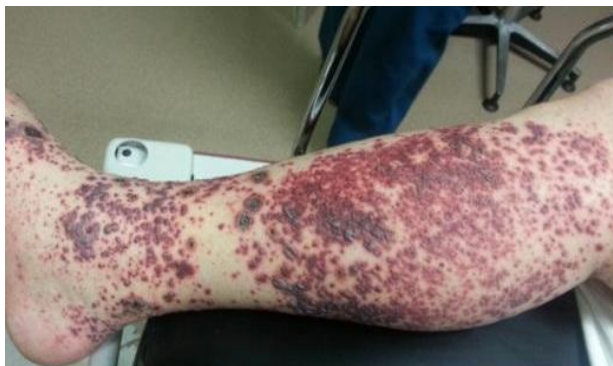Western Michigan University School of Medicine, Department of Internal Medicine, Kalamazoo, MI

INTRODUCTION: Meglitinides, a class of drug used in type 2 diabetes mellitus, includes repaglinide and nateglinide and is associated with hypoglycemia, nausea, diarrhea and peripheral edema. We report a unique adverse reaction to nateglinide.

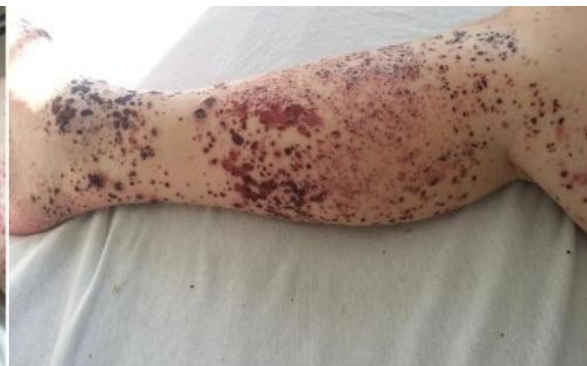CASE REPORT: A 55-year-old Caucasian male presented with a diffuse rash on skin which started on his ankles bilaterally 3 weeks before presentation. It began as pinkish-red in color, with irregular boundaries and had multiple blisters. The rash progressed over next one week to involve both lower legs. He took oral Solu-Medrol pack for 3 days without any effect on the progression of the rash. Over the ensuing 2 weeks, his rash progressed to involve both thighs, the abdomen, bilateral flanks and both arms, sparing chest and his face. He complained of itching in the rash, but no pain. His past history included diabetes mellitus type 2 for which he took insulin, metformin and nateglinide. Examination revealed a diffuse patchy maculo-papular rash, with some patches having pustules, purpura and eschar. The lesions on his right leg are shown in panel 1. Initial complete blood count and metabolic profile were unremarkable except for hyperglycemia (glucose 260mg/dL) and HbA1c of 12.4%. Urinalysis and blood culture were unremarkable except for glycosuria. ESR was 78mm/hr (normal 0-20mm/hr) and CRP was 11.2mg/dL (normal 0.0-0.9mg/dL). Anti-nuclear antibody, anti-neutrophilic cytoplasmic antibody, complement C3 level, C4 level and cryoglobulin level were unremarkable. Tests for HIV and syphilis were negative. Total IgM and IgG were normal. Skin biopsy showed areas of fibrinoid deposition with wall thickening in superficial dermal blood vessels. It also demonstrated perivascular and interstitial inflammatory infiltrates with neutrophils, occasional eosinophils, leukocytoclasia, extravasated red cells and endothelial cell enlargement consistent with leukocytoclastic vasculitis. The patient was recently started on nateglinide three months prior to admission. There was no other identifiable predisposing factor for rash. During hospitalization, his nateglinide was stopped and started on oral prednisone 60 mg daily. His lesions improved over the next one week as shown in panel 2. The temporal association of nateglinide to his rash and no effect of the initial Solu-Medrol (while on nateglinide) on its progression makes the nateglinide a most likely causative agent for rash. At discharge, his nateglinide was taken off medication list, other home medications continued and prednisone tapered off. Since discharge, his rash has improved without any recurrence of lesions.

DISCUSSION: LCV (also called hypersensitivity vasculitis) is associated with use of drugs, including report on repaglinide, but has never been reported by nateglinide. Criteria for diagnosis include presence of three or more of following; age >16, a possible offending drug in temporal relation to the symptoms, palpable purpura, maculopapular rash and biopsy of a skin lesion showing neutrophils around an arteriole or venule which has a sensitivity and specificity for the diagnosis of 71 and 84 percent, respectively. Management includes stopping the offending drug and steroid therapy. Our patient was treated successfully with oral steroids.

CONCLUSION: We recommend that clinicians should be vigilant for a new rash after starting nateglinide and have high index of suspicion for possible underlying leukocytoclastic vasculitis.



Panel 1 - Rash at time of presentation



Panel 2 - Improvement in rash after treatment

WATCH OUT! RED FLAGS OF CHRONIC BACK PAIN IN ADULTS: A CASE SERIES

Ravikanth Papani, Sourabh Aggarwal, Nicholas Demark, Sarah J. Polcher, Richard R. Roach
Western Michigan University School of Medicine, Department of Internal Medicine, Kalamazoo, MI

INTRODUCTION: Patients with chronic back pain present to health care facilities with frequent acute exacerbations. Health care providers often assume their back pain as the pain from the primary musculoskeletal process- like degenerative disk disease or pain from the hardware in the spine. We describe a series of patients who actually presented with their chronic back pain but found to have some serious underlying issues on work up.

CASE REPORT: Case 1: The patient is a 72 year old Caucasian female presented with severe back and right hip pain. Her past medical history was significant for chronic back pain, status post spinal fusion surgery many years ago. She received Methadone orally 30mg a day for about three years and then suddenly over a period of few months, her Methadone requirements raised to 90mg a day. She visited her primary care physician (PCP) four months ago and one week prior her presentation, she had an Emergency Department (ED) visit with complaints of severe right hip and back pain. She was given narcotics in the ED and was discharged. She presented again to the ED within a week with worsening symptoms. The patient underwent further work up this time which revealed an adenocarcinoma of the right lung with widespread metastasis in thoracolumbar spine. Sudden worsening of her back pain was from bony metastatic lesions requiring increased Methadone doses. Case 2: The patient is a 35 year old male presented to the ED with sudden onset back pain between shoulder blades, dyspnea and dizziness. His past medical history was significant for a motor vehicle accident status post thoracic spine fusion surgery and chronic back pain on Hydrocodone-acetaminophen (Norco) at home. Vitals included blood pressure of 141/86mm of Hg. Electrocardiogram was negative for any ST segment changes. His chest radiograph showed spinal hardware but negative for any acute cardiopulmonary process. The patient was discharged to home with refills on Norco. He returned to the ED within few hours as the symptoms worsened. His blood pressure was 176/104 mm of Hg. Further work up revealed type B thoracic aortic dissection, extending into abdominal aorta. He was admitted to the intensive care unit for aggressive hemodynamic monitoring. Case 3: The patient is a 56 year old Caucasian male presented to an office with worsening back pain. His past medical history was significant for cervical and lumbar disc degenerative disease for about five years with radicular symptoms in lower extremities. His PCP ordered a Computer Tomography (CT) of lumbosacral spine which was not done as the patient did not have an insurance. Patient qualified for disability benefits eventually. A Magnetic Resonance Imaging (MRI) study of the lumbosacral spine was performed which incidentally found a left renal mass. Urology service performed a left radical nephrectomy and pathology revealed clear cell renal cell carcinoma. The patient's worsening back pain was from the renal mass rather than musculoskeletal in origin.

DISCUSSION: Chronic back pain is a very common problem in primary care practice. Patients with chronic back pain are usually on pain medicines including narcotics, on a long term basis. They often present to health care providers at clinics and emergency departments with frequent exacerbations of their chronic back pain and seek narcotic medications. Most of the time, health care providers assume this from the same condition which is responsible for chronic back pain- often times it is degenerative disk disease or the spinal hardware. And patients do not get a thorough evaluation for their back pain, missing few serious underlying causes. Many associations came up with certain red flags to look for in chronic back pain patients, which if present warrants a thorough evaluation and work up. The American College of Radiology has identified 10 red flags (Table 1) - recent significant trauma, unexplained weight loss, unexplained fever, immunosuppression, history of cancers, intravenous drug abuse, osteoporosis, age >70 years, focal neurological deficits and back pain of >6 weeks duration. These factors should be recognized early and appropriate imaging should be performed without any delay to find the underlying cause.

CONCLUSION: An acute on chronic back pain may not always be due to the primary musculoskeletal process. Any red flags in these patients should prompt a thorough evaluation and work up to find the underlying cause at an early stage.

ANAPLASMOSIS PRESENTING AS MENINGISMUS IN MICHIGAN: AN UNUSUAL PRESENTATION IN AN UNUSUAL LOCATION

Sourabh Aggarwal, Arani Nanavati, Dustin Bivins, Susan Bannon

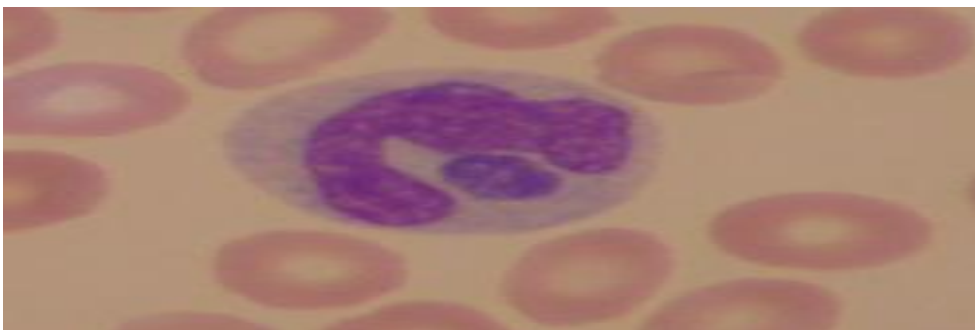
Western Michigan University School of Medicine, Department of Internal Medicine, Kalamazoo, MI

INTRODUCTION: Infections can have varied presentations and often provide a diagnostic challenge to physicians. When this unusual presentation occurs in a region that does not typically see the disease, it is even more of a challenge to diagnose. We describe an interesting case of Anaplasmosis presenting with meningismus in Michigan.

CASE REPORT: 59 year old female presented with complaints of altered mental status, headache, dizziness, nausea, photophobia, phonophobia and dizziness. There was no other complaint. The patient denied any ill contacts, pets in house and tick bites. Physical examination was unremarkable except for fever (101.1Â°F). Her labs revealed WBCs 6300/mm³, RBCs 3.92 million/mm³, hemoglobin 11.7mg/dL and platelets 123,000/mm³. CT scan of the brain and lumbar puncture were unremarkable. Next day her fever spiked to 103Â°F with WBC dropping to 3500/ mm³, RBCs to 3.17 million/ mm³ and platelets to 52,000/ mm³. C-reactive protein was 16.5 mg/dL and ESR was 33mm/hr. Workup for DIC was negative. Her blood and urine cultures were negative. Her workup for HIV, infectious mononucleosis, syphilis and Lyme disease were negative. However, her peripheral blood smear showed morulae inside monocytes characteristic of Anaplasmosis (formerly known as Human Granulocytic Ehrlichiosis (HGE)) as shown in image. She was started on doxycycline 100mg twice daily and she reported improvement in symptoms. Her blood count also started improving. IgG and IgM for Anaplasma phagocytophilum were positive. PCR was sent for A. phagocytophilum which came back positive. She was sent home on doxycycline to complete a 14 day course.

DISCUSSION: A. phagocytophilum, a rickettsial-like organism, is an obligate intracellular parasite. The principal vector is Ixodes scapularis which is also the vector of Lyme disease and Babesiosis. Most of the cases (90%) are found in the six states of New York, Connecticut, New Jersey, Rhode Island, Minnesota, and Wisconsin. Anaplasmosis can present from subclinical and self-limited to subacute or chronic infection. Most patients are febrile with nonspecific symptoms such as malaise, myalgia, headache, chills, arthralgia and cough. Neurologic symptoms, including mental status changes, stiff neck, and clonus, are less common. The most common laboratory findings include leukopenia and thrombocytopenia. Clinical diagnosis is based upon the history, clinical, and epidemiologic features of an individual case and is crucial early in the course of disease and clinicians should have high index of suspicion even in the presence of a normal white blood cell and platelet count. Examination of a peripheral blood can reveal intraleukocytic intracytoplasmic inclusions (morulae) which are highly specific for anaplasmosis. Serologic testing for antibodies using the indirect fluorescent antibody (IFA) test is the preferred and most widely available confirmatory test. The drug of choice in all patients is doxycycline. Patients who have intolerance or allergy to tetracyclines can be treated with rifampin (300 mg twice daily) for 7 to 10 days.

CONCLUSION: Clinicians should have high index of suspicion for ehrlichiosis as a cause for fever with leukopenia and thrombocytopenia.



CHRONIC PAIN MANAGEMENT AT AN INTERNAL MEDICINE RESIDENCY CLINIC: DATA ANALYSIS ON PATTERNS AND POLICY ADHERENCE

Sourabh Aggarwal, Ravikanth Papani, Shrey Velani, Susan Bannon

Western Michigan University School of Medicine, Department of Internal Medicine, Kalamazoo, MI

INTRODUCTION: Chronic pain management is a challenging tasks for primary care physicians. A pain policy was initiated at our Internal Medicine clinic in 2007, which required patients to sign a pain contract, undergo random urine drug screen(UDS), follow one provider and have Michigan Automated Prescription system (MAPS) profile on chart. This study was done to analyze the demographic profile, diagnosis, drugs given, pattern of patients per residents and adherence to policy in patients on pain contract.

METHODS: All the patients currently on chronic pain medication (>4 weeks) were identified and retrospective chart review done. All the information was extracted and analysis done using SPSS v16.0.

RESULTS: We identified 107 patients [53 males (49.53%) and 54 females (50.47%)] on chronic pain medication with mean age of 56.35 ± 13.42 years (males 56.87 ± 12.37 years, females 55.83 ± 14.47 years, $p=0.69$). Seventy-four patients (69.16%) were Caucasian, 27 (25.23%) African-American and 4 (3.74%) Hispanics. Seventy-nine patients (73.83%) were unemployed, 10 (9.35%) retired and 8 (7.48%) currently employed. Forty-three patients (40.19%) described them as single, 36 (33.64%) married, 21 (19.63%) separated and 7 (6.54%) widowed. The most common diagnosis was back pain (63 patients, 58.88%), followed by arthritis (12 patients, 11.21%), fibromyalgia (10 patients, 9.35%), malignancy (6 patients, 5.61%) abdominal pain and trauma (3 each, 2.8%) and 10 patients (9.35%) had other diagnosis including chronic pain syndrome, lymphedema, shoulder pain, phantom limb, neuropathic pain and Marfan syndrome as shown in figure 1. Thirty nine patients (36.45%) had concomitant psychiatric. The drug most commonly used was hydrocodone-acetaminophen in 60 patients (56.07%), morphine 21 patients(19.63%), methadone 14 patients(13.08%), oxycodone-acetaminophen 9 patients (8.41%), oxycodone 5 patients(4.67%), fentanyl 4 patients (3.74%), hydromorphone 3 patients (2.8%), propoxyphene and Tylenol 3 one patient each (0.93%). Seventeen patients (15.89%) had >1 pain medication with overall prescription depicted in figure 2. A single resident saw mean of 2.4 ± 1.2 patients on pain contract (Median 2, range 1-6). First year residents saw 2.23 ± 1.09 (Median 2, range 1-4), second years' 2.43 ± 1.03 (Median 2, range 1-4) and third years' 2.53 ± 1.56 (Median 2, range 1-6) with no difference in number of pain patients seen by residents per their year of training (p value=0.93). Pain contract was on file for 105 patients (98.13%) on chronic pain medication and 104 patients (97.2%) had UDS results on chart with 101 (94.39%) having it in preceding 12 months. All patients had MAPS profile on chart.

CONCLUSION: This study indicates that most patients on chronic pain medication are single, middle aged, unemployed, Caucasians without any gender predilection. Back pain is the most common diagnosis and hydrocodone-acetaminophen the most favored drug. The patients are seen equally by all residents irrespective of their stage in training (range 1-6 patients), and clinic adherence to pain policy is >94% in all 3 parameters.

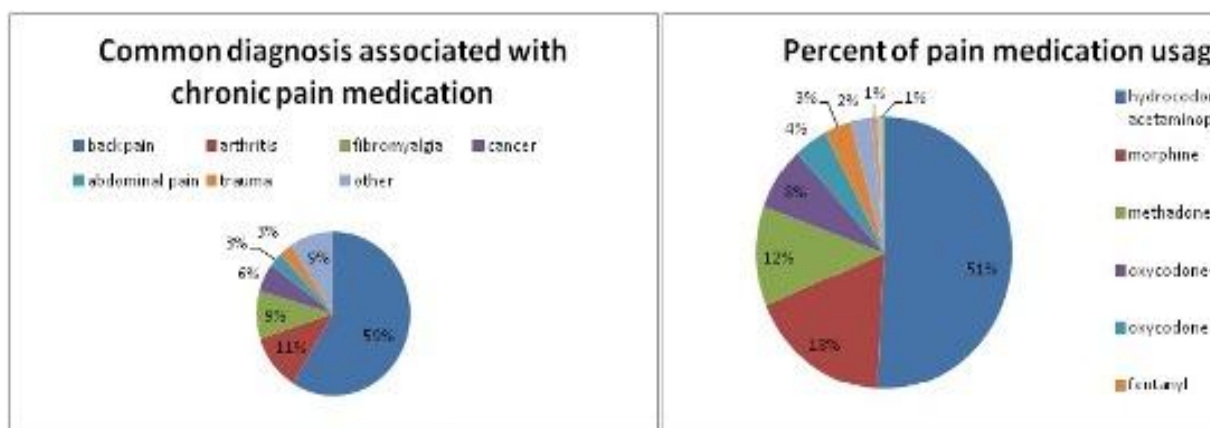


Figure 1 - common diagnosis associated with chronic pain medication

Figure 2 - Percent of pain medication usage

SARCOIDOSIS: DIAGNOSTIC AND THERAPEUTIC CHALLENGE

Chintan Shah, Ravikanth Papani, Richard Roach

Western Michigan University School of Medicine, Internal Medicine, Kalamazoo, MI

INTRODUCTION: Sarcoidosis: Diagnostic and Therapeutic Challenge

CASE REPORT: 64 yrs old Caucasian female with h/o diabetes and hypertension presented with gradually worsening shortness of breath, dry cough, pedal edema, and abdominal distension of 1 yr duration. Patient denied smoking, drinking or drug abuse. On admission, she was afebrile, with heart rate 50/min, breathing 22/min, normal blood pressure and 97 % SPO₂ on 2-3 L oxygen with nasal cannula. Physical exam was unimpressive except scattered respiratory crackles and pedal edema. Initial investigation showed unremarkable CBC and CMP except elevated ALP and ALT - 216 and 77 IU/L respectively. EKG showed 2: 1 heart block. Echocardiogram revealed stage II diastolic dysfunction. CXR showed 1.4 cm nodule on right lower lobe, with subsequent CT chest revealed multiple lung nodules and ill-defined liver lesions. MRI abdomen showed enumerable lesions in liver and spleen. Cardiac MRI revealed delayed hyper enhancement of basal septum consistent with cardiac sarcoid. Biopsy of liver lesion showed non-caseating granulomatous inflammation with negative acid fast and fungal stain. Angiotensin converting enzyme level was elevated 98 U/L (reference range 9- 67) and ESR was 45 mm/hr. Extensive lab work including quatiferon gold, brucella, lyme, histoplasma antigen and antibody, influenza A and B, blood culture, acid fast and fungal culture of liver tissue were negative. Moreover, ANA, Rheumatoid factor, ANCA, antimitochondrial antibody were unremarkable. Heart catheterization revealed normal EF (55- 60%), wedge pressure of 16 mmhg with elevated pulmonary artery and RA pressure of 60 and 16 mmhg respectively. Patient received diuretics, fluid restriction, pacemaker, and oral steroid was started once the diagnosis of sarcoidosis was confirmed but patient could not tolerate side effects.

DISCUSSION: Sarcoidosis is multisystem disease characterized by non-caseating granuloma of the involved organ. Our patient was never diagnosed with sarcoidosis, in addition, presented at the age of 64 years with symptoms of heart failure found to have advanced pulmonary hypertension (PH) with extensive involvement of lung, heart, liver, and spleen. Diagnosis is difficult due to myriad presentation and absence of single diagnostic test. For confirmation, histopathology and exclusion of other potential etiologies is necessary. Cardiac MRI is emerging as an important tool in diagnosing cardiac sarcoid and has been proven to be superior to EMB (endomyocardial biopsy). Moreover, presence of delayed hyper enhancement on cardiac MRI has been proven to be a predictor of ventricular arrhythmia and poor outcome. Furthermore, treatment is also challenging due to marked variability of clinical course. PH is a common complication, occurs in 5-74% of patients. While steroid is the standard of care and role is known in cardiac sarcoid, evidence in PH is conflicting. Similarly, utility of specific PH therapy is also poorly understood. In addition, data about the safety and efficacy of alternative agents like MTX, Azathioprine, Leflunomide, and Anti-malarials is also very limited.

AIRTRAQ-SUCCESSFUL USE IN AN AIR MEDICAL TRANSPORT SYSTEM

William Selde, Kyle English, Matthew Heffelfinger, Jan Eichel, Glenn Ekblad
Western Michigan University School of Medicine, Kalamazoo, MI

INTRODUCTION: There is a large body of literature that shows that the AirTraq device achieves equal or superior rates of successful intubation in all classes of user. A recent prospective human trial of the device questioned the first pass success rate and whether effective training could occur outside the Operating Room (OR). The purpose of this study was to investigate the first pass success rate for intubation with the AirTraq (AT) device in an air ambulance setting from Aug. 1 2009 to Aug. 1 2012 and compare it to direct laryngoscopy (DL).

RATIONALE: We hypothesize that the AirTraq device will be as effective overall as direct laryngoscopy, and that this requires no OR training to achieve.

MATERIAL & METHODS: A retrospective chart review of 161 intubations by air ambulance flight nurses from Aug. 1, 2009 to Aug. 1, 2012 was conducted. Data regarding date of service, devices used, number of attempts, rescue device use, and complications was gathered and analyzed. The generalized estimating equation and the chi-squared test were used to evaluate the data.

RESULTS: 161 intubations were reviewed. 135 met inclusion criteria. Overall first pass success rate for AT was 79% (71/90) and DL was 70% (43/61). The success rate for any attempt with the AT device was 80% (76/95) and DL 72% (54/75). The overall success rate of intubation for any patient in which either AT or DL was attempted is 96% (130/135).

DISCUSSION: All of the West Michigan Air Care nurses trained exclusively on mannequins in a sim lab setting. Our intubators had significantly more than 5 Airtraq intubations during their training with the device. The authors of the article that questioned the effectiveness of Airtraq only did 5 OR training intubations.

CONCLUSION: AirTraq was shown to be as effective as direct laryngoscopy. All air crew training for the AirTraq device was performed on mannequins. The success of the device compared to DL shows that mannequin training is sufficient to implement the AirTraq device for pre-hospital intubation.

METHAMPHETAMINE ABUSE, POOR DENTAL HYGIENE, AND ITS EFFECT ON MECHANICALLY VENTILATED PATIENTS

Sergey B. Gukasov, Ryan W. Bradstreet, Luis H. Toledo-Pereyra
MSU College of Human Medicine, Western Michigan University School of Medicine, Kalamazoo, MI

INTRODUCTION: The popularity of methamphetamine (meth) as an abused street drug has dramatically increased since the 1980s. Approximately 35 million people worldwide, and 10.4 million people in the United States, currently abuse meth (Hamamoto, 2009). Methamphetamine is a highly addictive and potent psychological stimulant that increases alertness, concentration and energy; it can also induce mania, feelings of euphoria, feelings of self-esteem and increased libido. One side effect of chronic meth abuse is its effect on oral dentition, as presented by Ravenel (2012) who found chronic abuse to be correlated with higher rates of decayed surfaces and missing teeth. Studies have shown an increase in ventilator-associated pneumonia in patients with poor oral hygiene.

RATIONALE: Once considered the “meth capital of Michigan,” Allegan County, and Southwest Michigan as a whole, have been notorious for high per capita illegal production and abuse of methamphetamine. This issue affects the cities and communities of Southwest Michigan, resulting in fires, explosions and chronic health issues. As residents of Southwest Michigan, we looked into the effects of meth abuse on periodontal disease, and the association between poor oral hygiene and ventilator-associated pneumonia (VAP).

MATERIALS AND METHODS: A comprehensive search of the literature of the last 12 years was performed on PubMed, Cochrane, Medline and ProQuest electronic databases on the effects of methamphetamine abuse on oral hygiene, and the effects of poor oral hygiene on mechanically ventilated patients. Nine studies consisted of randomized controlled trials and cohort studies with statistically significant results determined by p value <0.05. In examining the relationship between methamphetamine abuse and dental disease, Shetty (2010) and Brown (2012) observed dental hygiene in 301 and 17 known meth users compared to controls. To examine the relationship between oral hygiene and ventilator-associated pneumonia, Jones (2011) studied the effects of oral care on dental plaque following intubation in 137 patients. Fourrier (2000), Fourrier (2005), Koeman (2006), Munro (2009), Mori (2006), and Garcia (2009) studied the association between dental hygiene and incidence of VAP in RCTs with 60, 228, 610, 547, 1666, and 1538 patients respectively.

RESULTS: Shetty (2010) and Brown (2012) independently found that patients abusing meth were more likely to report oral health problems than control participants ($p < 0.001$ and $p < 0.05$ respectively). Jones (2011) found that patients receiving oral care had less dental plaque on day 7 compared to day 1 ($p = 0.03$). Fourrier (2000) found that patients treated for nosocomial infection with oral care had less colonization ($RR = 0.53$, $p < 0.05$). Fourrier (2005) also found that positive dental plaque cultures were significantly lower in patients treated with chlorhexidine (29% vs 66%, $p < 0.05$). Koeman (2006) found that patients on chlorhexidine oral treatments had decreased risk of developing VAP ($HR = 0.352$, $p = 0.012$ and $HR = 0.454$, $p = 0.030$). Munro (2009) and Mori (2006) found that chlorhexidine treatment was associated with reduced incidence of VAP ($p = 0.006$ and $p = 0.001$ respectively). Garcia (2009) found that oral treatment was associated with decreased incidence of VAP (8 vs 12 cases per 1000 ventilator days, $p = 0.06$), prolonged development of VAP (4.7 vs 2.9 days, $p < 0.001$), and decreased mortality (14.6% vs 19.4%, $p = 0.01$).

DISCUSSION: Methamphetamine abuse has been shown to have deleterious effects on oral hygiene. A review of the literature consisting of more than 4,800 patients from nine studies, suggested that oral hygiene, prior to and during ventilation, plays a significant role in the risk of developing VAP. This is the most common nosocomial infection in patients who require treatment with mechanical ventilators, and is associated with increased risk of complications, mortality, and length of hospital stay. Patients presenting with “meth mouth” are likely to have more oral bacteria, tooth decay, plaque formation and calculus, putting them at increased risk of developing VAP in situations requiring intubation and ventilator use. Multiple studies have come to similar conclusions, suggesting that oral treatment for ventilated patients results in improved dental hygiene and decreased incidence of VAP.

CONCLUSION: Based on this study, we recommend oral hygienic treatment for all patients who are mechanically ventilated for more than 48 hours, especially in patients with poor dentition related to methamphetamine abuse.

INTERDISCIPLINARY HEALTH FAIR AND THE TENDENCY FOR YOUNG ADULTS TO RECEIVE FOLLOW UP HEALTH CARE

Kaelyn M Monroe, Abby J Smith, Alexandra M Scheidt
WMU Bronson School of Nursing , Kalamazoo, MI

INTRODUCTION: There is a lack of research that focuses on adolescents and young adults obtaining follow-up health care and the reasons for not obtaining follow-up health care after they have been determined to have abnormal test results. Failing to obtain follow-up health care can have detrimental effects on a person's health. Throughout the United States, follow-up care is greatly underutilized. Barriers to obtaining care lead to a low rate of follow-up care in the healthcare field. It has been recognized that certain barriers such as poor family environment, substance abuse, and living below the poverty line lead to poor adherence to follow-up health care recommendations. Many adolescents and young adults experience these barriers to obtaining healthcare, and therefore, do not receive follow-up healthcare when necessary.

RATIONALE: The purpose of this study was to examine the tendencies of adolescents and young adults to adhere to healthcare follow-up recommendations and to explore the motivators and barriers to receiving follow up care.

METHODS: An interdisciplinary health fair was held for students who attend an alternative high school in the West Michigan area. There were 12 health topic stations including: BMI/weight, blood pressure, hearing, vision, nutrition and exercise, sleep, sexual health, dental health, stress and relaxation, smoking cessation and skin health. Flyers to students and parents were sent home including a parental consent form for those students who were under the age of 18. Following participation in the health fair, students that had been determined to have abnormal test results were asked to give their consent/assent to participate in a research study to determine the motivators and barriers to follow up health care. Students were called or emailed per their preference at 1 month and 3 months after the health fair to determine if they received follow up care. Responses were recorded and statistical analysis was preformed.

RESULTS: There were 32 students that participated in the health fair. Of those 32, there were (List how many) that had abnormal test results with seven students giving consent/assent to participate in the research study. Abnormal results included: dental carries, suspicious mole, abnormal vision exam, and high BMI. At the one month follow up, none of the participants had received the recommended follow up care. One three participants responded at this time. The reasons for not obtaining follow up care at one month included: being in jail, "being too busy", and unavailability of parents. At the three month follow up, 2 participants responded with one participant (14.3%) receiving follow up care. The motivators to receive follow up care included: having trouble with vision and parental encouragement. The reasons for not obtaining follow up care included: "family issues". There were four participants (57%) who did not respond to phone calls or emails that were sent at the one month and three month time periods.

DISCUSSION: One of the major barriers to obtaining healthcare services included family and/or personal conflicts. These young adults are in a transition stage in which they may get lost in the healthcare system. This has major nursing implications in the community setting which include: providing education of common health complications within this age group, encouraging regularly scheduled screenings to monitor for these complications, and offering secondary prevention methods to prevent further progression of these diseases. Many young adults do not have health insurance, and nurses can work to provide patients with community resources where care can be accessed.

CONCLUSION: The health fair itself was a success with the students engaged in learning about ways to promote and improve their health. Even if students did not participate in the research study, they were still given information about their abnormal test results and encouraged to follow up with their health care provider. This is a beginning step in determining barriers to obtaining healthcare in this population. Further research is needed, and further strategies to overcome these barriers needs further exploration.

MATCHING OSTEOCHONDRITIS DISSECANS LESIONS IN IDENTICAL TWIN BROTHERS: A CASE REPORT

Lucas B. Richie, Mark J. Sytsma
Western Michigan University School of Medicine, Kalamazoo, MI

BACKGROUND: Osteochondritis dissecans is a disorder of unknown etiology that can result in fragmentation of osteochondral surfaces, most commonly of the knee, shoulder, elbow, and ankle. This may lead to sequelae of pain and inability to participate in desired activities. Multiple theories exist as to the true cause of the disorder but none have been fully proven. One such proposed etiology is genetic causation. Familial cases of OCD are rare, yet these cases offer support to growing evidence that may support a genetic link.

CASE REPORT: This article describes osteochondritis dissecans lesions of the femoral trochlea in monozygotic twins. Both twins presented with similar symptoms 1 year apart, neither of which had any clear inciting trauma. MRI revealed osteochondral lesions of in very similar positions of the lateral trochlear of the same knee in both brothers. Osteochondral autograft transfer and tibial tubercle antero-medialization were performed on both patients. An identical post-op protocol was followed and recovery with full return to sport was comparable for the brothers. To the best of our knowledge there is only one other case report of OCD lesions in monozygotic twins.

CONCLUSION: While there continues to be debate regarding the true etiology of this disorder, cases of identical twins presenting with similar disease process are highly suggestive of a genetic component and may lead to early identification and treatment of these lesions. Continued research in the area of OCD and its genetic basis is needed to completely understand this disorder.

THE EFFECT OF CARPROFEN ON OSTEOGENIC DIFFERENTIATION OF MESENCHYMAL STEM CELLS

Eric M. Zellner, Debbie Reynolds, Mark C. Fuller, Jeffery C. Gandy, Lorraine M. Sordillo, Terri A. Zachos
MSU CHM, Kalamazoo, MI

INTRODUCTION: The clinical relevance of models evaluating non-steroidal anti-inflammatory drugs (NSAIDs) and bone healing has generated controversy.

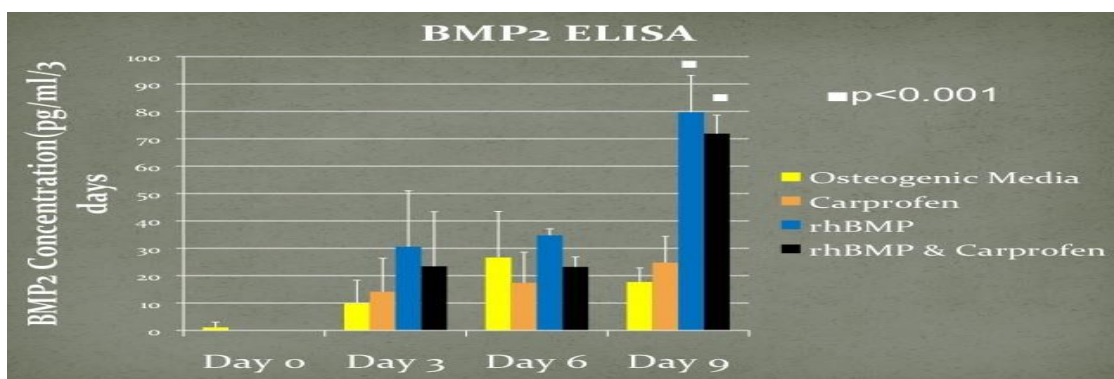
RATIONALE: We asked: (1) whether the NSAID carprofen would inhibit the osteogenic differentiation of bone marrow-derived mesenchymal stem cells (BMD-MSCs), (2) whether inhibitory effects of carprofen would manifest in impaired production clinically significant osteogenic growth factors, specifically bone morphogenetic protein 2 (BMP-2), and (3) whether the addition of recombinant human BMP-2 (rhBMP-2) would have a trophic effect on BMD-MSCs that was biologically potent enough to overcome the inhibitory effects of carprofen on osteogenic differentiation.

MATERIAL & METHODS: Canine BMD-MSCs were cultured in monolayer in four groups: 1) osteogenic medium (OM); 2) OM plus 4 µg/mL carprofen; 3) OM with 100 ng/mL rhBMP-2; 4) OM with rhBMP-2 and carprofen. Changes in gene expression and protein levels associated with osteogenesis were quantified.

RESULTS: Carprofen significantly downregulated VEGF gene expression ($p < 0.001$), but affected neither alkaline phosphatase nor BMP-2 gene expression. Carprofen significantly affected neither BMP-2 nor alkaline phosphatase protein levels.

DISCUSSION: We did not find evidence that carprofen inhibited osteogenic differentiation of canine BMD-MSCs. While we did not observe a relative reduction in the expression of genes characteristic of osteoblasts in our study, we propose potential explanations for this discrepancy. First, the addition of rhBMP-2 may have counteracted any negative effects caused by carprofen in the presence of rhBMP-2. Second, the relatively short duration of the in vitro culture time in this study (9 days) may not have been enough time for the downregulation of VEGF to affect the osteogenic differentiation of the canine BMD-MSCs or the more prolific growth and expansion of osteoblasts in culture. The results of this study did not demonstrate an inhibitory effect of carprofen on BMP2 and ALP gene expression and protein concentration. This was an unexpected finding, as these are among the most well documented proteins associated with osteogenic differentiation of BMD-MSC. Of the gene expressions and protein concentrations measured, carprofen only downregulated VEGF gene expression in the absence of rhBMP-2. Finally, our results support the hypothesis that the effects of rhBMP-2 have a trophic effect on BMD-MSC that is potent enough to overcome the inhibitory effects of carprofen on these cells in vitro, at least with regard to its effects on VEGF gene expression.

CONCLUSION: The main finding of this study is that carprofen downregulates VEGF gene expression in canine BMD-MSCs in the absence of rhBMP-2. Although NSAIDs are correlated with delayed bone healing, downregulation of VEGF gene expression was the only finding consistent with inhibition of osteogenic differentiation of BMD-MSCs. Downregulation of VEGF may account for decreased osteogenic differentiation of BMD-MSCs and may be one factor in delayed bone healing associated with NSAID therapy in vivo.



THE CURRENT QUALITY AND CONTENT OF MUSCULOSKELETAL CURRICULUM IN U.S. MEDICAL SCHOOLS

Nicole Van de Velde, Craig Smith Abby Childs, Vani Sabesan

Western Michigan University School of Medicine, Dept of Orthopaedic Surgery and Michigan State University College of Human Medicine, Kalamazoo, MI

INTRODUCTION: Although musculoskeletal conditions are among the most common in terms of disability, physician visits, and impairment, there is considerable evidence that medical students are ill-prepared in this area. This conclusion is further supported by recent studies which suggest that the discrepancy is likely the result of educational deficiencies at the medical school level.

RATIONALE: This study assesses why these educational deficiencies may be occurring by examining course quality and content.

MATERIAL & METHODS: A comprehensive list of medical schools in the US were each evaluated for the type of MSK course, length, teaching methodology, type of content, and types of assessment methods. A detailed review of each individual parameter was collected from medical school websites and the data was then verified through direct phone contact or email.

RESULTS: Of the 131 medical schools analyzed, 108 offered MSK courses (82.4%). Thirty one percent had dedicated MSK, 25% were combined with Dermatology, and 32% were a part of a combined course. Average course length was 5.5 weeks. Content format included: 74% largely lecture based, 34% included a problem based learning (PBL) component, 31% included a lab, 18.5% had web-based material, and 26% contained a clinical skills component. Assessment methods, 70% were evaluated by traditional exam, while 4.6% used quizzes, 8.3% clinical skills assessment, 6.5% a lab practical and 3.7% used Objective Structured Clinical Exam.

DISCUSSION: There is an appreciable gap between the prevalence of MSK disease in the patient population and sufficient mastery of the knowledge to manage these conditions. Much of the blame has been correctly placed on the lack of MSK education present in medical school; only 30% offer a dedicated MSK course. New formats of teaching and assessment may need to be considered in order to improve quality and competency of medical students MSK education.

CONCLUSION: While musculoskeletal education has evolved considerably over the past 50 years, there still are areas needing improvement. Regardless of how musculoskeletal education is delivered at different institutions, it is reasonable to develop a nationally endorsed, uniform musculoskeletal curricula and validated assessment of student competence. Changing medical school curricula to incorporate more effective musculoskeletal content and teaching methods will require a fundamental shift in the attitudes and a community of dedicated teaching leaders.

VSD FOLLOWING BLUNT CARDIAC TRAUMA: MRI FINDINGS

Andrew E. Liguori, Benjamin A. Maertins, & Randy Richardson

Other: St. Joseph's Hospital and Medical Center, Phoenix, AZ, Kalamazoo, MI

INTRODUCTION: Isolated VSDs represent the most common form of congenital heart disease. However, a VSD following thoracic trauma is a rare occurrence. Traumatic VSDs present in 2% to 10% of survivors of blunt chest trauma from MVAs, the most common cause of such trauma. Owing to the infrequent occurrence of traumatic VSDs as well as the associated and often overlying injuries, VSDs can initially be overlooked on radiographic imaging. Bedside transthoracic echocardiography (TTE) is the most practical tool available for early diagnosis and should be considered in all cases of blunt thoracic trauma in which cardiac injury is suspected. However, hemodynamically significant VSDs may be present despite a lack of anatomical evidence on TTE, and in such scenarios a CT angiogram and cardiac MRI (CMRI) should be considered. We describe a patient who sustained a VSD secondary to blunt thoracic trauma.

CASE REPORT: A 31 y/o male presented to the trauma center in critical condition following a motorcycle crash at a speed in excess of 100 mph. Initial cardiac troponins were 39.9 with a creatine kinase of 1128. EKG findings were consistent with a right bundle branch block. Physical exam was positive for a 3/6 holosystolic murmur heard best at the left lower sternal border. An echocardiogram was performed demonstrating moderate tricuspid regurgitation with no evidence of intracardiac shunt, though the sensitivity was reduced owing to the patient's wounds and bandages. A complete echo with Doppler flow was performed again 10 days later showing right ventricular enlargement with moderately severe pulmonary HTN and tricuspid regurgitation. A chest CTA was done 11 days later demonstrating a pericardial effusion with no mention of VSD. An additional echo with bubble study was performed 5 days later with still no comment of a VSD. The patient was noted to have a louder murmur. A CMRI was then ordered demonstrating an intramuscular type VSD secondary to infarction vs. rupture. Additionally, there was papillary muscle elongation at the site of injury to the septum causing poor function of the tricuspid valve septal leaflet and significant regurgitation. The patient was managed conservatively, and elective surgery was performed 2.5 months later.

DISCUSSION: There are two proposed mechanisms for VSD following trauma: early mechanical rupture or delayed inflammatory rupture. Mechanical septal rupture is thought to occur as the heart is compressed during late diastole when the ventricles are filled and the valves are closed. Rupture may occur as a result of direct cardiac impact or when the heart is compressed between the sternum and the spine. Delayed inflammatory rupture is thought to occur when cardiac injury causes localized edema with disruption of microvascular flow leading to infarction, septal liquefaction, and perforation. Reports show that VSD can appear days to months later.

CONCLUSION: When the signs and symptoms are suggestive of cardiac injury, and echo is unrevealing, CMRI may be of substantial benefit. Fortunately, late discovery of VSD rarely requires emergency surgery and often is repaired electively. MRI has a sensitivity of more than 90% for detection of ventricular septal defects. We demonstrated this effectiveness in a patient with clinical instability and normal echocardiograms.

A SURVEY OF SIMULATION FELLOWSHIP PROGRAMS

Eric Kotal, Ryan Sivertson, Scott Wolf, Richard Lammers, David Overton
Western Michigan University School of Medicine, Kalamazoo, MI

BACKGROUND: The use of simulation technology in medical education has expanded in recent years, with simulation playing an increasing role in both GME and UGME curricula. Many institutions are now specifically seeking faculty members with specialized knowledge in simulation education to participate in and lead their simulation programs. To this end, specialized educational programs (“simulation fellowships”) have emerged to teach aspiring faculty members the basis of medical simulation educational technology. Given Western Michigan University School of Medicine’s curricular emphasis on simulation education, it is well-poised to consider the development of such a simulation fellowship program. However, the nature and characteristics of these fellowship programs is not well known, and no comprehensive review exists in the literature.

OBJECTIVE: To determine the nature and characteristics of existing Simulation Fellowship programs in the United States.

METHODS: We sought to locate all existing US postgraduate educational training programs in medical simulation. Since such programs are not accredited via the ACGME, programs were located via available public means, such as web pages, mailed flyers, and advertisements. Although we primarily sought only fellowships at the postgraduate medical education level, we also included interdisciplinary programs that were open to other health care professionals, such as nurses, mid-level providers, and others. Data elements regarding each program were determined from these existing public sources, and descriptive statistical analysis was performed. Data provided as ranges were averaged in order to perform statistical analysis. A future survey of fellowship programs is planned to obtain data unobtainable in this literature search.

RESULTS: Sixteen programs that met inclusion criteria were identified. Not all data elements were publicly available from all programs. Sponsoring Academic Unit: Fourteen programs had data available. The most common sponsoring unit was emergency medicine (8 of 14, or 57%). One fellowship (7%) was based within a division of pediatric emergency medicine, while three programs (21%) were based in multiple departments, or were housed in interdisciplinary departments. Eligibility: Seven programs (54% of 13 available programs) were open only to graduates of emergency medicine residencies, while one was open only to pediatric emergency medicine graduates. Four (31%) were open to physician graduates of multiple medical specialties. Only one was open to both physicians and other health care professionals. Required Clinical Service: Eight programs had data available. Seven (88%) indicated that fellows were required to work clinically in their underlying clinical discipline as part of the fellowship. The required number of hours ranged from 16-20 (average of 19) hours per week. Only one program did not require clinical service as part of the fellowship. Several indicated that this clinical service provided financial support to the fellowship. Program Length: Fourteen programs had data available. Five programs (36%) were one year in length, and three programs (21%) were two years in length. Five additional programs (36%) were either one or two years in length, where the two year option involved obtaining a graduate degree or certificate. A wide variety of potential graduate degrees or certificate options were reported.

CONCLUSIONS: Sixteen simulation fellowships currently exist in the United States. All vary between one and two years in length. Most are sponsored by departments of emergency medicine or pediatric emergency medicine, and most accept only emergency medicine or pediatric emergency medicine graduates. The vast majority require their fellows to provide clinical service. Given that only a minority of simulation fellowship programs offer training to non-emergency physicians and non-physicians, a program that targets these groups may serve a relatively unmet need, and provide an opportunity as WMed considers development of such a fellowship program.

INTERVIEWER INTRA-RATER RELIABILITY OF MORNING AND AFTERNOON RESIDENCY INTERVIEWS

Cara Hollmer, Tyler Johnson, Philip Pazderka, David Overton
Western Michigan University School of Medicine, Emergency Medicine, Kalamazoo, MI, MI

BACKGROUND: It has been shown that conducting more interviews in one day give a better picture of the candidate. However, the effect of doing multiple interviews in a single day on the interviewer has not been well documented.

OBJECTIVE: The objective of this study was to determine the intra-rater reliability of interviewers scoring residency applicants when conducting both morning and afternoon Interviews.

METHODS: A retrospective study of data obtained during the 2011-2012 residency interview season was performed. The residency program interviewed 193 applicants. Each applicant underwent three interviews. These interviews were conducted by three teams: team 1 (one faculty interviewer), team 2 (one faculty interviewer) and team 3 (two resident interviewers). Approximately half the applicants were interviewed in the morning and half in the afternoon, and all three of each applicant's interviews occurred in the same half day session. Each interviewer was responsible for scoring each candidate on a scale of 0-5. A linear mixed model was used to analyze the data, taking into account the correlation between the three teams' rating on a single applicant. A test for interaction between teams and time (morning or afternoon) was first conducted. If the interaction was significant, the morning and afternoon difference was evaluated per group. All statistical tests were evaluated at $\alpha = 0.05$. SAS 9.2 was used for statistical calculations.

RESULTS: The difference between scores for morning and afternoon interviews for all teams was significant ($p = 0.0092$). Although there was no significant difference found between the scoring of applicants in the morning or afternoon by team 2 or team 3 individually, there was a statistically significant difference found in the ratings given by team 1. A comparison of morning and afternoon scores on team 1 revealed a mean morning score of 1.97 and a mean afternoon score of 1.56 ($p=0.0043$).

CONCLUSION: This study found that scores given to applicants who interviewed in the afternoon were overall lower than those given to applicants interviewing in the morning. Interviewer fatigue may play a factor. This difference may ultimately affect applicants' overall score, position on rank lists, and potentially the likelihood of matching into the program. Programs are advised to monitor interviewers' intra-rater reliability to ensure the most consistent scoring of applicants.

MEDICAL RESIDENTS' KNOWLEDGE OF THE COST OF LABORATORY TESTING AT BASELINE AND AFTER AN INTERVENTION.

Joanne K. Baker, D.O., Tracey L. Mersfelder, PharmD
Western Michigan University School of Medicine, Internal Medicine, Kalamazoo, MI

OBJECTIVE: To determine the baseline knowledge of medical residents concerning the cost of laboratory data and whether providing a half-hour inservice improves their knowledge.

METHODS: All medical residents in the internal medicine, medicine-pediatrics, family medicine, and transitional medicine programs at one teaching institution were included. A survey was conducted that consisted of eight questions. A case-based inservice was provided. Approximately three weeks following the inservice, a follow-up survey was conducted. The study was approved by the safety board and IRB.

RESULTS: Fifty-eight residents completed the pre-survey and 41 the follow-up survey. On average, questions were answered correctly 38% of the time (0% to 79%). There was no difference in scores in relation to the residents' year of training. Ninety-three percent of the residents stated they had no formal education in the cost of laboratory tests prior to participating in this study. Generalized estimating equations were used to test for improvements after the inservice. Overall, there was no statistically-significant difference in test scores before/after the intervention ($p = 0.0612$). Independently, three questions showed statistical improvement. These questions were regarding the cost of basic metabolic panels and complete blood counts (p -values: 0.0169, 0.0442, 0.0068). Three questions that did not show statistical improvement addressed the cost of liver function tests and medication levels. Overall, the inservices were well received with 87.5% of residents stating that it was valuable and 94% stating it should be repeated yearly to every three years.

DISCUSSION: This is the first study that looked at the medical residents' baseline knowledge of the cost of laboratory tests with follow-up to see if a half-hour inservice would improve their knowledge. Even though the results are not statically significant, there are a few points to make. First, these residents had previously received no formal training in the cost of laboratory testing and their baseline knowledge was low. Second, there were some positive trends in the data. More questions need to be asked to fully assess the knowledge gained from the inservice. Lastly, the residents valued the education that they received.

CONCLUSION: Residents' knowledge of the cost of laboratory testing can be improved. A half-hour case-based inservice was not sufficient to impact all areas of deficiency in knowledge. Additional ways to increase the residents' knowledge of the cost of laboratory monitoring need to be explored.

USE OF INTRANASAL INFLUENZA VACCINE IN PEDIATRIC INPATIENTS

Richard A. Van Enk, Aaron Lane-Davies, Neelakanta Kanike, Rushabh Shah, and Mary Woodhouse
Bronson Methodist Hospital, Departments of Infection Prevention and Epidemiology and Pediatrics ,
Kalamazoo, MI

INTRODUCTION: Inpatient encounters can be opportunities for immunizing susceptible patients during the influenza season. Hospitals should immunize susceptible pediatric inpatients. Most hospitals that immunize inpatients use only injectable vaccine. Live intranasal influenza vaccine is becoming the preferred influenza vaccine for children because it is effective and avoids an intramuscular injection. We gave eligible pediatric inpatients a choice of intranasal or injectable influenza vaccine during the 2011-12 season to determine if it was feasible to use live intranasal vaccine in an inpatient pediatric setting.

RATIONALE: Intranasal influenza vaccine has superior efficacy compared to intramuscular vaccine in patients under 18 years old, it is the preferred route of delivery for pediatric patients and their caregivers, and it is safe to administer in an inpatient setting if the published warnings and contraindications are observed. No published studies describe the use of live intranasal vaccine in pediatric inpatients. We conducted a trial of live intranasal influenza vaccine in pediatric inpatients, accompanied by surveys of the patients or their caregivers and of the nurses and physicians who discussed the vaccines with the patients and administered both vaccines to determine if there was demand for the product and if there were unanticipated consequences or problems associated with the use of live intranasal vaccine in a pediatric inpatient unit.

MATERIAL & METHODS: All patients admitted to the Pediatric and Pediatric Intensive Care Units were screened for eligibility for influenza immunization. Eligible patients with documented contraindications or warnings for the intranasal vaccine and not the injectable vaccine were offered only the injectable product, all others were given the choice of products. Patients or their caregivers were asked to complete a survey following their immunization. Nurses and physicians who explained or gave immunizations completed a survey at the end of the season to determine their opinions on the feasibility of offering both vaccines.

RESULTS: Of 113 vaccine doses given to children between 2 and 17 years of age on the pediatric units during the study period, 65 were injectable and 48 were intranasal. Surveys were completed by 16 patients or caregivers, 14 of whom were immunized, 12 of whom received intranasal vaccine and 2 received injectable vaccine. All patients indicated that they understood both vaccines, none reported any side effects, and 15 of 16 felt that both vaccines should be offered in the future. Most of the 28 staff respondents gave both vaccines, all staff either preferred giving the intranasal vaccine (14) or had no preference (2); and no staff preferred giving the injectable vaccine. All but one staff respondent wanted to continue offering the intranasal vaccine.

DISCUSSION: Patients and staff overwhelmingly preferred the live intranasal vaccine to injectable influenza vaccine. There were no concerns regarding safety or efficacy of the live vaccine. Most patients or their caregivers indicated that the child normally received the live vaccine from their regular providers and were familiar with it, so they appreciated the chance to have it in the inpatient stay. Children with active asthma were excluded from receiving live vaccine, and those patients were easily identified and offered the injectable product. No child with a contraindication received live vaccine. The nurses who administered the live intranasal vaccine easily acquired the required skill by watching the training video for the product, and there were no reported problems in administration.

CONCLUSION: Intranasal influenza vaccine is an attractive option for pediatric inpatients who are eligible for it, patients and staff prefer the intranasal route, and there were no problems or disadvantages to offering the intranasal product as a choice.

HEADACHES IN A FIFTEEN YEAR OLD FEMALE: A CASE REPORT

Nilam Patel, Angela Hanson, Colleen Dodich
Western Michigan University School of Medicine, Kalamazoo, Michigan

OBJECTIVE: To understand that headaches in a teenager with a history of trauma can be an atypical presentation of a serious underlying illness.

INTRODUCTION: Headache is a relatively common complaint in adolescents, the etiology of which can range from benign to serious. The vast majority of adolescents with headaches do not have a serious disease. In this unique case, the patient presented to our facility with a history of hypertension and migraine headaches, and further evaluation of her worsening headaches and neck pain led to the diagnosis of a life threatening disease. This case is presented because it is an example of how headaches in the adolescent population can be an atypical presentation of a devastating disease.

CASE PRESENTATION: A 15 year old female presented to the outpatient clinic multiple times for headaches. During the initial office visit, discomfort was described as throbbing and was located in the occipital region and neck. Symptoms had started two days prior and didn't respond to various analgesics which the patient received from a recent ER visit. Patient also had a history of hypertension for which she was on Lisinopril, although it was discovered during the first clinic visit that she had been non-compliant with her medication regimen. It was felt that her headaches were likely due to uncontrolled hypertension, thus Lisinopril was increased and patient was sent home to follow-up in two weeks. At the follow-up appointment patient was still experiencing headaches, with reported compliance with Lisinopril. Physical exam was unremarkable during all visits. Given her persistent symptoms, imaging was done. MRI and MRA of brain and cervical spine showed an intimal tear and dissection of the left internal carotid artery. On subsequent CTA, patient was found to have a stable left internal carotid artery dissection (CAD) without pseudoaneurysm formation. The left carotid artery was approximately 50% occluded with adequate blood flow to the brain. Patient was started on a Heparin drip and then transferred to the Pediatric Intensive Care Unit (PICU). During her hospitalization, patient reported a history of a cousin putting her in a "head lock" position during rough play. In the PICU, per the pediatric neurologists recommendations, the Heparin drip was discontinued and patient was started on Aspirin 81 mg daily and Plavix 75 mg twice daily. Pain control was achieved with Flexeril, and patient was discharged home in stable condition.

DISCUSSION AND CONCLUSION: Most adolescents who present with headaches in the ER or outpatient setting are diagnosed with benign conditions such as migraine, tension or cluster headaches or caffeine withdrawal. Others may present with acute conditions such as trauma related concussions. A very small percentage of those who will be diagnosed with conditions such as leukemia, metastatic malignancies, or CAD. Our patient's initial diagnosis of migraine headaches vs. uncontrolled hypertension was a likely possibility, but due to the persistent nature of the headaches after treatment, the threshold for further work up was very low. The reported history of a "head lock" during rough play seems to be the most likely cause of this patient's CAD. A community based study estimated the annual incidence of spontaneous internal carotid artery dissection to be 2.6/100,000 for all ages and 3.5/100,000 for ages 20 and older. It is likely that we underestimate the true incidence of this condition, as many are asymptomatic. The presenting symptoms vary depending on the location and vessel involved and can range from non-specific headaches to major neurological deficits; thus causing a delay in the diagnosis. The condition may be asymptomatic, or result in stroke or death. As described in the literature, minor trauma to the neck may also lead to CAD and, although rare, should be considered given the history. A retrospective study has raised the concern that treatment with unfractionated heparin may promote an increase in the extent of intramural hematoma with either transient or persistent delayed occlusion in patients with extracranial carotid dissection; therefore antiplatelet therapy is preferred. It is important for providers to review the diagnosis and correct management plan before starting treatment, as the patient was inappropriately treated with heparin initially. Given the rarity of CAD in children, this case sheds light on the importance of having a high index of suspicion for CAD, especially when there is a history of trauma related to the headaches and neck pain.

AUTOIMMUNE HEPATITIS TYPE 2 - A RARE DISEASE

Danielle G. Hirsch, Angela J. Hanson, Megan E.F. Sikkema, Colette A. Gushurst
Western Michigan University School of Medicine, Kalamazoo, MI

INTRODUCTION: Autoimmune hepatitis (AIH) is a rare chronic and progressive inflammatory liver disease in children and adults. There are two major types of AIH. Type 1 is defined by detection of anti-nuclear antibodies (ANA), anti-smooth muscle antibodies (SMA) while Type 2 is defined by detecting liver-kidney microsomal auto antibodies (LKM1) and/or liver cytosol 1 antigen (LC1) autoantibodies on liver biopsy. Type 1 has two peaks: adolescence and adulthood and is relatively benign. Type 2 occurs in infancy and is more severe. The presentation of this disorder in young children can be subtle and insidious and if left untreated can progress to liver cirrhosis and a need for transplant. We present a case of AIH type 2 whose fussiness and vomiting lead to the discovery of unexpected abnormal liver function tests.

CASE REPORT: A previously healthy 18-month-old female presented to clinic for a well child exam. At the visit mom relayed that the patient had a two-week history of nightly fits of screaming for 20 minutes without a known cause and not relieved with ibuprofen. These were interpreted to be night terrors. Two days later the patient returned to clinic after acute onset of 10 episodes of non-bloody emesis, persistent irritability and refusal to lie in a supine position. Mother complained of pink urine but normal urine output and no fevers. The combination of irritability, vomiting, and pink urine lead to a concern for toxic ingestion or non-accidental trauma. A non-catheterized urine specimen was negative for drugs or blood or bilirubin but positive for trace leukocytes and bacteria. A head CT was negative for bleeding, masses, or other abnormalities but liver enzymes were elevated (ALT 1660 u/l; AST 2153 u/l) and bilirubin was 3.3 mg/dL despite a lack of clinical jaundice. Test results that were within normal limits included: CMV IgM, EVB titer and hepatitis. Abdominal CT showed edema in the gallbladder fossa and periportal region; a liver biopsy demonstrated diffuse, extensive, lobular inflammatory activity with numerous necrotic hepatocytes accompanied by neutrophilic satellitosis and positive for liver-kidney microsomal antibody. A diagnosis of autoimmune hepatitis type 2 was made and the patient began on prednisolone and ursidol. Her liver enzymes subsequently normalized. A thiopurine methyltransferase level was obtained to determine if the patient could be started on azathioprine, but was found to be very low and thus, was started on mycophenolate as an alternative.

DISCUSSION: The etiology of AIH is unknown although genetic and environmental factors may be involved in expression. Reported prevalence in the US is 1 per 200,000. Anti-LKM associated liver disease is a distinct subgroup of autoimmune diseases in children. The onset of this disease is usually uncharacteristic and can begin without symptoms and evolve in two phases: early phase/early evolution and late phase. Early phase can present with very aggressive histology and early evolution with cirrhosis and progression to atrophy of the liver. Late phase is characterized by cirrhosis with varying degrees of inflammation but no major aggressive histology. There is a need for early immunosuppressive treatment regardless of the duration of disease because the patient can present from fulminate hepatic failure to asymptomatic hepatomegaly thus this disease should be evaluated in the scenario of acute symptoms with no other obvious cause. If AIH remains untreated it will progress to liver cirrhosis and liver failure is inevitable.

CONCLUSION: It was fortuitous that the diagnosis was made promptly in this patient although retrospectively there was some growth deceleration in the months preceding her diagnosis. The standard treatment is a combination of prednisone and azathioprine but if azathioprine intolerance is suspected then cyclosporine can be used. Some children will show regression of cirrhosis or resolution of fibrosis on treatment, others will need low dose prednisone indefinitely, and few require liver transplant. This patient has had normalization of liver function with her current suppressive therapy but there are several long-term concerns in these patients. If transplant is needed there is a high rate of disease recurrence and in those that never need transplantation there a risk of developing hepatocellular carcinoma. Strategies for optimal surveillance are still problematic.

GLUCOSE TRANSPORTER TYPE 1 DEFICIENCY SYNDROME: HISTORY AND DIAGNOSIS IN A 6-MONTH-OLD MALE

Shazia Malik, Todd Anderson, Faiza Wajid, Amaan Haq, Robert Baker
Western Michigan University School of Medicine, Family Medicine, Kalamazoo, MI

INTRODUCTION: Glucose transporter type 1 deficiency syndrome (GLUT1DS) results in a loss of functional glucose transporters, encoded by GLUT-1. This protein mediates glucose transport across the blood-brain barrier. Though rare, this can lead to in an epileptic encephalopathy, characterized by infantile seizures, developmental delay, and a complex movement disorder in association with a reduced cerebrospinal fluid glucose concentration. The appropriate diagnosis is important because patients respond better to a ketogenic diet, compared to more commonly use anti-seizure medications.

CASE REPORT: A 6-months old Caucasian male, with history of multiple hospitalizations secondary to recurrent seizures. He was born at 37 weeks estimated gestational age via cesarean section due to cephalopelvic disproportion. Family history did not reveal consanguinity or history of neurological conditions. Initial developmental milestones were normal. At 10 weeks of age, mother observed that the child had rhythmic left eye twitching occurring infrequently, thought due to tear duct blockage. At 3 1/2 months of age, episodes of periodic right arm stiffening, head drops and drooling developed, lasting for 90 seconds along with initial left eye twitches. He was lethargic after the episodes. These episodes were initially infrequent, then they started to occur in clusters several times per week. His initial diagnostic work-up included computed tomography (CT) of the brain, free fatty acid profile, amino acid profile, array-comparative genomic hybridization, which were all normal. MRI of the brain was unremarkable for any structural abnormality. An EEG showed focal abnormality in the right frontal region. Then phenobarbital was initiated for management of recurrent focal seizures. Later levetiracetam was started, as patient was not able to tolerate phenobarbital. He had significant motor developmental delay starting at 4 months of age, as he could not roll over and started to have a poor head control. At age 6 months, episodes of full tonic body rigidity and random eye movements developed, lasting for 2 minutes. These events were accompanied with intermittent perioral cyanosis, drooling and hypotonia. Further occult neuroblastoma was ruled out by an abdomen ultrasound. Repeated EEG demonstrated epileptiform discharges. A lumbar puncture revealed a decreased CSF glucose of 32 mg/dl, low CSF-serum glucose ratio (0.30) and a low CSF lactate level of 0.3mmol/L. This finding was confirmed by genetic testing, by which a pathogenic mutation of the SLC2A1 gene was found. A likely diagnosis of glucose 1 transporter (GLUT-1) deficiency was then considered and the patient was initiated on a ketogenic diet along with levetiracetam and lacosamide. Patient remained seizure free and found to be more alert with significant improvements in neurological symptoms on ketogenic diet. Attempts to wean him off levetiracetam were unsuccessful.

CONCLUSION: Children with unexplained epilepsy and/or a complex movement disorder with or without developmental delay should be evaluated to exclude hypoglycorrhachia. Though rare, GLUT1DS may be responsible for these symptoms. In these patients, barbiturates, such as Phenobarbital should be avoided as they are inhibitors of glucose transporter-1 function.

HYDRONEPHROSIS CAUSED BY SICKLE CELL DISEASE VASO-OCCLUSIVE CRISIS

Usman Saeed, Megan Brown
Western Michigan University School of Medicine, Kalamazoo, MI

INTRODUCTION: Hydronephrosis in pediatric patients is usually caused by obstruction in urine flow due to tumors, congenital or anatomic abnormalities or vesico-ureteral reflux. Hydronephrosis due to blood clots is usually caused by invasive urologic procedures. We report a case of hydronephrosis following hematuria in a patient with sickle cell vaso-occlusive crisis

CASE REPORT: 12 year old African American male with sickle cell disease of moderate severity presented with frank hematuria, right flank and suprapubic pain for last 2 days. He also reported increased urinary frequency and pain after micturition. He also passed a few clots upto 2 inches long. Right flank pain was 7/10 in intensity, cramping in nature. He denied any nausea, vomiting or fevers. He has history of sickle cell disease of moderate severity and was on hydroxyurea. He also has PMH of migraine headaches, cholelithiasis, pneumonia, multiple admissions for sickle cell painful crisis and multiple blood transfusions. On exam there was tenderness in the right flank and suprapubic area on deep palpation. His Hb at the time of admission was 7.8g/dL with a baseline Hb of around 9g/dL. U/A revealed large amount of blood but no evidence of infection. He was admitted on inpatient pediatric Heme-Onc service and was started on IV fluids and IV and oral narcotics for pain control. Renal US showed right ureteral obstruction due to heterogeneously echogenic material and grade 2 hydronephrosis. Urology was consulted, CT urogram was ordered and surgical intervention was planned for the next day. CT urogram revealed resolution of the right ureteral filling defect found on ultrasound but showed bilateral moderate bilateral hydroureteronephrosis is presumably due to distention of the urinary bladder which resolved with placement of Foleys catheter. The pt was discharged home with Foleys catheter and followed up with urology as outpatient. The Foleys catheter was removed a few days later without problems and f/u USG of the urinary tract was normal.

DISCUSSION: Sickle cell disease is the most common inherited blood disorder in US. 8% African American are carriers and 1 in 500 have sickle cell disease. Signs of disease can start during first year of life usually around 5 months of age. when the fetal hemoglobin is replaced by adult hemoglobin. Common complications are chronic anemia, recurrent painful crisis, acute chest syndrome, hand-foot syndrome, increased susceptibility to infections, splenic sequestration, visual impairment, lower extremity ulcers and increased risk of stroke. Genitourinary complications of sickle cell disease include UTI, hematuria, priapism and eventual renal failure and impotence.

CONCLUSION: Early recognition and improved treatment of sickle cell disease and its complications including genitourinary complications can decrease the morbidity and mortality.

CHEILITIS GRANULOMATOSA

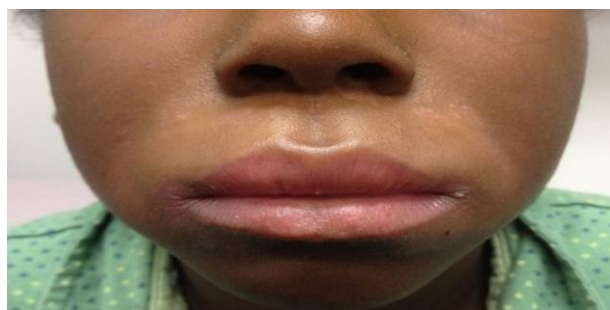Neelakanta Kanike, Rushabh Shah, Mary Moore
Western Michigan University School of Medicine, Kalamazoo, MI

INTRODUCTION: Cheilitis Granulomatosa is a rare inflammatory disorder of unknown etiology. It produces nontender, persistent swelling of one or both lips and affects primarily young adults and adolescents. Histologically, non-necrotizing granulomatous inflammation is seen on lip biopsy. Here, we report a case of Cheilitis Granulomatosa in an adolescent. We have also reviewed medical literature on this relatively rare condition.

CASE REPORT: 8 year old African-American female, referred to pediatric rheumatology clinic by her primary physician for upper lip swelling for 4 months. Initially, swelling was intermittent, but became persistent in the last 2 months. Patient also had peeling of skin over lips and her tongue gets dry. Patient also noticed fissuring of her tongue. Patient denies any pain or itching over swelling. Patient was referred to allergist in the past and was treated with two courses of corticosteroids and antihistamines with not much of an improvement. On physical exam, patient has diffuse swelling of upper lip with mild hypopigmentation of the surrounding skin and dry tongue with prominent fissures. There are several scattered scaly nodular skin lesions over palms and soles. There is mild swelling and hyperpigmentation over PIP joints. Previous laboratory studies including angioedema panel (C4, C2, C1Q, C1 inhibitor, C4D, C3C, CH50), thyroid studies were normal. Rheumatoid factor was negative; ESR and IgE levels were normal. Subsequently, the patient was referred to a dermatologist and was diagnosed clinically with Cheilitis granulomatosa and was started on topical Tacrolimus. The dermatologist and parents have decided to put lip biopsy on hold, considering the invasive nature of the procedure. Improvement of lip swelling was noticed with treatment.

DISCUSSION: Cheilitis granulomatosa is a recurrent, chronic swelling of lip due to granulomatous inflammation. Etiology is unknown, various theories were proposed. This condition is usually seen in adolescents and young adults. Lip swelling is typically recurrent, chronic and painless. First attack of edema/swelling usually subsides completely. After recurrent attacks, swelling may persist and slowly increases and eventually become permanent. 20-40% of patients with this condition also have fissured or plicated tongue, mainly because of decreased salivary secretions. They may have lost taste sensations. Morbidity related to the disease depends on whether an underlying organic disease, such as Crohn's disease or sarcoidosis, is present. Diagnosis is usually confirmed by lip biopsy, which shows nonspecific lymphoedema and perivascular lymphocytic infiltration during early phases and later shows granulomas. If suspecting Crohn's disease, further evaluation needs to be done. In some cases, this condition may improve with implementation of cinnamon and benzoate-free diet. Multiple agents have been tried for this condition, topical/intralesional steroids, topical tacrolimus, mast cell stabilizers etc. Reduction Cheiloplasty with intralesional triamcinolone and systemic tetracycline offers best results. Miescher Cheilitis is the term often used in literature when the granulomatous changes are confined to the lip. Melkersson-Rosenthal Syndrome is the term used when cheilitis occurs with facial palsy and plicated tongue; often associated with Crohn's disease.

CONCLUSION: We report a case of a Chelitis Granulomatosa presenting as angioedema. Furthermore studies need to be done to know about the etiology, pathogenesis, prognosis, complications and effective treatment of this rare disease.



PHARMACOKINETICS IN MORBIDLY OBESE PATIENTS IN ICU: A CASE REPORT

Ravikanth Papani MD, Sangeeth Dubbireddi MD, Erasmo Ruggeiro MD

Western Michigan University School of Medicine, Department of Internal Medicine, Kalamazoo, Michigan

INTRODUCTION: Managing morbidly obese patients in the ICU is a challenging situation and most of the available treatments may need to be tailored for these overweight patients. Especially when it comes to medications, we generally use fixed doses all the time which may not work for obese patients.

CASE REPORT: We present a 64 year old Caucasian lady who is morbidly obese with a BMI of 54 and other past medical history significant for multiple medical conditions including chronic Hepatitis C and Cirrhosis of Liver. On admission, patient had urinary tract infection with urine and blood cultures positive for E. Coli. She was in septic shock with failed resuscitation with 3-4L of crystalloids and was started on IV Levophed. In the initial 12 hours the patient was very hypotensive and we had to increase her Levophed dose to 90mics/min, in contrast to the conventional dose of 30mics/min. Apart from IV Vasopressin and stress dose steroids, patient was on this high dose Levophed for about 12 hours to maintain blood pressure. Over the next week, patient slowly recovered and eventually discharged in a stable condition, without any side effects like peripheral or splanchnic ischemia from high doses of Levophed.

DISCUSSION: Obesity is a fast growing health problem in adult, adolescent and child populations throughout the world. Apart from its effects on the different organ systems in the body, obesity also affects the pharmacokinetics of medications inside the human body. For example the Volume of distribution of one drug, which determines the loading dose, is altered in obese patients. This is because of a reduction in tissue blood flow from vascular dysfunction and alterations in cardiac structure and function in obese patients. And drug Clearance, which determines the maintenance dose of one drug, is also altered in obesity. This is because of an increased cytochrome P450 2E1 activity and phase II conjugation activity in the drug metabolism. Recent publications investigated the disposition of several classes of drugs in the obese patients, but still a thorough pharmacokinetic data does not exist for majority of drugs and there are no specific studies in ICU setting. Our patient maintained blood pressure with very high doses of Levophed which are usually thought ineffective and/or sometimes detrimental in general population.

CONCLUSION: When treating an obese patient in the ICU, these pharmacokinetic issues should be recognized soon and the doses of medications need to be adjusted accordingly, especially that of lifesaving medications like vasopressors, antiepileptics etc. A more thorough research is required to come up with an appropriate metric for measuring loading & maintenance doses of all the medications in morbidly obese patients.

REQUIP FOR A DREAM! A CASE OF VIVID HALLUCINATIONS SECONDARY TO ROPINIROLE

Sonia Motin, Paul D. Harcourt, Sara L. Galdys, Tracey L. Mersfelder, Lorenzo Zaffiri
Western Michigan University School of Medicine and Ferris State University, College of Pharmacy,
Kalamazoo, MI

INTRODUCTION: Ropinirole is a dopamine 2/3 agonist that was approved for restless leg syndrome (RLS) in 2005. Adverse events such as nausea, vomiting, somnolence, and dizziness were reported in over 5% of patients. More concerning are the psychiatric side effects such as confusion and hallucinations have been described in patients with advanced Parkinson's disease. We report a case of rapidly progressive perceptual distortion associated with vivid hallucinations that resolved with discontinuation of ropinirole.

CASE REPORT: A 70-year-old female presented to the hospital with a chief complaint of altered mental status and hallucinations. Her medical history was significant for diabetes mellitus type 2, frequent urinary tract infections (UTI), vascular dementia, depression and RLS. In the last three years her mental status began to gradually deteriorate. Correlating with this timeframe, she began taking ropinirole 2 mg at bedtime in October 2009 for RLS with good compliance. On admission, she was found to have a UTI and bizarre behavior characterized by vivid hallucinations. Ciprofloxacin was initiated for treatment of the UTI. All central nervous system depressant drugs including ropinirole were discontinued. A rapid improvement of clinical condition and disappearance of hallucinations were noted after the second day of hospitalization. However, ropinirole was then restarted based upon the patient's request during the third night of hospitalization for her RLS symptoms. The following evening hallucinations and psychotic symptoms returned. Ropinirole was again discontinued and within 24 hours the hallucinations resolved. Moreover, the patient's mental status significantly improved following the addition of quetiapine, a dopamine antagonist.

DISCUSSION: Ropinirole is a dopamine agonist frequently used to improve symptoms of RLS at night. Despite several case reports describing hallucinations with ropinirole use, a recent meta-analysis of safety and tolerability of ropinirole use in RLS did not suggest hallucinations as a potential adverse effect. However, a meta-analysis in Parkinson's patients reported a relative risk of hallucinations to be 2.84. Upon admission the patient's symptoms were significant and could have been accentuated by the presence of the UTI and the concurrent use of ciprofloxacin, which increases the serum concentration of ropinirole. We believed that ropinirole caused vivid hallucinations and progressive deterioration of the patient's mental status. The results of the Naranjo adverse drug reaction probability scale related this case of hallucinations as "probable" and a second challenge with ropinirole supports our hypothesis. In addition, treatment with quetiapine, a dopamine antagonist, induced a significant improvement in the patient's sensorium.

CONCLUSION: This case highlights the risk of vivid hallucinations with the use of ropinirole in patients not affected by Parkinson's disease.

FACTORS ASSOCIATED WITH IMPROVEMENT OF DEPRESSION AMONG PERIPARTUM WOMEN UNDER PSYCHIATRIC CARE

Katie Q. Yang, Ruqiya S. Tareen, Michael R. Liepman, Catherine L. Kothari, Remitha M. Charoth, Kathleen A. Gross,
Benedict P. Dormitorio

Western Michigan University School of Medicine, Department of Psychiatry, Kalamazoo, MI

INTRODUCTION: Many biological, psychological and social factors play an etiological role in peripartum depression and may also interfere with treatment. Women being treated for perinatal mood disorders vary in their responses to psychotherapeutic interventions.

RATIONALE: Psychosocial states and traits and treatment variables may play a role in outcomes of psychiatric treatment for perinatal mood disorders. We hoped to identify variables contributing to improvement or resistance to treatment among peripartum women who were treated for mood disorders in the Women's Behavioral Health Clinic.

MATERIAL & METHODS: This was a pre-post, single-group study. Data was collected through retrospective record review of the psychiatric records of 57 women treated for perinatal depression. The patients were pregnant or postpartum at the time of intake. The primary outcome, depression, was measured using the Edinburgh Postnatal Depression Scale (EPDS), a validated screener for perinatal depression. The final EPDS versus the change in EPDS score from baseline was graphed on a scatter plot and two clusters were identified visually. One cluster, showing a large change in EPDS and low final EPDS, was designated "Improved" (N=22) and the other cluster, with little change in EPDS and high final EPDS, was designated "Unimproved" (N=35). Depression improvement ("Improved" or "Unimproved") was modeled using the following predictors: insurance status, age, number of visits, planned pregnancy, cohabitation, social stressors, comorbid substance abuse, number of comorbid Axis I diagnoses, presence of comorbid Axis II diagnoses, and history of experiences of psychic trauma. Multiple linear regression (MLR) was used to model the data with $\alpha=0.05$. Type III sum of squares was used to assess the significance of a specific variable to the change in EPDS score while adjusting for the rest of the independent variables. Interdependence of the variables was examined using linear regression, t-tests, and chi-square tests.

RESULTS: Factors that impacted treatment response included the initial EPDS score and the type of insurance: 1) The difference in change in EPDS scores between the Improved (14.8) and Unimproved (3.4) groups was significant ($p<0.0001$); 2) The initial EPDS score did not significantly interact with any of the other variables; 3) The initial EPDS score predicted future changes in EPDS score ($p<0.0001$). Among the population treated in the clinic, the mean reduction in EPDS score was 50%; 4) The Improved and Unimproved groups were not equally distributed among the two insurance types ($p=0.0005$). Patients with private insurance had, on average, 3.95 points more reduction in EPDS score than those with Medicare, Medicaid, or no insurance; 5) The variables: unplanned pregnancy, young age, history of psychological trauma, and living alone all significantly interacted with government or no insurance (poverty); 6) With age, insurance type and improvement group variables removed from the model, unplanned pregnancy surfaced as a significant predictor of poor treatment outcome ($p<0.01$), accounting for a mean of 6 less EPDS points of change. Of the improved group 68% and of the unimproved group 87% had unplanned pregnancies, and women with unplanned pregnancies were 1.6 times more likely to present for care in our clinic; 7) There was a non-significant trend between patient's age and change in EPDS score ($p=0.09$) indicating less change in younger patients; 8) The average number of visits among all patients ($n=57$) was 6; 88% of patients did not exceed 10 visits.

DISCUSSION: Most of the women with perinatal mood disorders in this study received a brief psychiatric intervention. Poverty, as represented by insurance type, predicted poorer treatment outcome. Among several other variables that contribute to socioeconomic status: younger age, history of psychological trauma, unplanned pregnancy, and lack of a significant other at home, only unplanned pregnancy significantly influenced treatment outcome. Cigarette smoking and alcohol use did not significantly affect outcome. Interestingly, the number of Axis I or presence of Axis II diagnoses neither affected the severity of patient depression, as indicated by the initial EPDS score, nor change in EPDS score during their treatment in the clinic.

CONCLUSION: There is a complex interplay between variables affecting the mood state of a pregnant or postpartum woman. Several of these variables are traits upon which a psychiatrist has no impact. Optimally, medication and psychotherapy may modify the woman's reaction to these variables.

ACKNOWLEDGEMENTS

The Steering Committee for the 31st Annual Kalamazoo Community Medical and Health Sciences Research Day would like to thank the following WMed professionals who dedicated their time to participate as abstract reviewers, judges, and/or session moderators for today's event.

Joanne Baker, DO
Faculty, Internal Medicine

Robert Baker, MD
Program Director, Sports Medicine

Susan Bannon, MD
Faculty, Internal Medicine

Joseph Calles, MD
Faculty, Psychiatry

Joseph D'Ambrosio, MD
Program Director, Transitional Year &
Medicine/Pediatrics

Colleen Dodich, MD
Faculty, Pediatrics

Martin Draznin, MD
Faculty, Pediatrics

Ross Driscoll, MD
Faculty, Internal Medicine

David Dunstone, MD
Faculty, Psychiatry

Arthur Feinberg, MD
Faculty, Pediatrics

Thomas Flynn, MD
Faculty, Infectious Disease

Donald Greydanus, MD
Program Director, Pediatrics

Jane Hanneken, MD
Faculty, Family Medicine

Mark Loehrke, MD
Faculty, Internal Medicine

Thomas Melgar, MD
Faculty, Pediatrics

Ahsan Nazeer, MD
Faculty, Psychiatry

Earl Norman, MD
Program Director, Surgery

David Overton, MD
Program Director, Emergency Medicine

Dilip Patel, MD
Faculty, Pediatrics

Vinay Reddy, MD
Faculty, Pediatrics

Richard Roach, MD
Faculty, Internal Medicine

Dale Rowe, MD
Program Director, Orthopaedics

Saad Shebrain, MD
Faculty, General Surgery

Robert Strung, MD
Program Director, Psychiatry

Ruqiya Tareen, MD
Faculty, Psychiatry

Perry Westerman, MD
Faculty, Psychiatry

Alan Wilke, MD
Program Director, Family Medicine

Peter Ziemkowski, MD
Faculty, Family Medicine

INDEX OF AUTHORS FOR ORAL PRESENTATIONS

Abdulmassih.....	8, 11	Dubbireddi.....	10, 11, 67, 68	Lantz.....	65	Samal,	7
Acharya.....	66	Dugan.....	9, 10, 67	Lash.....	8	Schauer.....	10, 66, 67
Adu-Gyamfi.....	66	Duhn.....	11	Lee-Ekblad.....	67	Scheidt.....	67
Agarwal.....	10, 65	Dunstone.....	9, 10	Liepman.....	9, 10, 68	Selde.....	67
Aggarwal.....	10, 11, 66, 67	Egloff.....	66	Liguori.....	65, 68	Shah.....	67, 68
Anderson.....	68	Eichel.....	67	Livezey.....	12	Sharma.....	7, 8, 11
Attaway.....	11, 66	Ekblad.....	67	Loehrke.....	66	Shaw.....	8, 12
Bagh.....	11	Elliott.....	7	Loehrke, M.....	128	Shebrain.....	9, 128
Baker.....	8, 12, 68	English.....	67	Longstreet.....	10	Sheppard.....	12
Baker, J.....	68	Ertl65.....		Lowe Furge.....	12	Sherwood.....	65
Baker, J.....	128	Essani.....	65	Lund.....	8, 9, 66	Sikkema.....	68
Baker, R.....	128	Fales.....	8, 65	Luz.....	12	Singh.....	65
Bakke.....	65	Feinberg, A.....	128	Maertins.....	68	Sivertson.....	68
Bannon.....	8, 10, 67	Florian.....	9	Malik.....	8, 12, 66, 68	Smith, A.....	67
Bannon, S.....	128	Flynn.....	7, 11, 67	Maltz.....	9	Smith, C.....	67
Bard.....	65	Fuller.....	67	Mastenbrook.....	67	Smith, N.....	8
Becktell.....	7	Galdys.....	68	McCormack.....	10, 66	Smullen.....	8
Beckwith.....	67	Gandy.....	67	McKean.....	9	Sordillo.....	67
Bejcek.....	65	Gittus.....	66	McKenna.....	65	Stark.....	8
Birchmeier.....	67	Greydanus, D.....	128	Mersfelder.....	68	Steensma.....	9
Bivins.....	67	Grinfield.....	66	Michalsen.....	65	Stevenson.....	10
Blostein.....	9	Gross.....	68	Miller.....	9, 65	Stork.....	8
Boapimp.....	11	Gukasov.....	7, 67	Moe.....	9	Strung.....	9
Bobeda.....	11	Gupta.....	65, 66	Monroe.....	67	Strung, R.....	128
Boitano.....	65	Gushurst.....	7, 68	Moore.....	7, 10, 11, 68	Struzziari.....	66
Bolles.....	12	Gustafson.....	7	Morgan.....	65	Suryawanshi.....	65
Boulden.....	11	Gygi.....	65	Motin.....	68	Swezy.....	9, 12
Bradstreet.....	11, 67	Haas.....	9	Movitz.....	8, 9	Sytsma.....	67
Bricker.....	11	Haghshenas.....	9	Musaev.....	65	Szeles.....	65
Briggs.....	12	Hammouda.....	7	Nagy.....	12	Tareen.....	9, 68, 128
Brown.....	11, 68	Hanson.....	68	Nanavati.....	11, 66, 67	Tensmeyer.....	7
Burgess.....	65	Haq.....	68	Nehra.....	66	Terry.....	11
Burke.....	9, 65	Harcourt.....	68	Norman, E.M.....	128	Toledo-Pereyra.....	8, 11, 12, 67
Burns.....	12	Hays.....	10, 11	Olken.....	66	Tuncay Scorza.....	11
Byrd-Jacobs.....	65	Heffelfinger.....	67	Olsen.....	65	Vaddineni.....	10
Callanan.....	11	Hirsch.....	68	Ortega.....	8	Vaishnav.....	11
Campbell.....	8	Hollmer.....	68	Overton.....	68	Van de Velde.....	67
Chandana.....	11, 66	Homa.....	10, 12	Overton, D.....	128	Van Enk, R.....	68
Chang.....	67	Homnick.....	7	Papani.....	10, 66, 67, 68	VandenBerg.....	9
Charoth.....	9, 68	Iglesias.....	65	Pareshbhai Shah.....	66	VanEnk, L.....	66
Chess.....	7	Janiski.....	65	Patel.....	7, 68, 128	Varshney.....	7, 66
Childs.....	7, 67	Jastifer.....	7, 8	Pazderka.....	8, 65, 68	Velani.....	11, 66, 67
Ching.....	10	Jeng.....	65	Polcher.....	67	Wajid.....	68
Connaughton.....	9, 65	Johnson, T.....	68	Pratt.....	9	Walsh.....	9
Cox.....	8	Kalavakunta.....	66	Preet.....	66	Warga.....	65
Cressman.....	10	Kane.....	65	Putman.....	8	Waterson.....	8
Currey.....	7	Kanike.....	68	Randhawa.....	10	Wen Goh.....	65
Curtis.....	9, 12	Kanzawa.....	10	Rango.....	7	Wiley.....	12
D'Ambrosio, J.....	128	Karampahtsis.....	9	Rathburn.....	65	Williams.....	65
Dams.....	65	Kavanaugh.....	67	Remmler.....	9	Williams.....	9
Danielsky.....	8	Klein.....	8	Reynolds.....	8, 67	Willoughby-Byrwa.....	65
Darling.....	65	Koestner.....	8	Richardson.....	68	Wilt.....	67
Davidson.....	8, 9	Kolderman.....	7	Richie.....	67	Wolf.....	68
DeBoer.....	8	Kolla.....	66	Roach.....	10, 67	Woodhouse.....	68
DeGrand.....	65	Kotal.....	68	Roach, R.....	128	Yang.....	68
Deibel.....	8	Kothari.....	8, 9, 12, 68	Roberts.....	7, 66	Yoder.....	67
Demark.....	67	Kraatz.....	9	Rogers.....	66	Zachos.....	8, 12, 67
Dodich.....	68	Kutzko.....	8	Rohs.....	8	Zaffiri.....	8, 9, 10, 68
Doherty.....	7	Lagerwey.....	8	Rowe, D.....	128	Zellner.....	67
Dormitorio.....	68	Lammers.....	65, 68	Ruggeiro.....	68	Zhou.....	12
Draznin, M.....	128	Landon.....	10, 12	Ryan.....	66	Zielinski.....	8
Driscoll.....	11, 66	Lane-Davies.....	68	Sabesan.....	7, 8, 11, 67		
Driscoll, R.....	128	Lang.....	7, 66	Saeed.....	11, 68		